

Available online at [www.sciencedirect.com](http://www.sciencedirect.com)

ScienceDirect

journal homepage: [www.elsevier.com/locate/burns](http://www.elsevier.com/locate/burns)

# A literature review of the military uses of silver-nylon dressings with emphasis on wartime operations<sup>☆,☆☆</sup>

David J. Barillo<sup>a,\*</sup>, Morano Pozza<sup>b</sup>, Mary Margaret-Brandt<sup>c</sup>

<sup>a</sup> Disaster Response, Critical Care Consultants, LLC, Mount Pleasant, SC, USA

<sup>b</sup> Italian Army Medical Service & Università degli Studi di Modena e Reggio Emilia, Emilia-Romagna, Italy

<sup>c</sup> Department of Surgery, St. Joseph Mercy Hospital-Ann Arbor, Ann Arbor, MI, USA

## ARTICLE INFO

### Keywords:

Military medicine  
Deployed medicine  
Silver  
Burns  
Trauma  
Mass casualty  
War

## ABSTRACT

Medical support of military operations involves treatment of massive soft tissue wounds, thermal burns, open fractures, blast injuries and traumatic amputations under conditions that are often austere and far from supply lines. Military hospitals, as recently deployed in Iraq and Afghanistan, are designed and equipped for stabilization and rapid transfer of injured patients back to their home nation. These austere facilities are often tasked with the emergency or long-term treatment of local populations when injured or burned, further stressing the medical resupply system.

Pathogens encountered in contemporary wartime practice are increasingly resistant to antibiotics. Ionic silver is bactericidal against a broad spectrum of bacteria, yeasts and fungi, has been utilized as a topical antiseptic for over 100 years, and has no known clinically-relevant resistance. Silver-nylon dressings, initially stocked in US military hospitals as a burn dressing, are now finding utility as a universal dressing for all types of combat wounds. Compared to conventional burn dressings, they are easier to transport and store, easier to use, and do not need to be changed as frequently, allowing for conservation of nursing resources.

In this literature review, the recent military uses of silver-nylon dressings are examined. The stockpiling and use of silver-nylon as a universal military burn and wound dressing is advocated.

© 2014 Elsevier Ltd and ISBI. All rights reserved.

## 1. Introduction

The nature of military operations is continually changing. For this reason, medical support for such operations must

constantly evolve. In recent years, emphasis has changed from the support of large-scale land wars to smaller regional conflicts that start rapidly and unpredictably and that occur far from established logistics hubs or supply routes. Recent operations in Iraq and Afghanistan are prime examples.

<sup>☆</sup> Presented as a Poster Session at the 2011 Meeting of the European Wound Management Association, Brussels, Belgium, May 25, 2011.

<sup>☆☆</sup> The opinions or assertions herein contained are the private views of the authors and are not to be construed as official or as reflecting the views of the Department of the Army or Department of Defense. Brand names of commercial devices are for illustrative purposes and do not imply endorsement by the Department of the Army or Department of Defense. Institutional Review Board/Ethics review was not required.

\* Corresponding author at: Disaster Response/Critical Care Consultants, LLC, PO Box 683, Mount Pleasant, SC 29465, USA.

E-mail address: [dbarillo@gmail.com](mailto:dbarillo@gmail.com) (D.J. Barillo).

<http://dx.doi.org/10.1016/j.burns.2014.09.017>

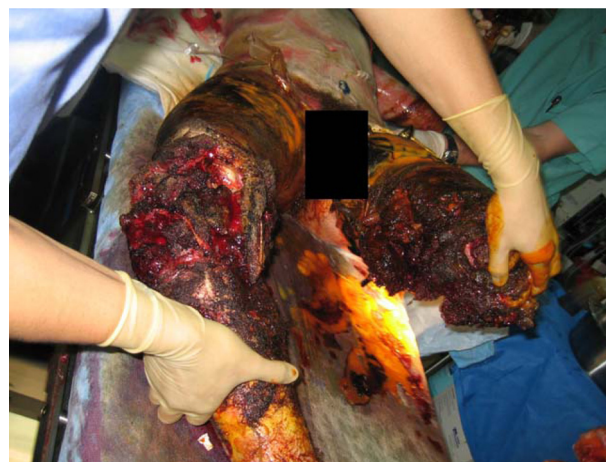0305-4179/© 2014 Elsevier Ltd and ISBI. All rights reserved.

In response, military medical facilities are now smaller and more mobile, but less extensively equipped than their Cold-War predecessors. This requires a corresponding change in medical doctrine: the very-rapid evacuation of casualties out of the combat zone to large fixed facilities in Europe or the United States for definitive care.

Deployed military hospitals often find themselves in the position of providing care to the local (civilian) population because the local medical system is either significantly disrupted or overwhelmed [1]. Cancio notes that 'during war, civilian health care, to include burn care for patients of all ages, may temporarily become the responsibility of the occupying forces' [2]. It is very difficult to provide proper burn care in a deployed environment, particularly if the medical facility is housed in tents. A lack of nursing personnel with formal training in burn care and the inability to provide conscious sedation on the ward means that most major burn dressing changes will have to be performed in the operating room. Because of the demands of personnel and materiel, US military doctrine recommends against providing definitive burn care within the theater of operations [2-4]. Extended burn care in a deployed facility becomes unavoidable, however, when care is provided to local civilians who cannot be evacuated or when either weather (e.g. sandstorms) or distance (e.g. injury occurring in the remote mountains of Afghanistan) precludes immediate evacuation of military personnel. In this situation, an anti-microbial dressing that could be applied by inexperienced personnel and left in place for several days would be ideal.

Both the pathogens and the injuries encountered in war are evolving. Ressler et al. examined the pathogens responsible for bacteremia in burn patients involved in combat operations overseas and found that the traditional pathogens, *Staphylococcus aureus* and *Pseudomonas aeruginosa*, are increasingly being supplanted by multi-resistant *Acinetobacter* and *Klebsiella* species [5]. When choosing topical antimicrobial therapy for burn or other open war wounds, these resistance patterns must be considered.

In current conflicts, the extensive use of body armor covering the head and trunk, and the introduction of Improvised Explosive Devices (IED) as a weapon have changed the patterns of injuries encountered. Open fractures and traumatic amputation injuries are commonly found in close proximity to thermal burns (Photograph 1). Abdominal Compartment Syndrome (ACS) is increasingly being diagnosed and managed by decompressive laparotomy in the deployed setting [6]. This has created a need for a dressing method that can be used to cover the open abdomen in flight. Operations Enduring Freedom and Iraqi Freedom are the first conflicts where Negative-Pressure Wound Therapy (NPWT) has been available in deployed medical facilities, and this method has been extensively used to treat open wounds, extremity amputations, fasciotomy sites and as a dressing for the open abdomen after decompressive laparotomy. Negative-pressure wound therapy by itself is reported to lower wound microbial counts, but a method of applying a potent and sustained-release antimicrobial dressing under NPWT would be useful for war wounds. Patients with such injuries are frequently flown long distances and handed off between multiple medical teams, precluding serial examination and frequent dressing changes.



**Photograph 1 – Massive blast/amputation/open fracture/thermal burn typical of combat casualties.**

Ionic silver is bactericidal against over many species of bacteria, yeasts and fungi, including Methicillin-resistant *Staphylococcus aureus* (MRSA) and multi-drug resistant (MDR) *Acinetobacter*, *Klebsiella* and *Pseudomonas*. In 1881, it was discovered that application of silver nitrate solution to the eyes of newborns would prevent ophthalmia neonatorum, and this practice, still in use in some locations, became mandatory by state law in most US jurisdictions by the early 1900s [7,8]. Moyer et al. [9,10] pioneered the use of 0.5% silver nitrate solution as a topical therapy for burn patients in 1965. His work was influenced by the experiences of one of his co-authors, who had been using topical silver nitrate solutions as an adjunct for the management of necrotizing fasciitis since 1941 [10]. Fox introduced silver-sulfadiazine for burn management in 1968 [11,12]. Both 0.5% silver nitrate solution and 1% silver sulfadiazine cream continue to be used in contemporary burn care [9].

Several groups investigated the use of silver-nylon cloth as a topical dressing in the 1980s and 1990s including the US Army Institute of Surgical Research (Army Burn Center) at Brooke Army Medical Center in San Antonio, Texas [13-25]. Independent of these efforts, a commercial silver-nylon dressing was brought to the market in the following decade (Silverlon<sup>®</sup>, Argentum Medical, LLC). Silverlon<sup>®</sup> was first evaluated at the Army Burn Center in 2003, and became available as a burn dressing in US military medical facilities in Iraq and Afghanistan in the same year. Initial success with burn patients led to more widespread use in-theater for other indications. Silverlon<sup>®</sup> dressings soon found utility as a trauma dressing for diverse applications including open wounds, amputation sites, fasciotomy incisions and in combination with NPWT placed over decompressive laparotomy incisions. By 2006, these dressings had also become a standard of care for transcontinental aero-medical evacuation of patients with large burns [26].

In this literature review, the evolution and contemporary use of silver-nylon dressings in military medical practice is summarized.

## 2. Methods

A computer literature review for the years 1987–2011 was conducted, searching for English-language articles describing the military use of silver-nylon dressings in either laboratory or clinical settings, with emphasis on experience at deployed or far-forward medical facilities or in transcontinental aero-medical evacuation. A similar search was conducted using the annual report and publication archives of the US Army Institute of Surgical Research. The experiences of the authors in using silver-nylon dressings while deployed as burn and trauma surgeons in Afghanistan (MMB, MP), Iraq (DB, MMB) and in-flight (DB) were also reviewed. A total of 21 articles were found and evaluated [1,2,15–33].

A number of commercially available silver-containing products presently are used for burn care. The use of silver nitrate solution and silver-sulfadiazene has already been described in detail and these compounds were not included in the literature search. We also chose to limit this study to silver-nylon based products because of our prior research and clinical experience with this modality [2,15,16,26,29]. A final limitation of the study is that no articles referencing the military or deployed use of silver products by other countries were found. A number of countries have deployed medical facilities into Afghanistan or Iraq either independently or under the auspices of the North Atlantic Treaty Organization (NATO). The choice and methodology of wound care provided at US deployed facilities is guided by Joint Theater Trauma System (JTTS) and US Central Command (CENTCOM) Clinical Practice Guidelines (CPGs). Choice of wound care product used at other NATO facilities is governed by their internal policies and procedures and is beyond the purview of US guidelines.

## 3. Results

English-language literature review for the years 1987–2011 produced 21 publications describing the laboratory or clinical use of silver-nylon dressings in military burn or combat applications [1,2,15–33]. These included bench studies, retrospective and prospective clinical studies and general care recommendations, and are summarized in Table 1.

Chu et al., at the US Army Institute of Surgical Research, extensively studied the effects of weak direct electrical current on burn and wound healing in different rodent models [16–25,31,32]. The electrodes used to apply electrical current were constructed of a silver-nylon cloth originally developed for use as a radar reflector or electrostatic shield [20]. As a serendipitous finding, it was discovered that silver-nylon dressings in combination with weak direct current, possessed some antimicrobial properties, which was attributed to the release of ionic silver. On the basis of these studies, limited human use of silver-nylon cloth, with and without direct current was undertaken. The patient shown in Photograph 2 had silver-nylon cloth with direct current (“electric bandaid”) placed under a Compassionate Use protocol because the burn wounds were growing *Pseudomonas aeruginosa* resistant to all available antibiotics. Shirani et al., completed a prospective human study of silver-nylon dressings and direct current on

**Table 1 – Incidence of burn in combat casualties.**

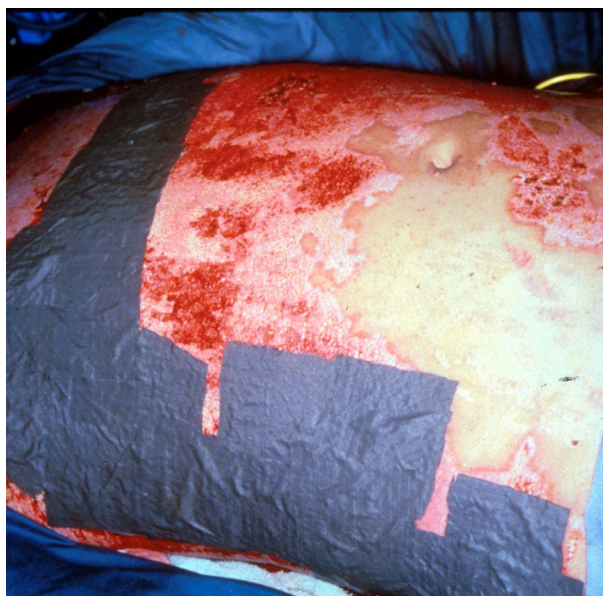
Conflict	Year	% of casualties	References
Vietnam	1965–1975	10	[3,35]
6 Day war	1967	4.6	[37]
Yom Kippur war	1973	10.5	[2,43]
Falkland Islands	1982	18	[35,37,38]
Lebanon	1982	8.6	[2,44]
Desert storm	1991	7.9	[2,45]
Early OIF/OEF	2003–2005	~5	[5,27]

Note: OIF = operation Iraqi freedom; OEF = operation enduring freedom.

skin graft donor sites [15]. Compared to standard therapy (fine-mesh gauze), silver-nylon dressings and direct current resulted in faster wound healing and significantly less pain [15].

At this point, emphasis changed to the use of commercially available silver dressings that did not require the addition of direct current. Albrecht, et al., completed a similar donor site a decade later using a commercial silver-nylon product (Silverlon<sup>®</sup>) and found similar results. Compared to Xeroform<sup>®</sup> dressings, donor sites treated with Silverlon<sup>®</sup> healed faster and were less painful [28].

Brandt et al. documented the first combat use of silver-nylon dressings in 2003 [2,29]. In Afghanistan, the 452nd Combat Support Hospital (CSH) was deployed in 2003 to Bagram Airbase, 47 km north of Kabul. The hospital operated 44 inpatient beds in tents. Burned troops from the US or NATO countries were usually stabilized and evacuated out of country, however, local nationals with burn often required treatment at the CSH for prolonged periods of time. Over several months, the CSH treated 10 burn patients including 8 children and an additional 8 patients with complex wounds from mine injuries including 4 children. Silver-nylon dressings were extensively utilized. Dressings were left in place for



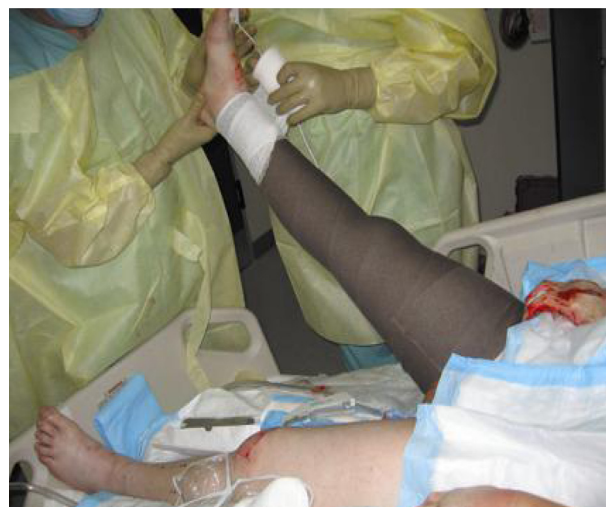**Photograph 2 – Early human use of silver-nylon cloth with direct current: placement on a patient with a large full thickness burn.**

3–7 days and reused for a total of 7 days [2,29]. Use of an every 3–7 day dressing change instead of a twice-daily silver sulfadiazine dressing change ‘appeared to decrease the total workload associated with burn wound care’ [2]. There were no episodes of cellulitis or burn wound infection associated with the use of silver-nylon in this setting [2,29].

Cancio et al. [2] described the use of silver-nylon dressings at the 28th Combat Support Hospital (CSH) in Iraq. Deployed to Baghdad in the initial phases of Operation Iraqi Freedom, the 28th CSH operated from April 11, 2003 to August 26, 2003 in tents on an austere logistics base. During this period, the CSH was designated as the primary in-theater burn facility. Of the 1867 patients admitted to the hospital, there were 86 burn patients, comprising 5% of all admissions [2]. These included 42 US military or coalition patients and 44 Iraqi Nationals. The average length of stay was 2 days for military patients compared to 10 days (range 1–53 days) for Iraqi civilians [2]. Of 877 operations performed at the CSH, 59 were performed for burn, including 49 debridements, 5 split thickness skin grafts and 4 escharotomies. In addition, a large number of bedside procedures were performed under conscious sedation.

As Operation Iraqi Freedom progressed, the Baghdad CSH moved into Ibn Sina Hospital, a fixed facility located within the International Zone. This hospital remained the only designated military burn center in Iraq for 7 years. Over several rotations between the years 2003 and 2009, Ibn Sina was continuously staffed by US Military personnel from the 28th, 10th, 31st and 86th Combat Support Hospitals, and by surgeons from the US Army Burn Center. Silver-nylon dressings were extensively used during this timeframe for burn, blast, open fracture and other massive soft tissue injuries. Danks and Laird [33] described the management of a typical patient at Ibn Sina hospital.

Barillo et al. [26] described the use of silver-nylon dressings in flight for transcontinental aero-medical evacuation. The US Army Burn Center staffs a Burn Flight Team to facilitate long-range aero-medical transfer of patients to the center for care, and this team frequently transports patients from Landstuhl Regional Medical Center, Germany to San Antonio, Texas, a distance of 5400 miles. During wartime operations, it was not unusual for the Burn Flight Team to simultaneously transport 5 or more severely burned patients (with total burn surface area (TBSA) ranging from 50 to 90% total body surface area) on a single flight. On arrival to Landstuhl Regional Medical Center, the burn team would perform a full burn dressing change using silver sulfadiazine and mafenide acetate creams. This usually required two or more nurses and two or more hours per patient to perform. A second dressing change would be performed in the evening, and a third dressing change would be required prior to flight the following day. With 5 patients requiring nearly 10 h of combined dressing time, it was difficult for the team to both complete the pre-flight dressing change and to be able to depart the Intensive Care Unit at midmorning for the flight home. Since the flight would take approximately 13 h, the patients would require another dressing change immediately upon arrival in San Antonio. To solve this problem, the Burn Flight Team began carrying silver-nylon burn dressings to Landstuhl. This allowed a single dressing change at the time of Burn Team arrival and obviated the need for a second dressing change at night and a third



**Photograph 3 – Silver-nylon dressings being applied by the Burn Flight Team at Landstuhl Regional Medical Center (Germany) prior to 13-h flight to USA.**

dressing change pre-flight the following day (Photograph 3). With the silver-nylon dressing technique, if the aircraft was delayed or diverted, there was no need for an additional burn dressing change in flight. The silver-nylon technique soon became the standard treatment for aero-medical evacuation. Silver-nylon burn dressings are presently positioned at every US military hospital along the evacuation route, including Landstuhl Regional Medical Center and Bagram Air Base. The technique has been adopted by US Air Force Critical Care Air Transport (CCAT) Teams and is taught at the US Air Force School of Aerospace Medicine CCAT Basic Course.

#### 4. Discussion

The nature of wartime medical support is constantly changing. For most of the major conflicts of the 20th century, large station or field hospitals could be positioned in or close to the combat zone. These were full-service general hospitals with 1000 or more beds where injured soldiers could be treated for extended periods of time. Medical planning during the Cold War relied on the availability of such facilities pre-positioned in Europe, along with robust supply chains to keep them functioning.

Following the fall of the Soviet Union and the corresponding downsizing of military forces on both sides, it became impossible to deploy such large fixed hospitals. At the same time, the military threat switched from the possibility of a protracted land war in Europe to smaller regional conflicts. Lieutenant General Paul K Carlton, a former US Air Force Surgeon General, notes that “beginning with *Operation Just Cause* in Panama (1989), it became apparent that our troops would, at times, suffer injury in a location where only minimal stabilizing medical care is available” [34]. General Carlton further comments that during Operations Desert Shield and Desert Storm, “the amount of sealift required to move ‘mobile hospitals’, together with the time required to set them up,

mandated that the medical services of all military branches find a new way to deliver medical care to combat troops" [34]. Following a joint-service streamlining of military medical forces in the 1990s, the medical facilities in present use are lighter, smaller, modular, and easier to move but are not as well stocked as the fixed facilities that they replaced [34]. This means that frequent re-supply must be carried out, involving either airlift or convoy operations thru hostile territory.

In planning medical support for combat operations, a basic tenet is that burns will comprise 10% of all combat injuries. This is based on data from the Vietnam War collected by the Wound Data and Munitions Effectiveness Team showing that thermal injury or other major soft tissue injury requiring operative debridement will be present in 10% of combat casualties [3,35]. In fact, as seen in Table 1, the incidence of combat burn will vary from 5 to 20% depending upon the nature of the conflict [2]. In particular, conflict involving either armored vehicles or naval operations will produce a larger number of burn casualties [2,36]. For example, burns occurred in 18% of British casualties from the Falklands War [35,37,38], a conflict that involved the use of anti-ship missiles. In these situations, silver-nylon dressings have a clear advantage as fewer dressing supplies are required. Patients with burns can be treated with one dressing change every 3–7 days rather than requiring two dressing changes a day with either mafenide acetate or silver sulfadiazine. Silver-nylon dressings are also lighter to transport, easier to store and less affected by environmental extremes during storage compared to conventional cream-based dressings.

Each war presents new challenges in terms of emerging pathogens, and the current conflicts are no exception. In particular, colonization or infection with multi-drug resistant (MDR) *Acinetobacter* species (ACB) has been seen in casualties returning from Iraq or Afghanistan. While it was originally thought that this might simply represent local flora from the location of injury, more recent data suggests that colonization may be occurring after entry to Level III (deployed) medical facilities as a nosocomial event [27,39]. Albrecht et al. reviewed the experiences of the US Army Burn Center with this pathogen between January, 2003 and November, 2005 [40]. The study population of 802 patients included both patients admitted locally and servicemembers transferred from Afghanistan and Iraq. There were 59 patients diagnosed with ACB infection and 52 additional patients found to be colonized with ACB. Sixty-one percent of ACB isolates were sensitive to imipenem-cilastin, 36% were sensitive to amikacin, and 24% were sensitive to ampicillin-sulbactam; all other antibiotics had sensitivities between 2 and 22%. A number of second-line antibiotics, including inhaled and intravenous colistin were re-introduced into burn practice as a result. Patients with ACB infection had larger-sized burns, more co-morbidities and a higher mortality rate compared to the non-infected cohort. Nevertheless, multivariate analysis demonstrated no statistical association between ACB infection and mortality.

When emerging pathogens demonstrate resistance to multiple intravenous antibiotics, the topical agent used for control of burn wound flora becomes more important. An ideal topical agent will have a broad spectrum and little potential for resistance. Ionic silver is no exception. In theory, dressings that deliver low (or even sub-lethal) levels of silver ion could result in bacterial resistance to silver [41].

True microbial resistance to silver is exceptionally uncommon, although the exact incidence remains undefined. The few articles that can be found consist of *in vitro* studies, letters to the editor or collective reviews and are essentially devoid of human data. Loh et al., [42] examined the prevalence of three genes coding for silver resistance (*silE*, *silP* and *silS*) in 33 strains of methicillin-resistant MRSA and 8 strains of methicillin-resistant coagulase negative Staphylococci (MR-CNS) obtained from animal and human wounds and nasal cavities. Two of the resistance genes (*silP* and *silS*) were absent in all specimens tested. Two MRSA and one MR-CNS strain were positive for the *silE* gene. Further testing of these strains showed that a silver-containing dressing was effective in killing all strains with or without the resistance gene: in other words, the presence of a silver-resistance gene did not afford protection to the organism against silver dressings [42]. Chopra [41] in a 2007 literature review noted that there have been fewer than 20 documented cases of bacterial resistance to silver since 1975. The review concluded that clinicians should preferentially choose dressings that release high levels of ionic silver and demonstrate rapid bactericidal activity to minimize the risk of silver resistance.

While initially fielded for burn care, silver-nylon dressings have also proven useful for the management of massive soft tissue injuries, open fractures, blast injuries and traumatic amputations. Silver-nylon products intended for use under NPWT are commercially available, and these products are ideal to cover debrided traumatic wounds or open amputation stumps, fasciotomy sites, and laparotomy incisions intentionally left open for Abdominal Compartment Syndrome. Silver-nylon dressings are easier to transport and store than conventional burn creams, are useful on a wider variety of wounds, and are easier to use by inexperienced personnel. On this basis, we would recommend the military stockpiling and use of silver-nylon as a universal wound dressing for use in applications where the number of trained medical personnel may be limited, supply lines may be tenuous and storage conditions may be unpredictable.

---

## Conflict of interest

Dr Barillo is a paid consultant to Argentum Medical, LLC and member of the Argentum Medical Advisory Board. Dr Pozzo and Dr Brandt have no potential conflicts of interest to declare.

## REFERENCES

- [1] Barillo DJ, Brisim M. Pediatric burns in war environments. In: Phillips BJ, editor. *Pediatric burns*. London: Cambria Press; 2012. p. 477–83.
- [2] Cancio LC, Horvath EE, Barillo DJ, Kopchinski BJ, Charter KR, Montalvo AE, et al. Burn support for Operation Iraqi Freedom and related operations, 2003–2004. *J Burn Care Rehabil* 2005;26:151–61.
- [3] Bowen TE, Bellamy RF, editors. *Emergency war surgery: second United States revision of the emergency war surgery NATO handbook*. Washington, DC: US Government Printing Office; 1988.

- [4] Anonymous. Emergency war surgery, third United States edition. Washington, DC: Borden Institute, Walter Reed Army Medical Center; 2004.
- [5] Ressler RA, Murray CK, Griffith ME, Rasnake MS, Hospenthal DR, Wolf SE. Outcomes of bacteremia in burn patients involved in combat overseas. *J Am Coll Surg* 2008;206:439-44.
- [6] Markell KW, Renz EM, White CE, Albrecht ME, Blackburne LH, Park MS, et al. Abdominal complications following severe burns. *J Am Coll Surg* 2009;208(5):940-9.
- [7] Standler RB. Statutory law in the USA: requiring silver nitrate in the eyes of newborns; 2006, Available online at [www.rbs2.com/SilvNitr.pdf](http://www.rbs2.com/SilvNitr.pdf) [accessed 15.05.10].
- [8] Dillon HC. Prevention of gonococcal ophthalmia neonatorum. *New Engl J Med* 1986;315:1414-5.
- [9] Barillo DJ. Topical antimicrobials in burn wound care: a recent history. *Wounds* 2008;20(7):192-8.
- [10] Moyer CA, Brentario L, Gravens DL, Margraf HW, Monafio Jr WW. Treatment of large human burns with 0.5% silver nitrate solution. *Arch Surg* 1965;90:812-67.
- [11] Fox Jr CL. Silver sulfadiazine-a new topical therapy for *Pseudomonas* in burns. *Therapy of Pseudomonas infections in burns. Arch Surg* 1968;96(2):184-8.
- [12] Stanford W, Rappole BW, Fox Jr CL. Clinical experience with silver sulfadiazine, a new topical agent for control of *Pseudomonas* infection in burn patients. *J Trauma* 1969;9(5):377-88.
- [13] MacKeen PC, Person S, Warner SC, Snipes W, Stevens SE. Silver-coated nylon fiber as an antibacterial agent. *Antimicrob Agents Chemother* 1987;31:93-9.
- [14] Deitch EA, Marino AA, Gillespie TE, Albright JHA. Silver-nylon: a new antimicrobial agent. *Antimicrob Agents Chemother* 1983;23:356-9.
- [15] Shirani KZ, McManus AT, Robertson F, Walton G, Barillo DJ, McManus WF, et al. Silver-nylon dressings promote painless healing. *Proc Am Burn Assoc* 1993;25:66.
- [16] Barillo DJ, McManus AT, Chu CS, Pruitt BA. Effect of silver-nylon dressings and weak direct current on skin microcirculation. *Shock* 1995;3(42 Suppl.). page 41 (abstract).
- [17] Chu CS, McManus AT, Pruitt Jr BA, Mason Jr AD. Therapeutic effects of silver nylon dressings with weak current on *Pseudomonas aeruginosa*-infected burn wounds. *J Trauma* 1988;28:1488-92.
- [18] Chu CS, McManus AT, Okerberg CV, Mason Jr AD, Pruitt Jr BA. Weak direct current accelerates split-thickness graft healing on tangentially excised second degree burns. *J Burn Care Rehabil* 1991;12:285-93.
- [19] Chu CS, Matylevich NP, McManus AT, Mason Jr AD, Pruitt Jr BA. Direct current reduces wound edema after full thickness burn injury in rats. *J Trauma* 1996;40(5):738-42.
- [20] Chu CS, Matylevich NP, McManus AT, Pruitt Jr BA, Goodwin CW. Direct current reduces accumulation of Evans Blue albumin in full thickness burns. *J Trauma* 1999;47(2):294-9.
- [21] Matylevich NP, Chu CS, McManus AT, Mason Jr Ad, Pruitt Jr BA. Direct current reduces plasma protein extravasation after partial thickness burn injury in rats. *J Trauma* 1996;41(3):424-9.
- [22] Chu CS, Matylevich NP, McManus AT, Pruitt Jr BA, Goodwin CW. Optimized mesh expansion of composite skin grafts in rats treated with direct current. *J Trauma* 1997;43(5):804-12.
- [23] Chu CS, McManus AT, Mason Jr AD, Okerberg CV, Pruitt Jr BA. Multiple graft harvestings from deep partial thickness scald wounds healed under the influence of weak direct current. *J Trauma* 1990;30(8):1044-50.
- [24] Chu CS, McManus AT, Matylevich NP, Mason Jr AD, Pruitt Jr BA. Enhanced survival of autoepidermal-allodermal composite grafts in allosensitized animals by use of silver-nylon dressings and direct current. *J Trauma* 1995;39(2):273-8.
- [25] Chu CS, Matylevich NP, McManus AT, Goodwin CW, Pruitt Jr BA. Accelerated healing with a mesh autograft/allodermal composite skin graft treated with silver nylon dressings with and without direct current in rats. *J Trauma* 2000;49(1):115-25.
- [26] Barillo DJ, Cancio LC, Stack RS, Carr SR, Broger KP, Crews DM, et al. Deployment and operation of a transportable burn intensive care unit in response to a burn multiple casualty incident. *Am J Disaster Med* 2010;5(1):5-13.
- [27] D'Avignon LC, Saffle JR, Chung KK, Cancio LC. Prevention and management of infections associated with burns in the combat casualty. *J Trauma* 2008;64:S277-86.
- [28] Albrecht MC, Renz E, Cancio LC, White CE, Blackburne LH, Chung K, et al. Comparison of Silverlon<sup>®</sup> dressing to Xeroform gauze in the treatment of skin graft donor site wounds. *J Burn Care Res* 2008;29(2 Suppl.):S134.
- [29] Brandt MM, Tait MJ, Taddonio TT, Wahl WL. Silverlon use in Afghanistan, 2003. *J Burn Care Rehab* 2004;25(2 Suppl.):S170.
- [30] White CE, Renz EM. Advances in surgical care: management of severe burn injury. *Crit Care Med* 2008;36(7 Suppl.):S318-24.
- [31] Chu CS, McManus AT, Matylevich NP, Goodwin CW, Pruitt Jr BA. Integra as a dermal replacement in a meshed composite skin graft in a rat model: a one-step operative procedure. *J Trauma* 2002;52:122-9.
- [32] Chu CS, McManus AT, Mason AD, Pruitt Jr BA. topical silver treatment after escharectomy of infected full thickness burn wounds in rats. *J Trauma* 2005;58:1040-6.
- [33] Danks RR, Lairet K. Innovations in caring for a large burn in the Iraq war zone. *J Burn Care Res* 2010;31:665-9.
- [34] Carlton PK. Forward. In: Hurd WW, Jernigan JG, editors. *Aeromedical evacuation, management of acute and stabilized patients*. New York: Springer-Verlag; 2003.
- [35] Barillo DJ, Craigie JE. Burn injury. In: Hurd WW, Jernigan JG, editors. *Aeromedical evacuation: management of the acute and stabilized patient*. New York: Springer-Verlag; 2002.
- [36] Chapman CW. Burns and plastic surgery in the South Atlantic campaign 1982. *J R Nav Med Serv* 1983;69:71-19.
- [37] Eldad I, Torem M. Burns in the Lebanon War "the blow and the cure". *Mil Med* 1982;155:130-2.
- [38] Cioffi WG, Rue LW, Buescher TM, Pruitt Jr BA. A brief history and the pathophysiology of burns. In: Zajchuk R, editor. *Textbook of military medicine. Part 1, vol. 5*. Washington, DC: US Government Printing Office; 1990.
- [39] Murray CK, Roop SA, Hospenthal DR, Dooley DP, Wenner K, Hammock J, et al. Bacteriology of war wounds at the time of injury. *Mil Med* 2006;171:826-9.
- [40] Albrecht MA, Griffith ME, Murray CK, Chung KK, Horvath EE, Ward JA, et al. Impact of *Acinetobacter* infection on the mortality of burn patients. *J Am Coll Surg* 2006;203:546-50.
- [41] Chopra I. The increasing use of silver-based products as antimicrobial agents: a useful development or a cause for concern? *J Antimicrobial Chemother* 2007;59:587-90.
- [42] Loh JV, Percival SL, Woods EJ, Williams NJ, Cochrane CA. Silver resistance in MRSA isolated from wound and nasal sources in humans and animals. *Int Wound J* 2009;6:32-8.
- [43] Owen-Smith MS. Armoured fighting vehicle casualties. *J R Army Med Corps* 1977;123:65-76.
- [44] Shafir R, Nili E, Kedam R. Burn injury and prevention in the Lebanon War 1982. *Isr J Med Sci* 1984;20:311-3.
- [45] Shirani KZ, Becker WK, Rue LW, Mason AD, Pruitt Jr BA. Burn care during operation desert storm. *J US Army Med Dep* 1992;PB8-92-1/2:37-9.