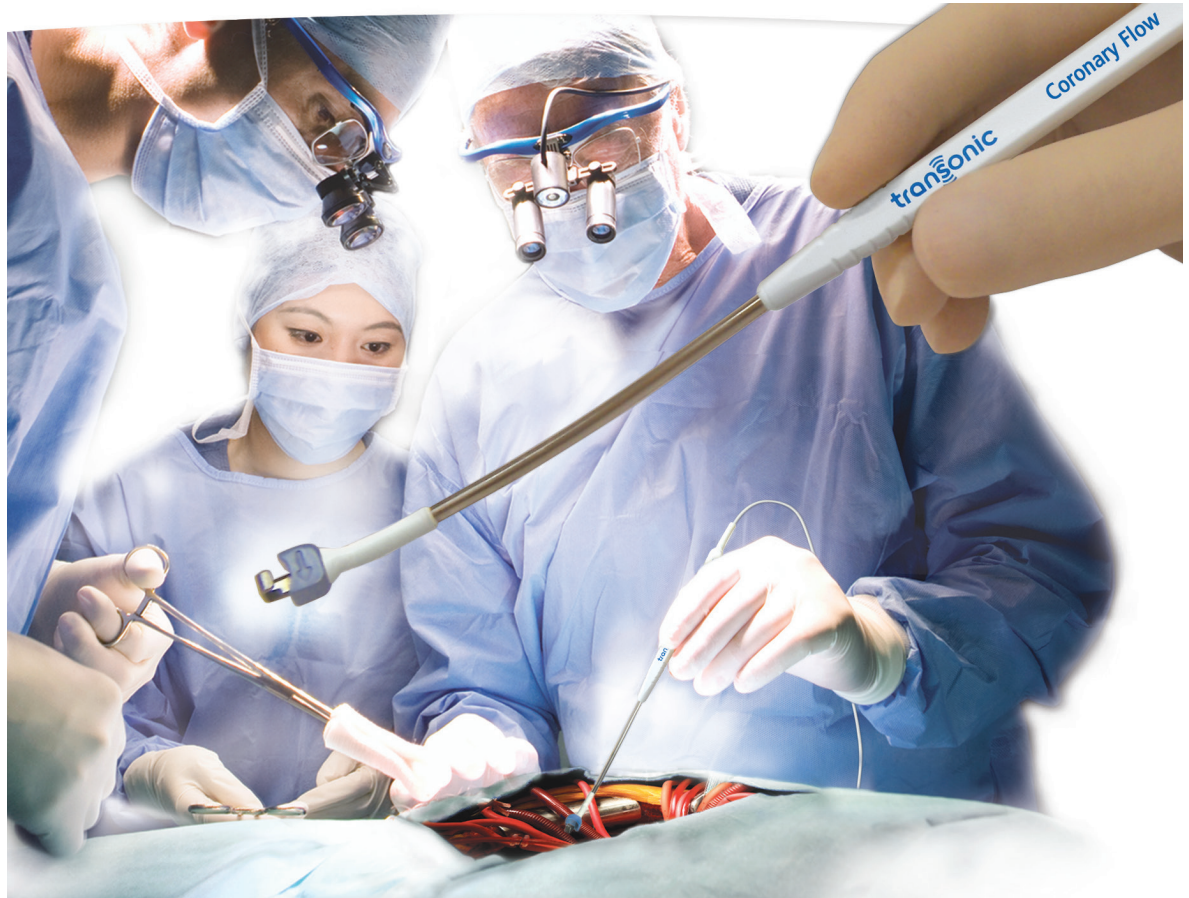

Flow-based Patency Assurance: Illustrative CABG Case Reports

"The intraoperative use of flow measurements provides invaluable information in a timely, accurate, cost-effective manner allowing for the surgical correction of a surgical problem. This has significantly reduced the complications related to early technically induced graft failure ... and provides documentation of the *sine qua non* of the operation: patency."

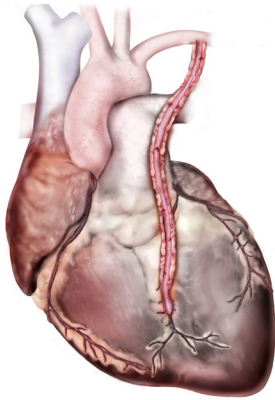
Mindich BP et al, "Reduction of Technical Graft Problems Utilizing Ultrasonic Flow Measurements,"
NY Thoracic Society, 2001.



transonic
THE MEASURE OF  BETTER RESULTS.

Intraoperative Flow Measurements

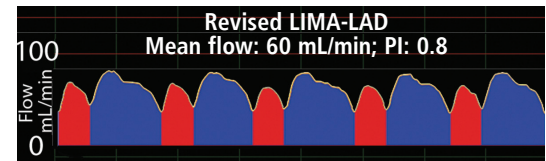
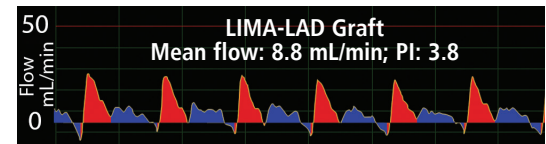
Two LIMA-LAD Cases Demonstrate that PIs <5 Can Be Misleading; Acceptable Mean Flow Is Key



These two cases demonstrate that a PI < 5 doesn't always mean that the graft has good flow. Acceptable mean flow is critical for graft patency assurance and decision making.

A 76-year-old male patient underwent coronary artery bypass grafting (CABG) surgery to bypass a lesion in the left anterior descending (LAD) artery utilizing a left internal mammary artery (LIMA) graft. Initial LIMA-LAD mean flow measured 8.8 mL/min (PI: 3.8) (top waveform).

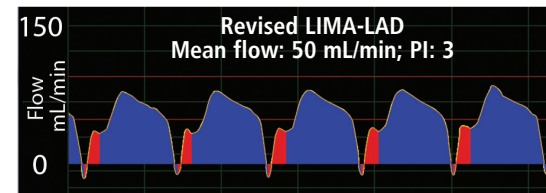
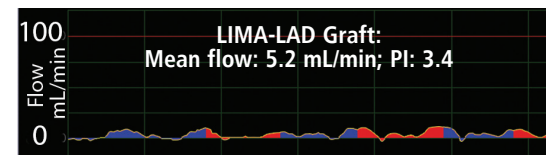
The graft was revised. Following revision, LIMA-LAD mean flow improved to 60 mL/min (PI: 0.8) and was accompanied by a classic, diastolic dominant waveform profile (bottom waveform).



The top LIMA-LAD graft waveform with a spiky systolic profile shows an initial graft flow of 8.8 mL/min (PI: 3.8). Following revision of the graft, flow increased to 60 mL/min (PI: 0.8) and was accompanied by a diastolic dominant waveform profile (bottom waveform).

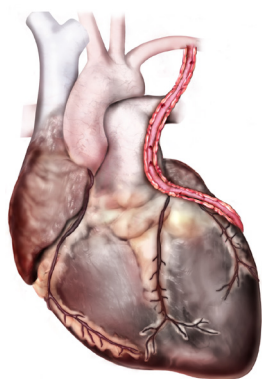
In the second case, a 67-year-old male patient with single-vessel coronary artery disease underwent off-pump CABG. LIMA-LAD graft flow first measured 5.2 mL/min (PI: 3.4). The patient's pulse and pressure appeared normal and the graft appeared functional, but the waveform exhibited a damped profile and atypical diastolization (top waveform). The surgeon decided to revise the graft.

After revision, LIMA-LAD graft flow improved to 50 mL/min (PI: 3). The flow waveform (bottom) exhibited a classic LIMA-LAD profile. Note that the first PI was 3.4, the revised PI was 3.



The top waveform demonstrated a damped profile and an atypical diastolization, and was accompanied by the 5.2 mL/min flow. This supported the surgeon's decision to revise the LIMA-LAD graft. Flow improved dramatically after revision and the waveform exhibited a classic LIMA-LAD profile (bottom waveform).

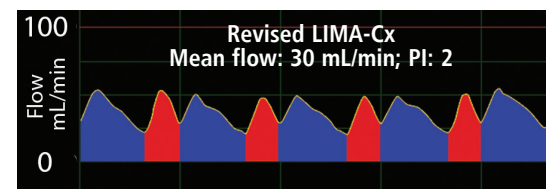
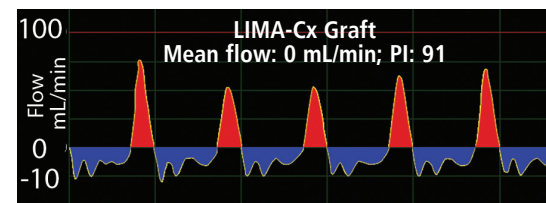
Zero Mean Flow Demands Revision of LIMA-Cx Graft



Case demonstrates serious problem with a graft when flow measures 0 mL/min.

A 78-year-old female patient underwent single coronary bypass grafting to bypass a blocked circumflex (Cx) coronary artery with the LIMA. Flow first measured 0 mL/min (PI: 91) following anastomosis of the LIMA to the Cx. The flow waveform had a spiky systolic profile (top waveform). Revision was demanded.

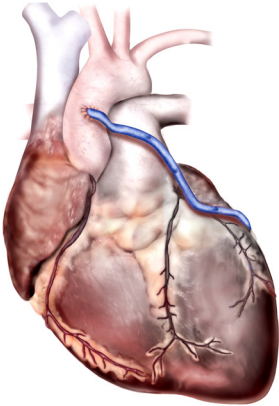
Following revision of the graft, mean graft flow improved to 30 mL/min (PI: 2), and the waveform exhibited a balanced systolic/diastolic profile (bottom waveform). Zero mean flow was the determining factor in the decision to revise the graft.



The top waveform exhibited a spiky systolic profile, which, accompanied by zero mean flow, called for the surgeon to revise the LIMA-Cx graft without hesitation. Flow improved to 30 mL/min after revision and the waveform exhibited a balanced LIMA-Cx profile (bottom waveform).

Provide Graft Patency Assurance

Zero Flow in SVG-Cx Graft Reveals Clot

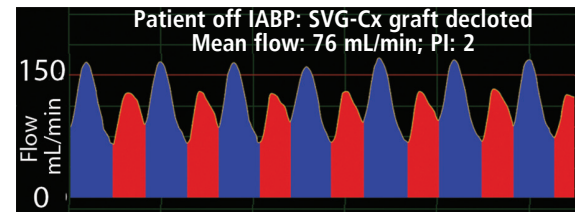
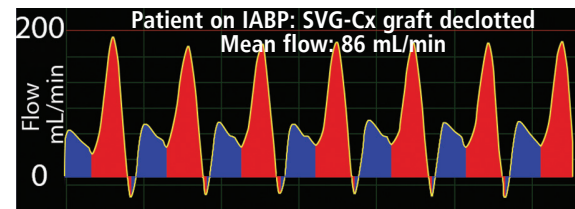
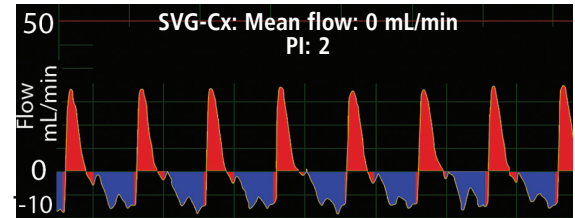


Case demonstrates that IABP support does not significantly influence flow.

An 81-year-old male patient underwent CABG surgery to bypass a blocked circumflex (Cx) coronary artery. A harvested saphenous vein graft (SVG) was used to connect the aorta to the Cx distal to the lesion (top waveform).

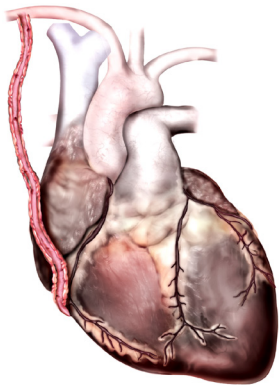
Following anastomosis of the SVG to the Cx, graft flow measured 0 mL/min, clearly indicating that there was a problem. Investigation revealed a clot in the graft. The patient was placed on IABP support. The graft was declotted and flow was remeasured with the patient still on IABP support. Flow measured 86 mL/min (middle waveform).

When the IABP support was removed, graft flow measured 76 mL/min (PI: 2) indicating that the presence of an IABP did not significantly affect graft flow (bottom waveform).



Three waveforms above show a progression from a clotted graft with zero mean flow (top waveform) to a declotted graft on IABP (mean flow, 86 mL/min) to the declotted graft with IABP removed (mean flow, 76 mL/min, bottom waveform).

RIMA-RCA Graft Flow Suppressed by Competitive RCA Flow



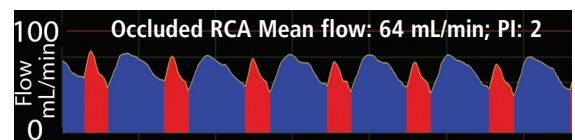
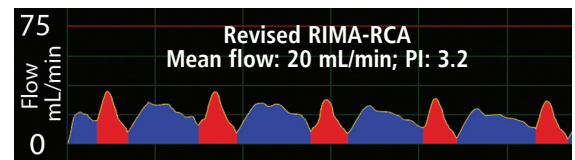
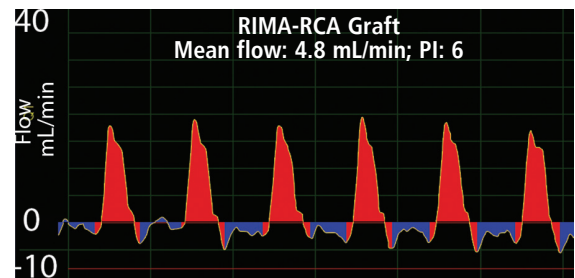
Case demonstrates that competitive flow from a native coronary can suppress graft flow.

A 60-year-old male underwent CABG to bypass a blockage in his right coronary artery (RCA) with a right internal mammary artery graft (RIMA).

Following the RIMA-RCA anastomosis distal to the blockage, flow measured 4.8 mL/min (PI: 6). Low mean flow, a high PI and a systolic dominant waveform profile indicated the need for graft revision.

After revision, flow improved to 20 mL/min (PI: 3.2), but this flow was not as high as the surgeon expected given the size of the patient. Suspecting the presence of competitive flow from the native RCA, the surgeon occluded the native RCA proximal to the anastomosis of the graft. Mean graft flow increased to 64 mL/min (PI: 2). Another graft was added, placed more distally on the RCA. Runoff improved, competitive flow decreased and graft flow was > 40 mL/min.

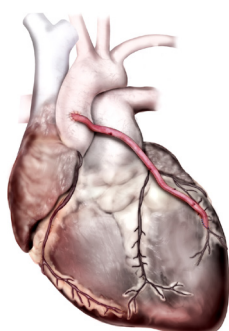
The significant increase in mean graft flow supported the surgeon's suspicion that competitive flow was suppressing graft flow.



The three waveforms show the systolic dominant profile of the RIMA-RCA graft before revision (top), the systolic/diastolic flow waveform profile following revision of the graft (middle), and the similar graft waveform with the proximal RCA occluded (bottom).

Flow-based Patency Assurance

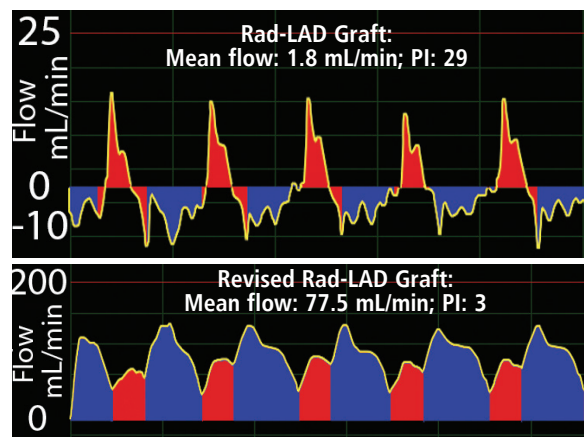
Poor Rad-LAD Graft Flow Triggers Graft Revision



Case demonstrates that poor flow signals need for graft revision.

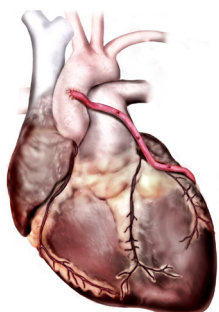
A 71-year-old male with single-vessel coronary artery disease underwent CABG surgery. A segment of the radial artery (Rad) was harvested and grafted proximally to the aorta and distally to the LAD. Initial Rad-LAD mean flow measured 1.8 mL/min (PI: 29) indicating that revision of the graft was warranted (top waveform).

After revision, graft flow improved to 77.5 mL/min (PI: 3). The flow was accompanied by a repetitive systolic/diastolic waveform profile (bottom waveform).



The top Rad-LAD waveform exhibits a spiky systolic profile and is coupled with an initial graft flow of 1.8 mL/min. Following revision of the graft, flow increased to 77.5 mL/min and was accompanied by a diastolic dominant waveform (bottom).

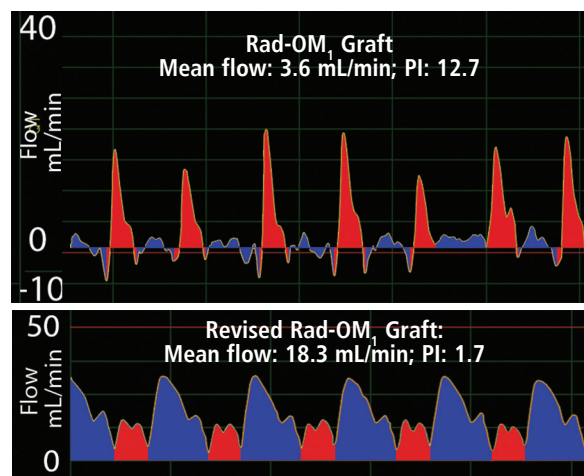
Low Mean Flow Spurs Rad-OM₁ Graft Revision



Case demonstrates that poor flow in one out of four grafts signals need for need for graft revision in that one graft.

A 48-year old male patient with multi-vessel coronary artery disease underwent quadruple CABG. Four grafts including a LIMA-LAD, SVG-OM, SVG-Dx and Rad-OM₁ were constructed to deliver flow to the distal myocardium. Mean flows in the LIMA-LAD, SVG-OM and SVG-Dx grafts were acceptable.

However, mean Rad-OM₁ graft flow measured 3.6 mL/min (PI: 12.7) signaling the need for revision of the graft. Following Rad-OM₁ graft revision, mean graft flow improved to 18.3 mL/min (PI, 1.7) and was accompanied by a systolic/diastolic waveform.



The top waveform with a spiky systolic profile shows initial Rad-OM₁ graft flow of 3.6 mL/min. Following revision of the graft, flow increased to 18.3 mL/min and was accompanied by a diastolic dominant waveform profile (bottom waveform).

transonic
THE MEASURE OF BETTER RESULTS.
www.transonic.com

Transonic Systems Inc. is a global manufacturer of innovative biomedical measurement equipment. Founded in 1983, Transonic sells "gold standard" transit-time ultrasound flowmeters and monitors for surgical, hemodialysis, pediatric critical care, perfusion, interventional radiology and research applications. In addition, Transonic provides pressure and pressure volume systems, laser Doppler flowmeters and telemetry systems.

AMERICAS

Transonic Systems Inc.
34 Dutch Mill Rd
Ithaca, NY 14850
U.S.A.
Tel: +1 607-257-5300
Fax: +1 607-257-7256
support@transonic.com

EUROPE

Transonic Europe B.V.
Business Park Stein 205
6181 MB Elsloo
The Netherlands
Tel: +31 43-407-7200
Fax: +31 43-407-7201
europe@transonic.com

ASIA/PACIFIC

Transonic Asia Inc.
6F-3 No 5 Hangsiang Rd
Dayuan, Taoyuan County
33747 Taiwan, R.O.C.
Tel: +886 3399-5806
Fax: +886 3399-5805
support@transonicasia.com

JAPAN

Transonic Japan Inc.
KS Bldg 201, 735-4 Kita-Akitsu
Tokorozawa Saitama
359-0038 Japan
Tel: +81 04-2946-8541
Fax: +81 04-2946-8542
info@transonic.jp