

The muscular system is like a giant pulley system.

Muscles work with and against each other in order for you to do all the things you do.

Muscle Premium takes a dive into the human muscular system with muscle origins and insertions, interactive animations, quizzing, and more.

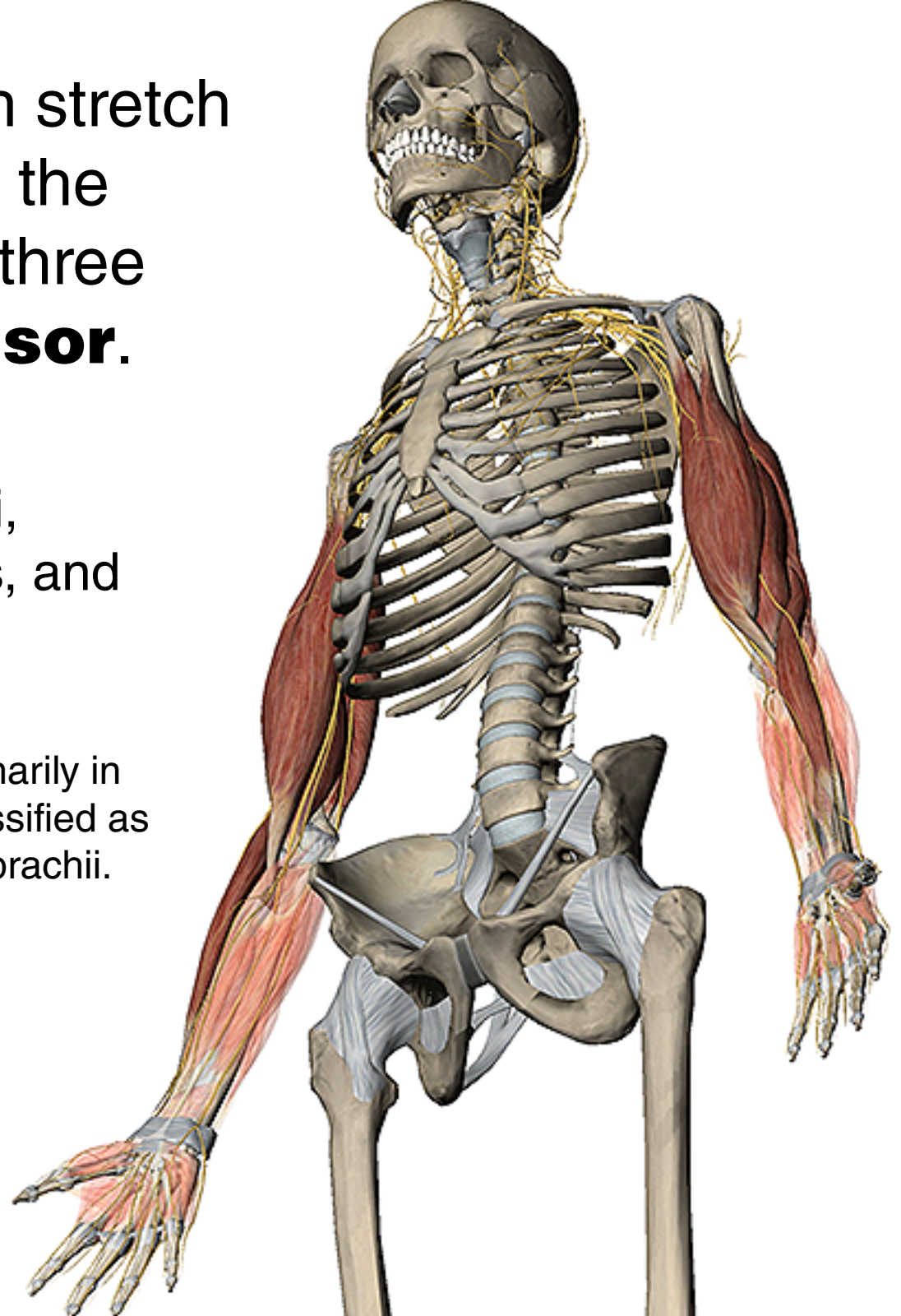
Let's take a look!



The **arm** muscles (which stretch from the shoulder joint to the elbow) are comprised of three **flexors** and one **extensor**.

They are the biceps brachii, coracobrachialis, brachialis, and the triceps brachii.

Factoid: The **anconeus**, primarily in the forearm, is sometimes classified as the fourth head of the triceps brachii.

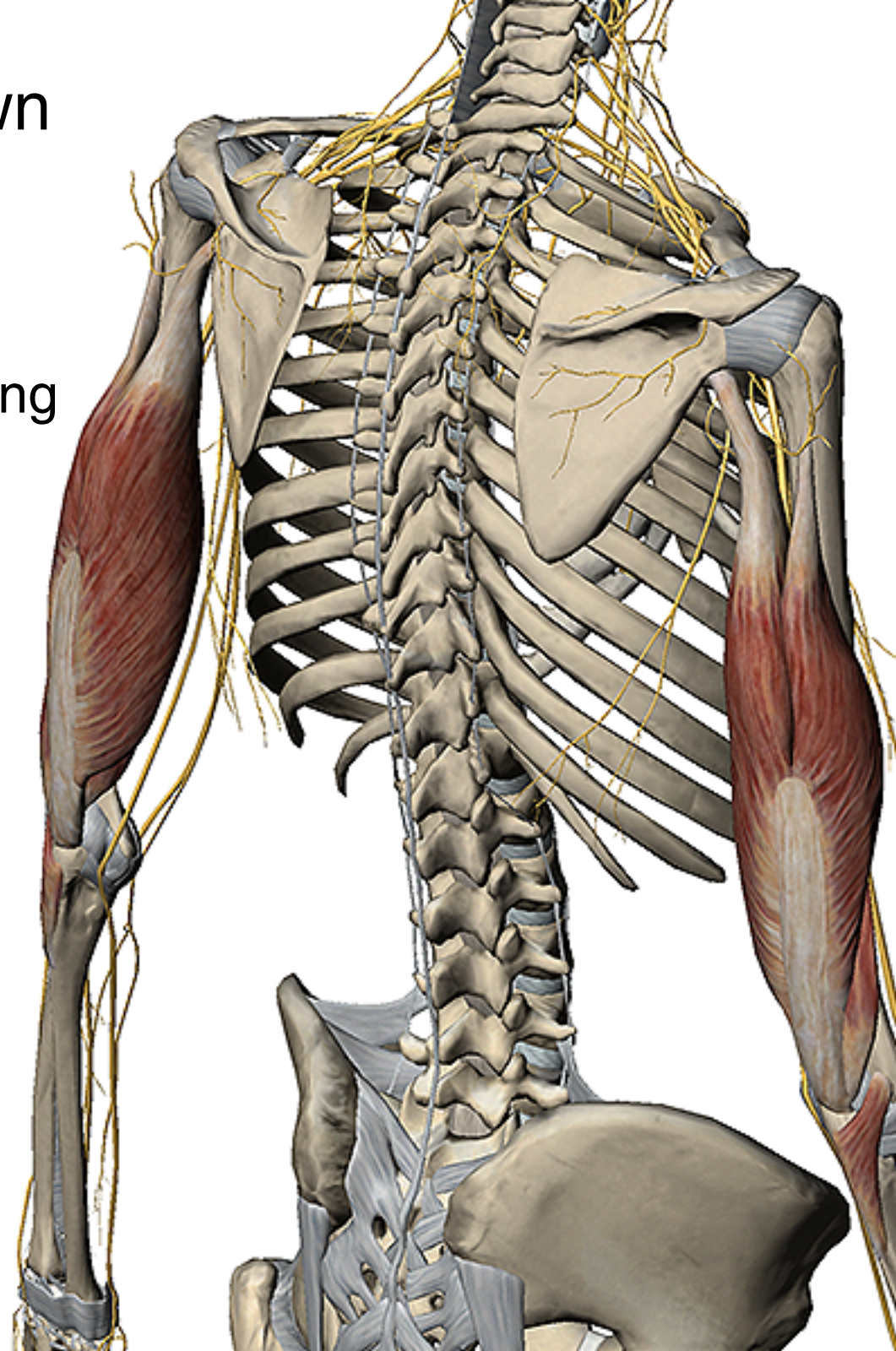


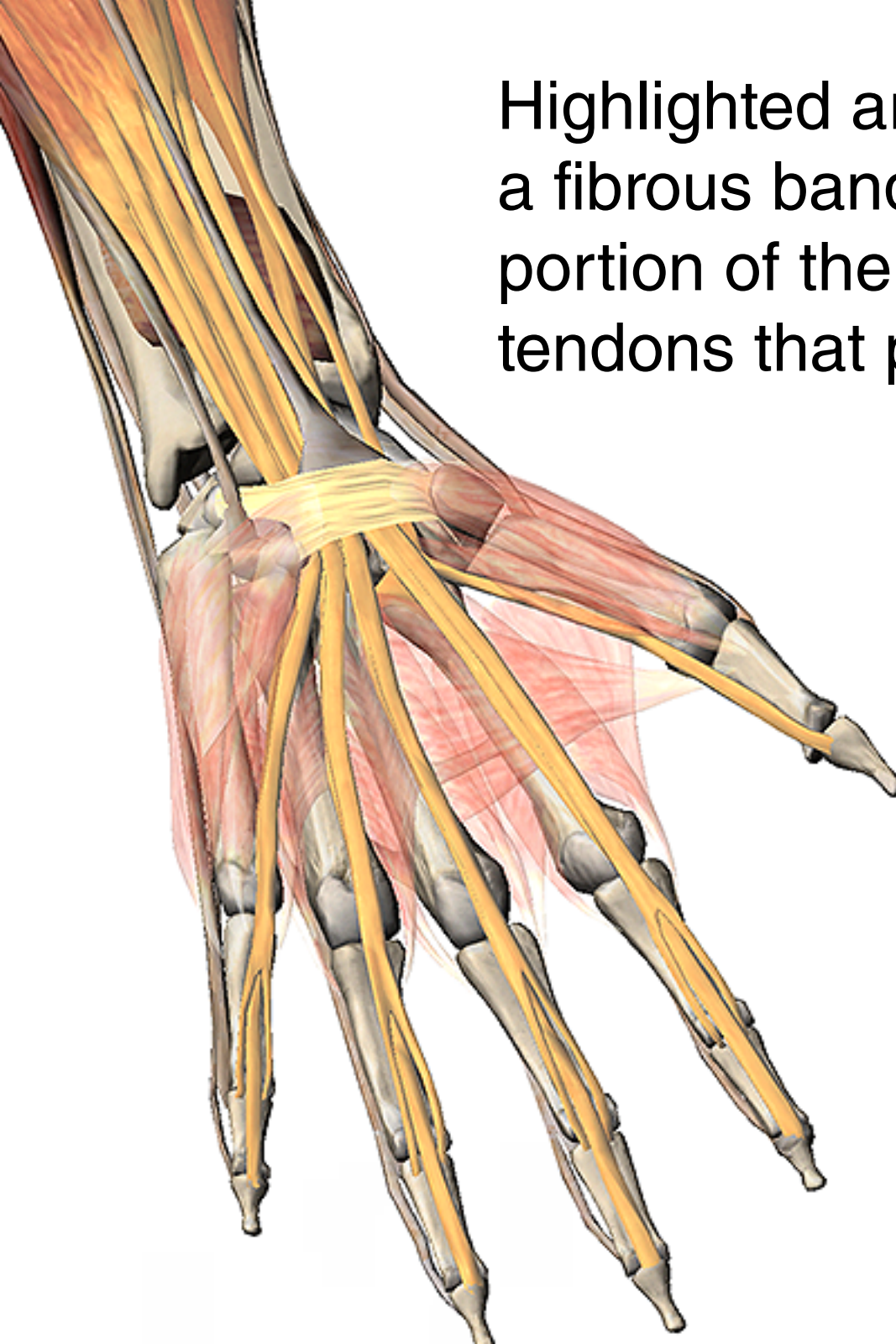
The **triceps brachii** (shown with the **anconeus**) is the main extensor of the arm.

It is primarily responsible for extending the elbow joint.

As implied by its name, the triceps has three heads: the lateral head, the long head, and the short head.

All three comprise the **triceps tendon**.



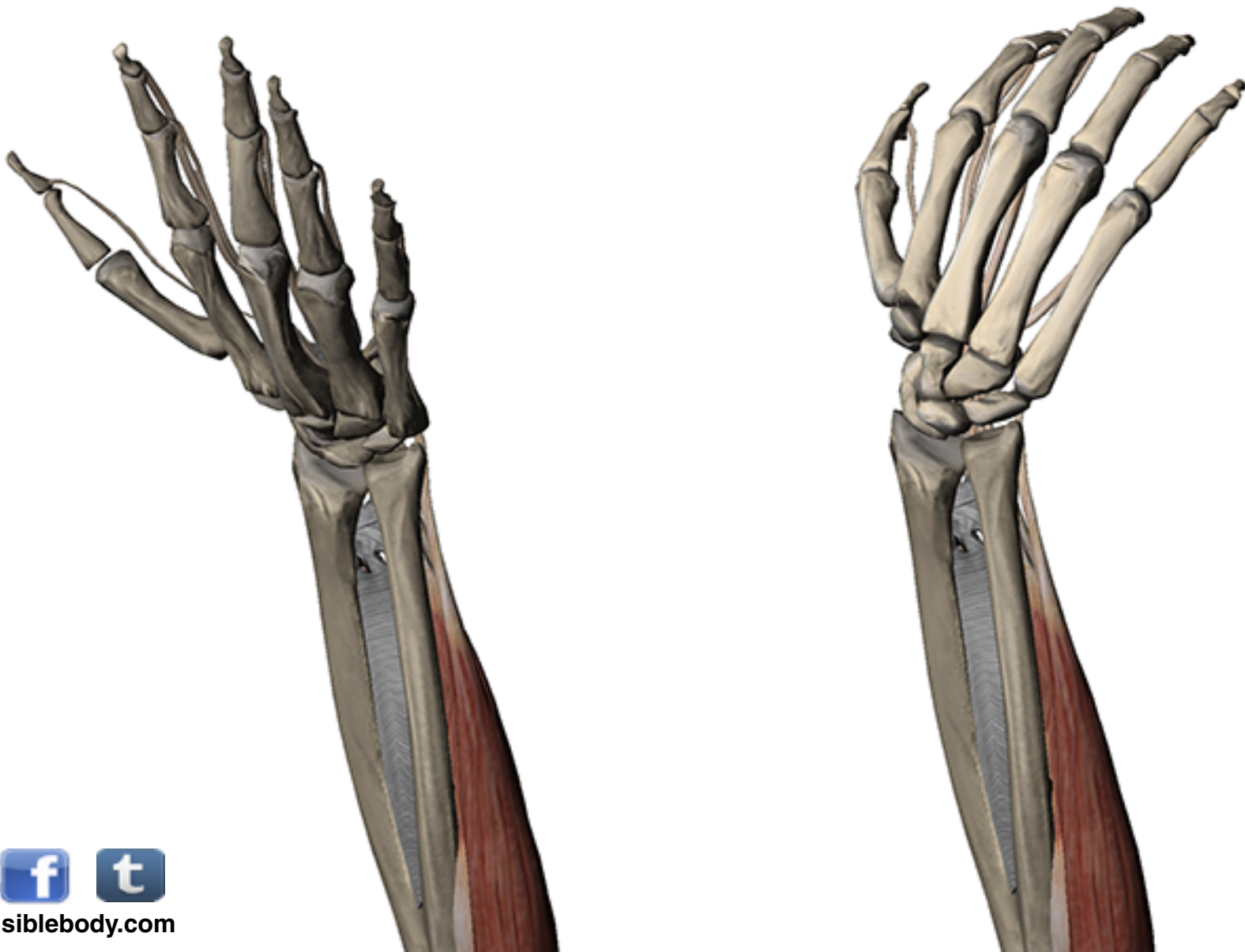


Highlighted are the **flexor retinaculum**, a fibrous band, which forms the anterior portion of the **carpal tunnel**, and the tendons that pass through it.

When these tendons swell or break down, they trap the **median nerve** that passes through the tunnel, which causes pain, numbness, and parathesia (“pins and needles”).

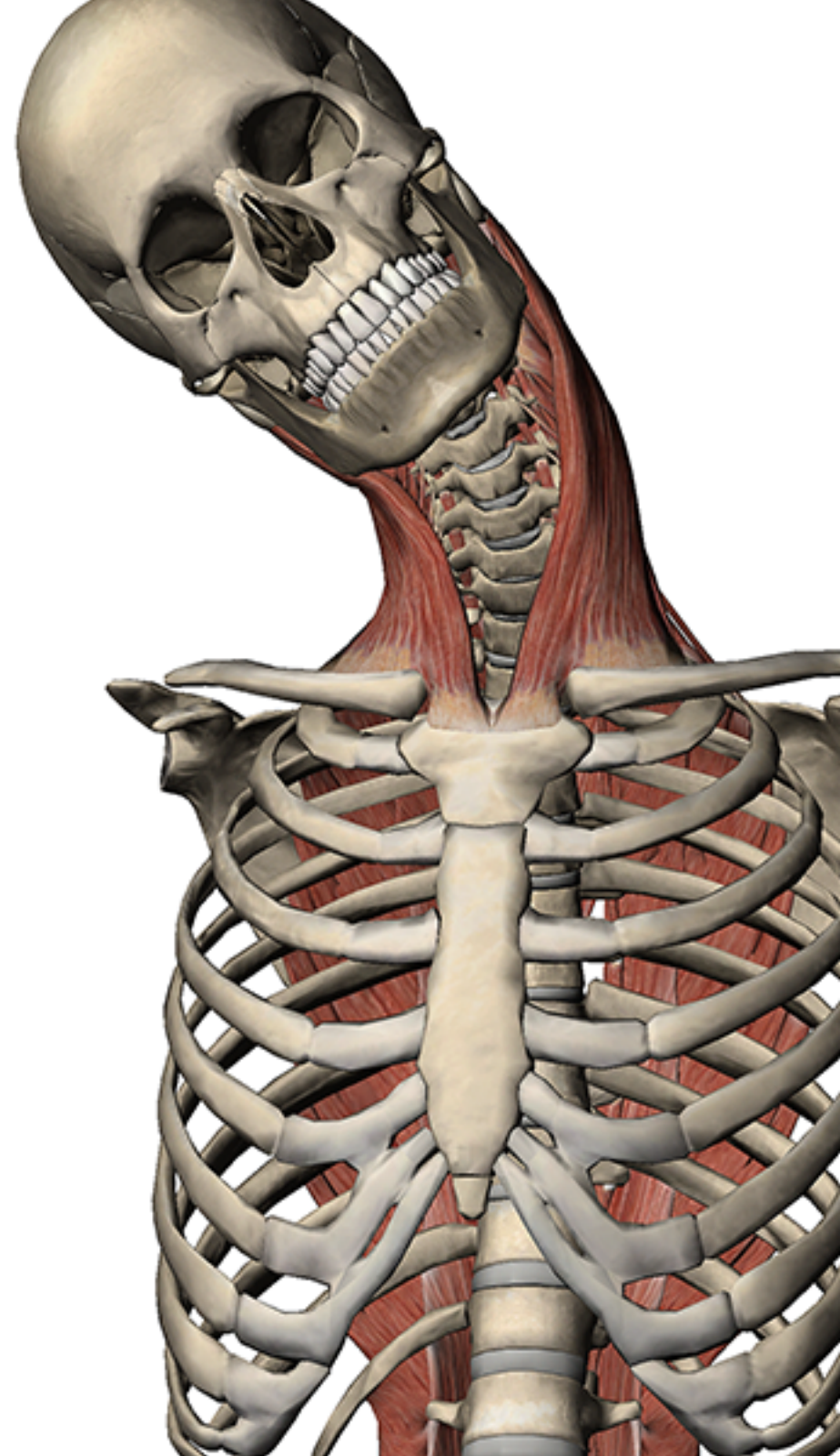
Factoid: About 3% of women and 2% of men will be diagnosed with **carpal tunnel syndrome** during their lifetime. That’s over 9 million people in the United States alone.

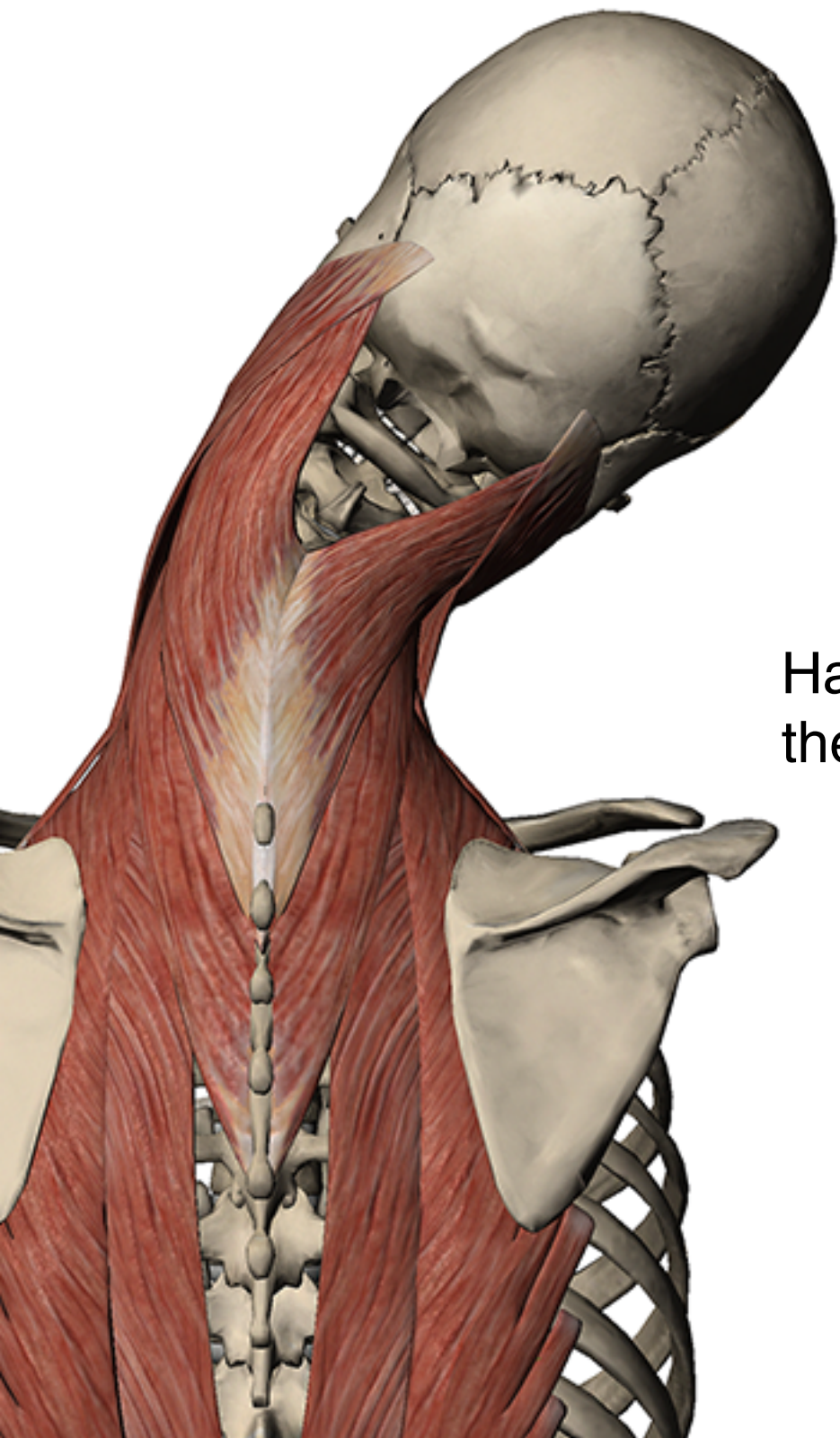
Want to see the wrist flexors in action?
Click [here](#) to watch a video of wrist flexion.



The **sternocleidomastoids** (SCM) originate on the manubrium and the clavicle, and are involved in **lateral flexion** of the neck.

In the image, the left SCM is contracted to draw the head to the shoulder.

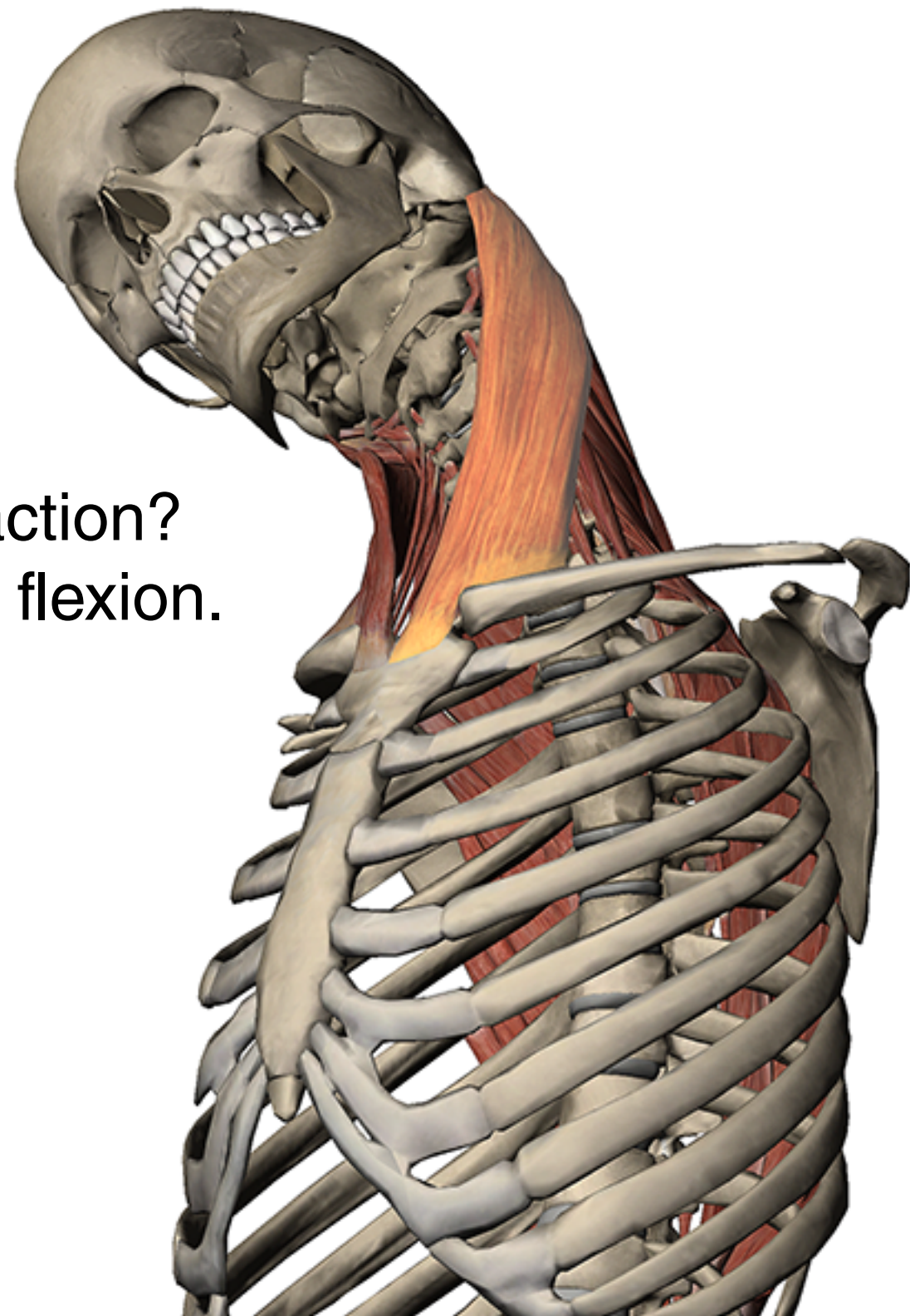




In this posterior view of lateral flexion, the **splenius capitis** muscles also contribute to draw the head toward the shoulder.

Having muscles in the front and back of the neck help to **stabilize** movement.

Want to see the SCM in action?
Click [here](#) to watch lateral flexion.




Hold it right there!

Quick review.


Origins and **insertions** are where the muscle **attaches** to a structure, either a bone or other tissue.

Muscles tend to have more **mass** at the origin.

The structure that the **origin** is attached to tends to be moved by the **muscle contracting**.



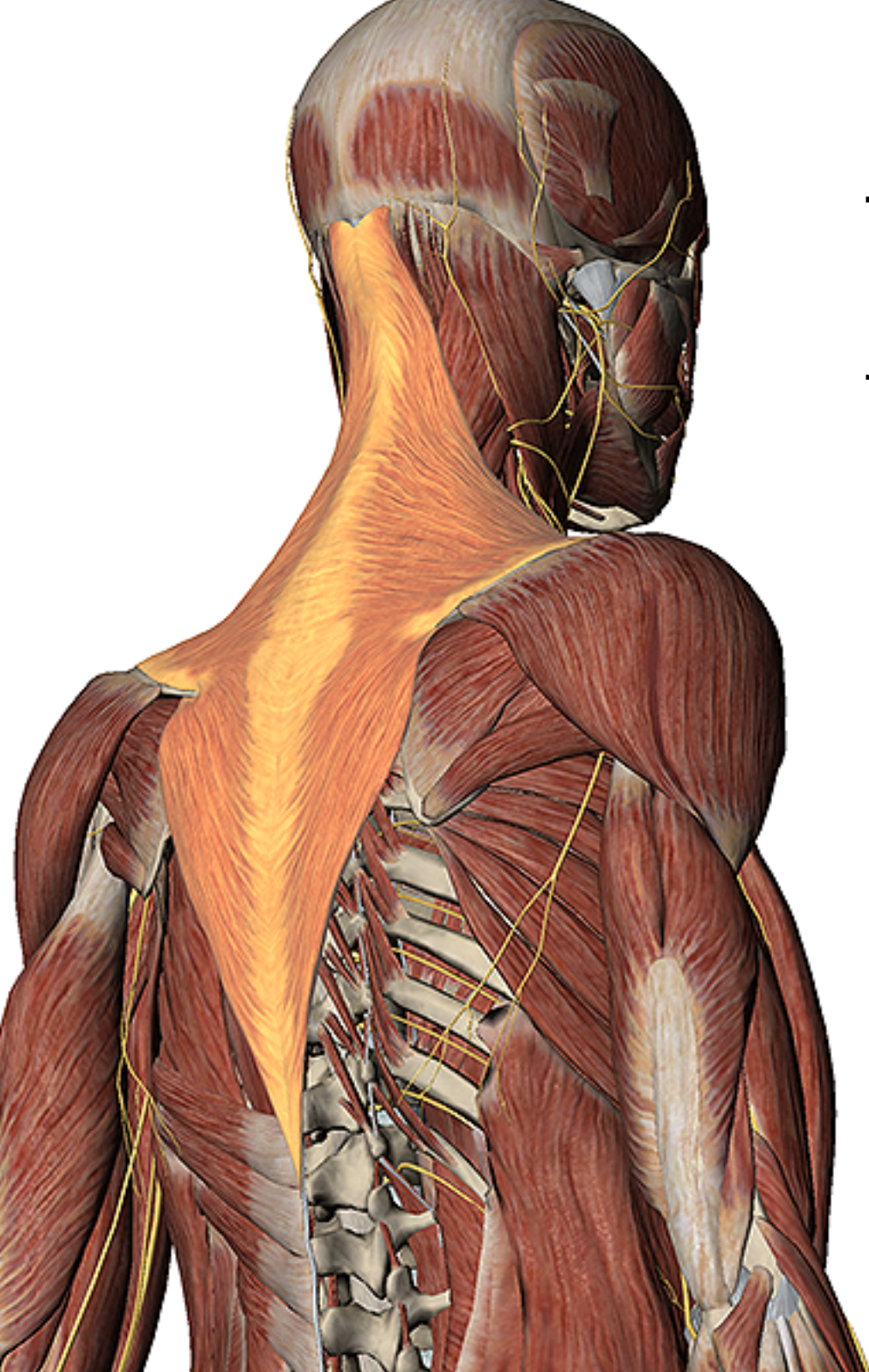
Muscle Premium marks origins in red on the skeleton using these nifty red pins.



The opposite end of the origin is the **insertion**.

It tends to move while the structure of the origin is **stabilized**.

Insertions are marked in blue on the skeleton and use these cool blue pins.



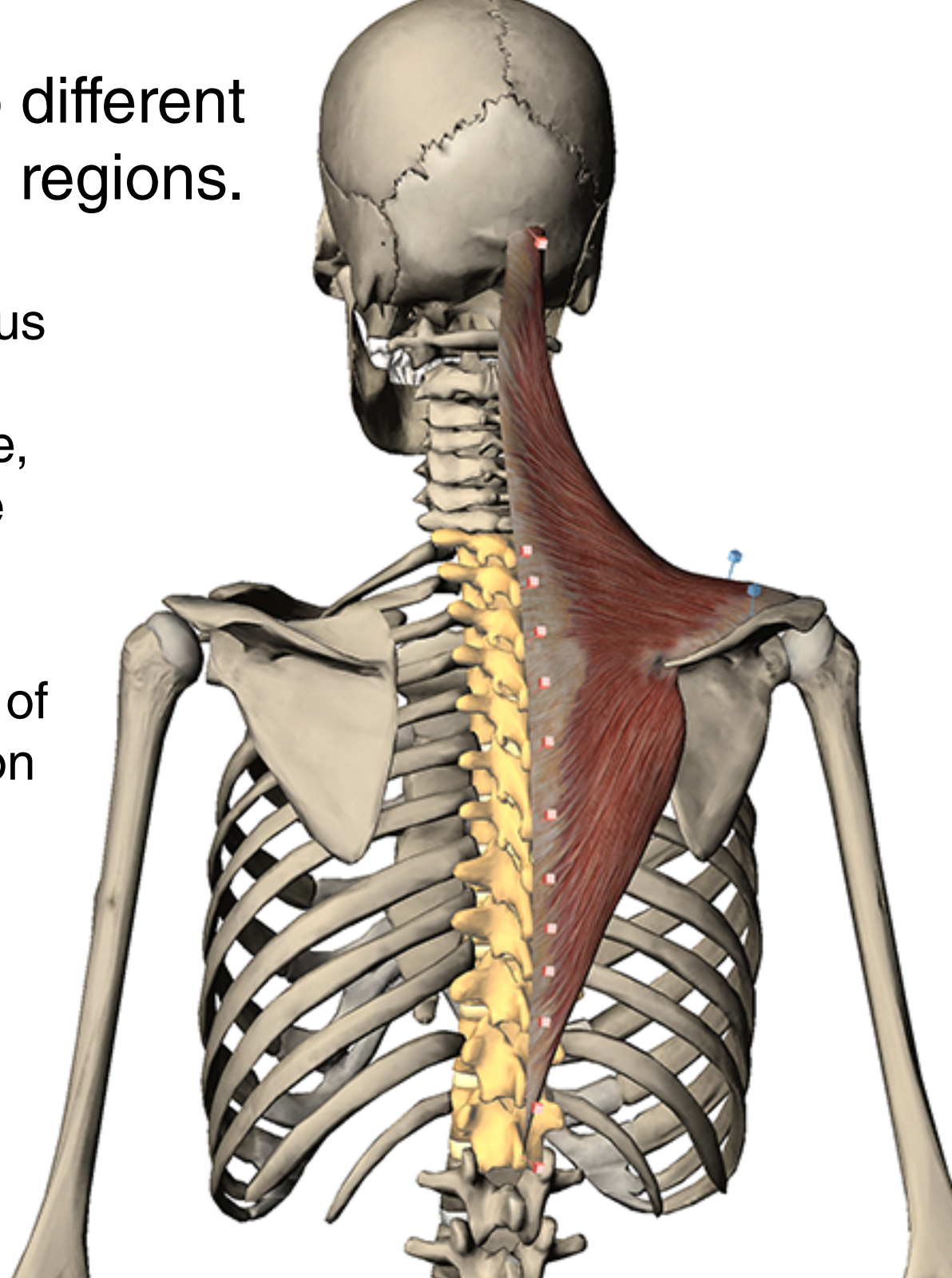
The **trapezius** is a broad muscle of the **thorax** named for its trapezoidal shape.

It covers the upper and back parts of the neck and shoulders, and is involved in extending the head, neck, and scapula.

The trapezius attaches to different bones in multiple skeletal regions.

It **originates** on the spinous processes of the thoracic vertebrae, the occipital bone, and the ligamentum nuchae (not shown).

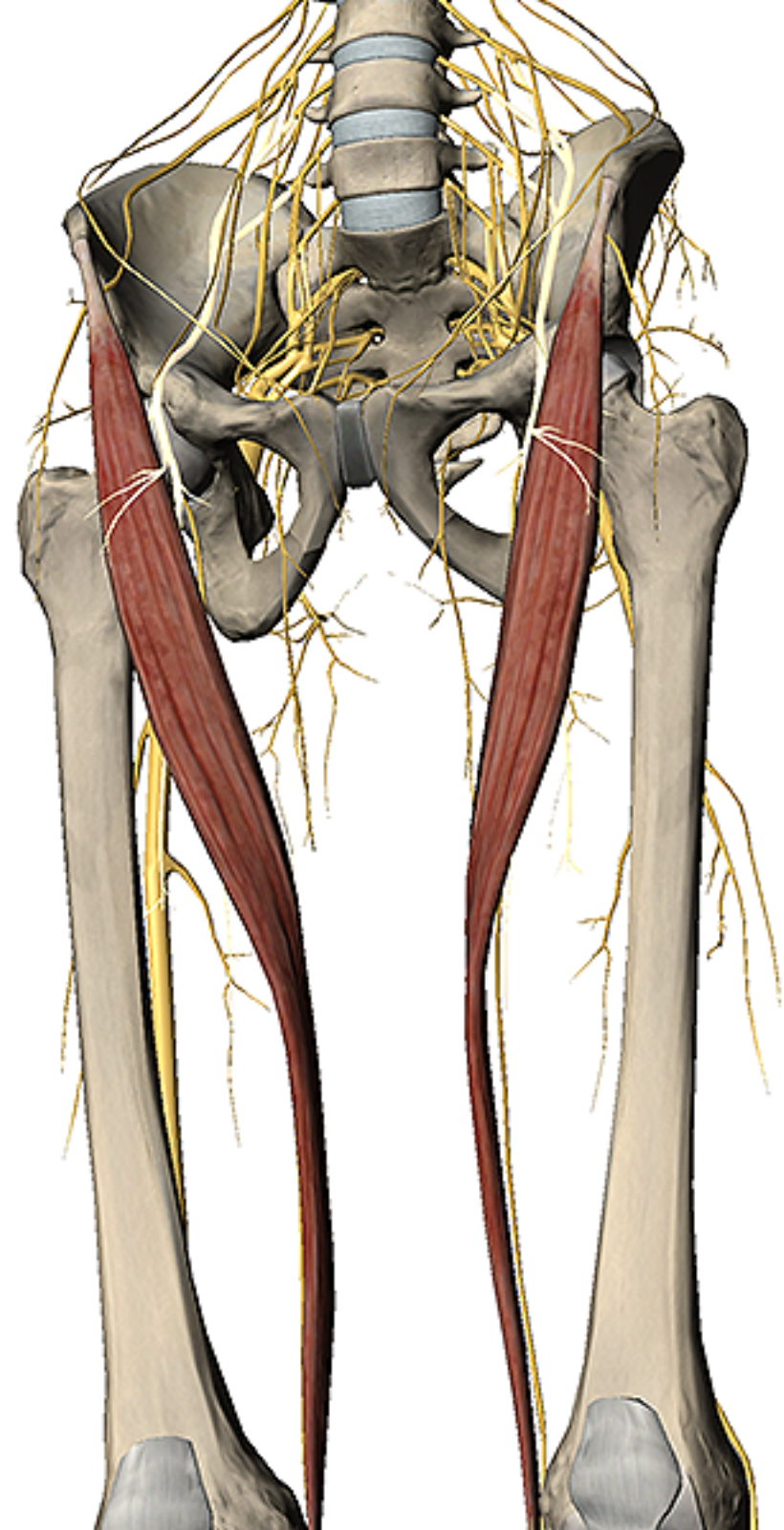
It inserts on the lateral third of the clavicle and the acromion and scapular spine of the scapula.



The **sartorius** is a long muscle in the proximal (upper) leg of the lower extremity.

It is part of the **pes anserinus**, which also includes the gracilis and the semitendinosus.

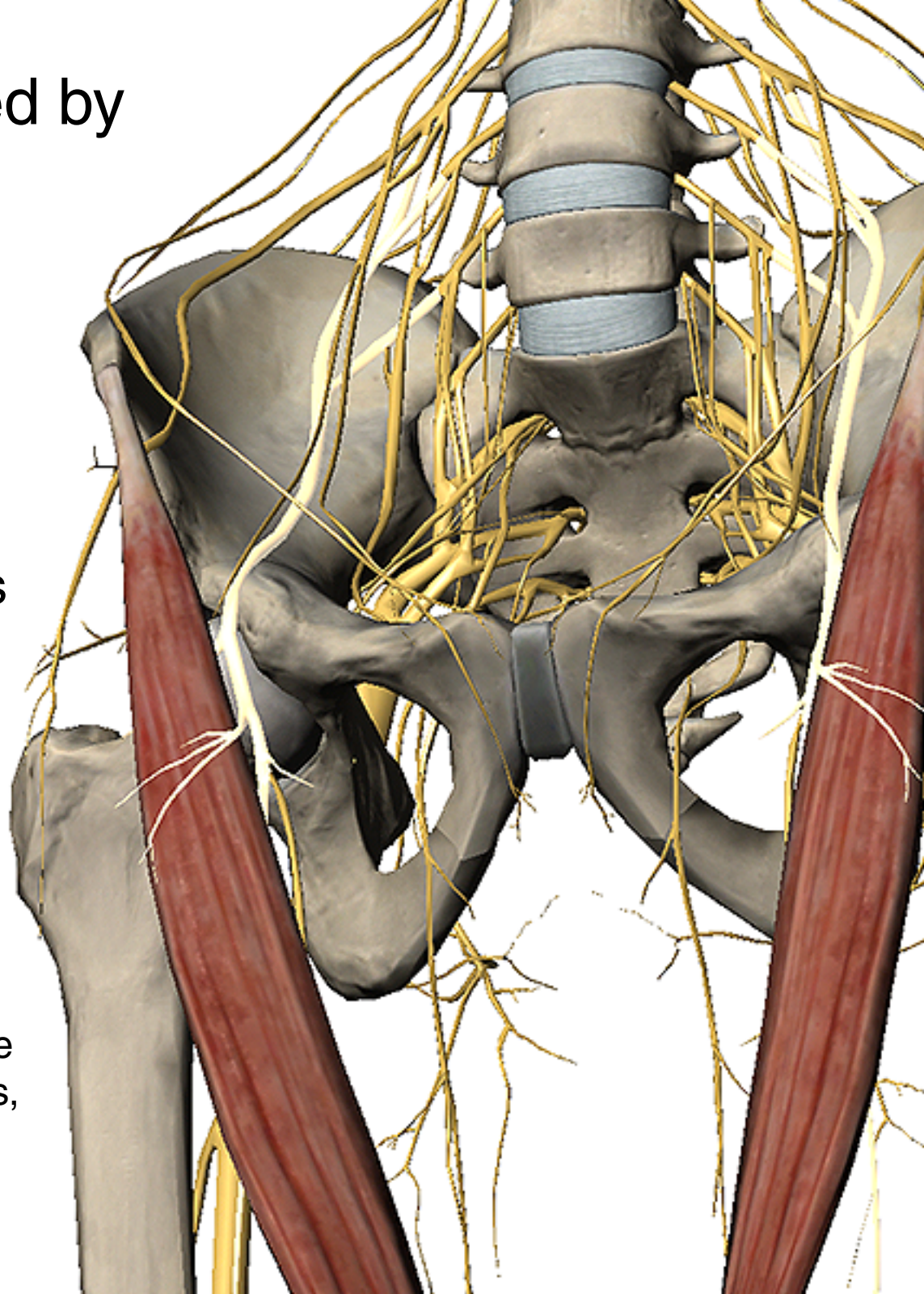
Factoid: the sartorius is the longest muscle in the human body.

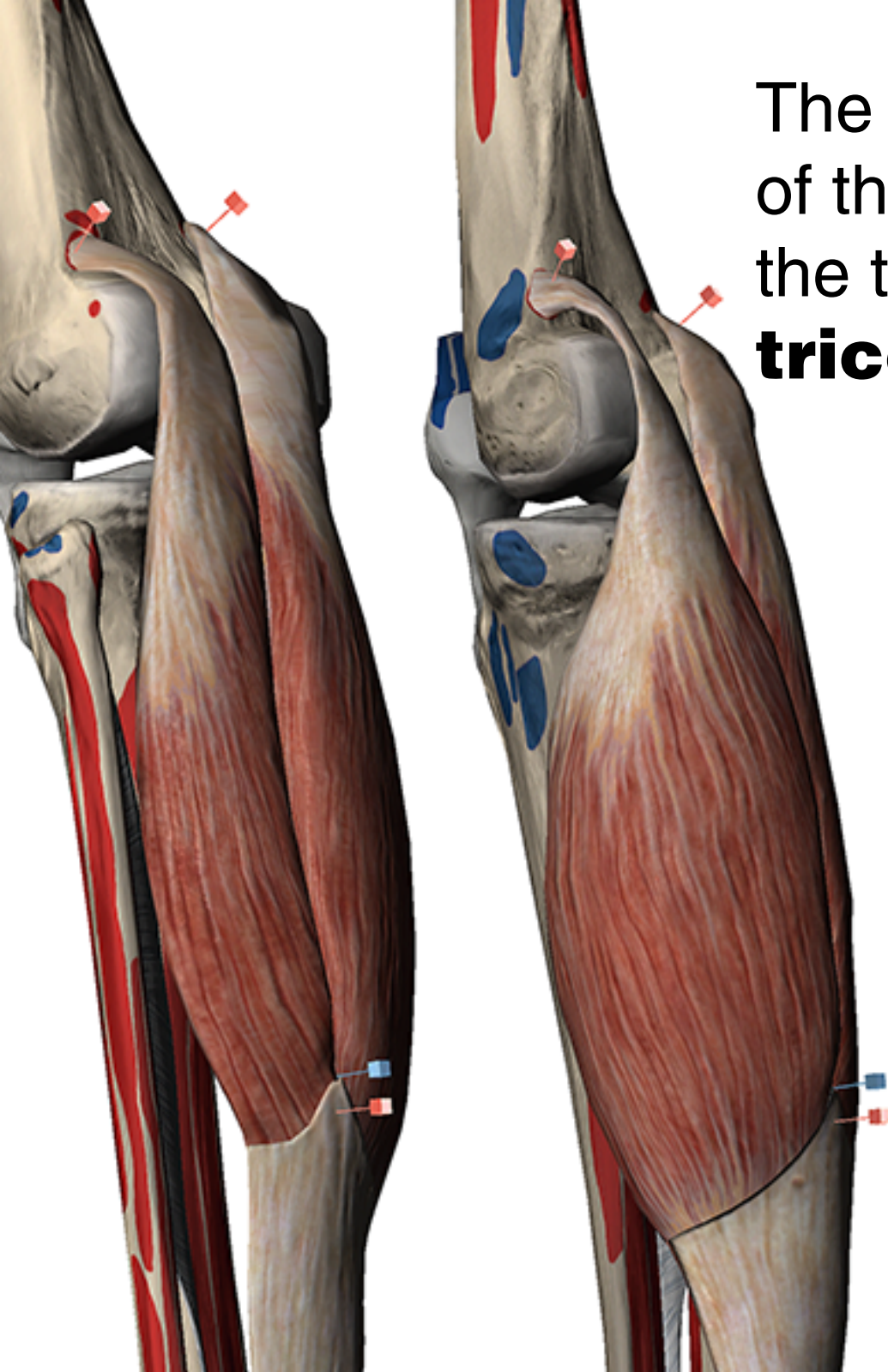


The sartorius is innervated by the **femoral nerve**.

The femoral is part of the **lumbosacral plexus**, from which some of the major nerves of the lower limbs derive, such as the **sciatic nerve**.

Factoid: Sciatica is a common pathology in which pain radiates along the path of the sciatic nerve, affecting the lower back, hips, buttocks, and lower limbs.





The two-headed **gastrocnemius** of the distal leg group is one of the two muscles that make up the **triceps surae**.

The gastrocnemius originates on the condyles of the femur (top red pins) and inserts into the Achilles tendon (blue pins).

This muscle helps to flex the knee at the joint, as well as flex the **plantar region** of the foot.

Muscle Premium

All the images and text in this eBook came from Visible Body's Muscle Premium app—an encyclopedic anatomical reference for human musculature.

Content in the app includes:

- 600+ muscles, 200+ bones, peripheral nerves, and ligaments all rendered in interactive 3D, as well as dozens of interactive muscle action animations.
- Functionality that allows you to rotate, zoom in/out, pan, hide, and add structures to see the anatomy from any angle. Customize and save Views.
- Dozens of quizzes to test your knowledge.

Muscle Premium is available for [iOS](#), [PC](#), [Mac](#), and [Android](#).

