

Use of Pure Metallic Silver

Plated to Nylon Dressing for:

Recalcitrant Wounds

Pyoderma Gangrenosum

Diabetic Neuropathy

Arthritis

Infection

Mixed Vascular

Connective Tissue Disease

ONE PROTOCOL

1. Rinse with sterile water *
2. Place silver contact dressing on wound **
3. Cover with secondary dressing of choice
4. Leave in place for 24 hours up to 7 days, subject to exudate ***

1. Rinse wound per your protocol
2. Rinse silver contact dressing
3. **Re-apply silver contact dressing**
4. Cover with secondary dressing

Repeat process as necessary. Replace silver contact dressing after 7 days

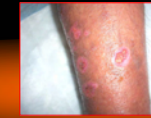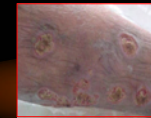
* Silverlon can go on dry, but a moistened dressing w/sterile, distilled, or tap water is preferred

** Dry contact dressing can be left in place longer than 24 hours

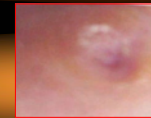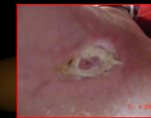***Silverlon should be sized 2 cm larger than wound & overlap normal periwound skin

Before

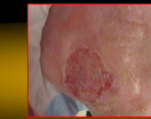
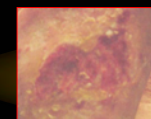
After



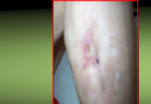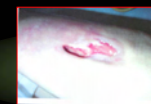39 yo male with cirrhosis of liver with pyoderma gangrenosum for 12 wk duration: Tx in conjunction with IV antibiotic therapy
Healed: 2 mos



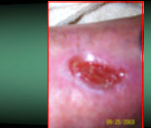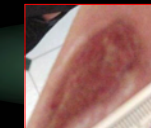53 yo male with IDDM with osteomyelitis to plantar surface of foot for 18 mos duration, had been tx with IV antibiotics and growth factors prior to treatment.
Healed: 4 mos



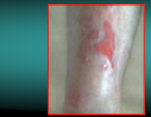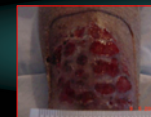79 yo female with dwarfism and long-standing dystocia of hips, severe Arthritis, recurrent cellulitis and pain
Duration of wound 4 years
Healed 4 mos.



76 yo female with Metastatic Cancer with a staph infection to the leg
Duration of wound: 5 mos
Pain diminished in 2 weeks, status is Healing at 4 mos.



88 yo with trauma wound to leg for 12 mos duration. Experienced severe pain that interrupted her sleep at nite.
Pain diminished in 10 days, sleeps through nite. Healing in 4 mos.



78 yo female with advanced vascular and connective tissue disease and SLE
Skin friable. Used product in conjunction with mesh dressing. Healed within 3 mos.

Mary Foote

RN MSN ANP CWCN ED.Dc

Woundcare On Wheels, Inc.