

# High-intensity Focused Ultrasound: Ready for Primetime

Kyle O. Rove, MD<sup>a</sup>, Kathryn F. Sullivan, MD<sup>b</sup>,  
E. David Crawford, MD<sup>c,d,e,\*</sup>

## KEYWORDS

- Prostate cancer • High-intensity focused ultrasound
- HIFU • PSA • Biochemical recurrence

Prostate cancer (CaP) is the second most common cause of cancer deaths in the United States, and the incidence of CaP has remained constant at 165 cases per 100,000 men.<sup>1</sup> Since 1990, the age-adjusted death rate has decreased by 31%. The decrease in death rate is most likely due to early detection and treatment.<sup>1</sup> The decrease in mortality has not been as significant as expected compared with the increase in diagnosis of CaP. The discrepancy between incidence and mortality has been attributed to increasing detection of clinically insignificant tumors.

Furthermore, prostate screening (ie, digital rectal examination [DRE] and prostate specific antigen [PSA]) may identify clinically insignificant cancers and result in over diagnosis and over treatment of prostate cancer. CaP screening may result in over treatment of prostate cancer by at least 30%.<sup>2</sup> Since the beginning of the PSA era, CaP screening has shifted the disease burden to organ-confined and lower-grade disease.<sup>3</sup> Etzioni and colleagues<sup>4</sup> estimated that 10% of men with low-grade prostate cancer are over treated with

radical surgery, and 45% are over treated with radiation therapy.

Some of the side effects of radical prostatectomy and radiation therapy include urinary incontinence and impotence. The incidence of these morbidities has decreased with improved technique; however, these morbidities are significant for individuals who may be over treated for their otherwise indolent CaP.<sup>3</sup>

Once diagnosed with CaP, a patient must make an informed decision on which mode of treatment to pursue. This decision is made more difficult by the varied modalities, invasiveness, outcomes, and return to baseline function after treatment. Moreover, treatment type depends on clinical stage, Gleason grade, patient preference, and other comorbid conditions.<sup>3</sup> Treatment types include active surveillance, radical prostatectomy, cryotherapy, and radiation therapy (either brachytherapy or external-beam radiation).<sup>3</sup> In addition, several new and innovative therapies such as high-intensity ultrasound (HIFU) are being studied.

HIFU was introduced 15 years ago for the treatment of benign prostatic hypertrophy.<sup>5</sup> In 1996,

<sup>a</sup> Division of Urology, University of Colorado Anschutz Medical Campus, 12631 East 17th Avenue, Mailstop C302, Aurora, CO 80045, USA

<sup>b</sup> Division of Urology, University of Colorado Anschutz Medical Campus, 12631 East 17th Avenue, Mailstop C319, Aurora, CO 80045, USA

<sup>c</sup> Department of Surgery, University of Colorado Cancer Center, University of Colorado Anschutz Medical Campus, 12631 East 17th Avenue, Mailstop C319, Aurora, CO 80045, USA

<sup>d</sup> Division of Urology, University of Colorado Cancer Center, University of Colorado Anschutz Medical Campus, 12631 East 17th Avenue, Mailstop C319, Aurora, CO 80045, USA

<sup>e</sup> Department of Radiation Oncology, University of Colorado Cancer Center, University of Colorado Anschutz Medical Campus, 12631 East 17th Avenue, Mailstop C319, Aurora, CO 80045, USA

\* Corresponding author. Department of Surgery, University of Colorado Cancer Center, University of Colorado Anschutz Medical Campus, 12631 East 17th Avenue, Mailstop C319, Aurora, CO 80045.

E-mail address: [david.crawford@ucdenver.edu](mailto:david.crawford@ucdenver.edu) (E.D. Crawford).

Gelet and colleagues<sup>6</sup> used HIFU for the treatment of localized low-grade CaP. Many studies have been performed to evaluate the use of HIFU for low-grade, localized prostate cancer. HIFU has also been used as salvage therapy after radiation. The National Institute for Clinical Excellence (NICE) in the UK evaluated HIFU in 2005 and found that there was sufficient evidence to recommend its use for the treatment of CaP.<sup>7</sup> However, in 2008, NICE only recommended the use of HIFU in controlled clinical trials or when patients are entered into a registry and closely followed.<sup>8,9</sup> The French Association of Urology (FAU) and the Association of Italian Urologists (AURO) now recommend HIFU as standard treatment for patients with localized disease, who are unsuitable for or who failed radiation, or who are unsuitable for surgery.<sup>7</sup> The European Association of Urology guidelines, however, state HIFU is “investigational or experimental.”<sup>10</sup> In the United States, HIFU is currently not approved for treatment of CaP outside ongoing investigational trials. As more studies elucidate long-term disease-free rates, it is expected that consensus recommendations on the use of HIFU for localized CaP will soon emerge.

Recent response to the over diagnosis of CaP and over treatment of CaP by urologists has led to the need to consider other forms of therapy that have less morbid side effects and are less invasive. HIFU is a minimally invasive treatment of CaP and needs to be evaluated for efficacy that is similar to or exceeds other modalities of treatment, minimum side effects, quicker recovery from treatment, and hopefully reduced treatment costs. HIFU uses ultrasound energy to cause mechanical and thermal injury to the target tissue. In this article, the authors review the current literature on the experimental therapy for HIFU. The HIFU technique, its mechanism of action, patient selection, current efficacy studies, complications, follow-up after HIFU treatment, and future developments are discussed.

## HIFU TECHNIQUE

HIFU, when used for the treatment of localized prostate cancer, uses an ultrasound transducer placed in the rectum to generate acoustic energy that is focused on the tissue target, creating high temperatures and irreversible coagulative necrosis. HIFU uses a trackless principle, whereby tissue outside the focal plane is not damaged; the transrectal probe sits on the rectal mucosa and sends acoustic energy through the intervening tissues, only heating the tissue volume targeted by the probe.<sup>11</sup> The probe is repositioned mechanically as needed to target the entire prostate. This

technique is minimally invasive, requires less anesthesia and involves a shorter recovery period than surgery, and can be performed in a day surgery setting.

HIFU is generally performed with the patient under spinal or general anesthesia. The operation can last from 1 to 4 hours, and should not be performed with prostate volumes greater than 40 mL. Often, a limited transurethral resection of the prostate (TURP) is performed before application of HIFU to reduce the risk of postoperative urinary retention.<sup>12</sup> (Notably, study protocols of US trials do not permit the use of TURP before HIFU.) The patient is placed in the lithotomy position. The ultrasound probe is covered with a condom and inserted gently into the rectum using lubricating jelly. Once inserted, an articulating arm aids in maintaining the position of the probe. Cool water (17–18°C) is circulated through the condom to protect adjacent tissues from thermal damage throughout the procedure.<sup>13</sup> The prostate is visualized using real-time diagnostic images generated by the probe using lower, nondestructive acoustic energies (0.1–100 mW/cm<sup>2</sup>). Once the target areas are identified, the prostate tissue is ablated with high energies (1300–2200 W/cm<sup>2</sup>) focused in a small 1- to 3-mm-wide by 5- to 26-mm-long focal plane. Each pulse heats the tissue to 80 to 98°C over a 3-second period. The gland is revisualized with lower ultrasound energies between ablative pulses. The probe is then moved and rotated in a semi-automated manner (device-dependent) using lower-energy diagnostic images to target adjacent prostate tissue. The end goal is to create overlapping lesions until the whole gland is treated. Patients often require a urethral or suprapubic catheter for several days.

Body movement and breathing pose continued challenges to the application of this technology.<sup>14</sup> In addition, the small target volumes make it more difficult to achieve homogeneous treatment of the entire gland. Because the HIFU device settings are based on animal models with presumed uniform tissue characteristics, further difficulty arises from uneven absorption of the acoustic energy influenced by possible heat-resistant tumor cells, prostatic calcifications, and differences in local blood perfusion.<sup>15,16</sup>

## CURRENT MARKET PRODUCTS

Two commercially-available ultrasound-guided transrectal devices are currently used for the treatment of prostate cancer: the Ablatherm (EDAP TMS, Lyon, France) and the Sonablate 500 (Focus Surgery, IN, USA). While these devices are approved in the treatment of localized prostate

cancer in Asia and Europe, their use in the United States is currently limited to investigational, phase III trials only. Both HIFU devices are trackless, in that no tissue is damaged between the probe and the targeted area of tissue in the focal plane. The original Ablatherm employs two probes each with piezoceramic transducers, has fixed-power settings, and requires a transurethral resection of the prostate (TURP) to be performed preoperatively due to limitations in depth of treatment. A newer version uses a single probe with two transducers. One transducer is dedicated to imaging and the other to treatment, enabling real-time visualization during treatment. Additionally, the newer Ablatherm device has three dedicated treatment parameters for the different clinical scenarios, including primary treatment, repeat HIFU, and salvage therapy. The Sonablate 500 device offers greater mobility and customization of treatment settings, allowing for more surgeon control over the HIFU beam characteristics, including adjustment of focal length, energy and power delivered to the target. The device enables users to tailor treatment to the particular characteristics of a patient's prostate and disease burden through transverse and sagittal low-energy, real-time imaging and software monitoring of tissue changes. The Sonablate 500 also incorporates imaging of blood flow around the neurovascular bundles; a clinician can alter treatment based on this visual feedback. Because the volume of tissue targeted by the Sonablate 500 is smaller than that of the more automated Ablatherm device, more manual manipulation of the transrectal probe is required.<sup>17</sup>

## MECHANISM OF ACTION

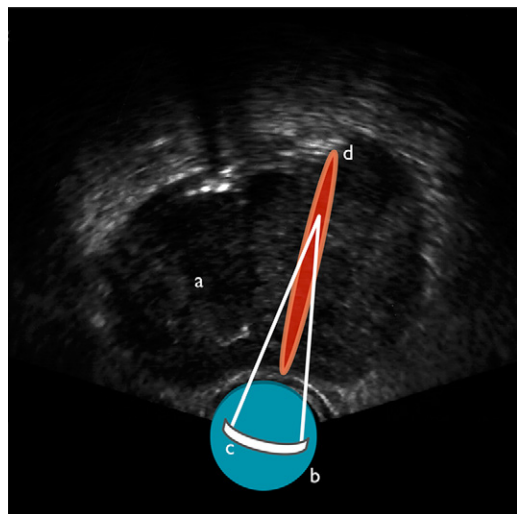
The application of high-intensity ultrasound in medicine began with studies in 1954 by Lindstrom and Fry, who were investigating the possibility of its use in the treatment of neurologic disorders.<sup>18,19</sup> Fry and colleagues<sup>20</sup> also discovered that in focusing these high-energy acoustic waves, they could be used safely in vivo. Attempts were made to apply its use in tumors of various organs throughout the 1970s, but at lower energies for long durations. Without any method to measure target tissue temperatures noninvasively, however, this investigational treatment modality fell out of favor. In the 1980s, extracorporeal shockwave lithotripsy came to the forefront with its approval for use by the Food and Drug Administration (FDA) in 1984, allowing for the noninvasive treatment of kidney stones.<sup>21</sup> In the 1990s, HIFU as a treatment of soft-tissue tumors was revived after advancements in the underlying technology, namely with the introduction of noninvasive tissue

temperature monitoring. Its origination in the treatment of prostate cancer came from the canine prostate experiments by Gelet,<sup>22</sup> Bihrlé,<sup>23</sup> and Kincaide and colleagues.<sup>24</sup>

HIFU destroys target tissue through the thermal and mechanical effects of nonionizing, acoustic radiation (ie, sound waves) delivered to target tissues after focusing by an acoustic lens, bowl-shaped transducer, or electronic phased array (Fig. 1). Because HIFU uses nonionizing radiation, it can be repeated one or more times in multiple sessions. The thermal effects are achieved by heating tissues to 60°C or higher, resulting in near-instantaneous coagulative necrosis and cell death.<sup>25</sup> By focusing the energy, more destruction occurs within the focal plane, but tissues outside the target area are spared damage, as energy intensities are far lower.

## Mechanical Effects of HIFU

The use of high-frequency sound waves results in various, significant mechanical effects on the tissues in addition to the thermal effects just mentioned. These include cavitation, microstreaming, and radiation forces. Cavitation is the creation or movement of gas in an acoustic field. As the tissue compresses and expands with exposure to the acoustic waves, gas is extracted creating bubbles. These bubbles interact with the acoustic field and begin to oscillate violently. The bubbles collapse and create high-velocity jets that disrupt cell membranes.<sup>26</sup> Microstreaming refers to the rapid movement of liquid outside an oscillating bubble generated through cavitation forces.



**Fig. 1.** Delivery to target tissues after focusing by an acoustic lens, bowl-shaped transducer, or electronic phased array.

When the bubbles oscillate, nearby tissues are subjected to shearing forces that can also disrupt cell membranes.<sup>27</sup> Radiation forces are the pressures tissues endure when either absorbing or reflecting sound waves. Because tissues and solids respond differently from liquid media, movement of liquids can create streaming and shearing effects that disrupt cell membrane integrity.<sup>28</sup> Overall, the primary mechanism of cell death in HIFU therapy is coagulative necrosis, but the sum contribution of thermal and mechanical effects is ultimately responsible for ablation of target tissues.

It has been hypothesized that these mechanical effects might contribute to local spread of tumor cells, limiting the clinical efficacy of HIFU. Several studies have refuted this claim *in vitro* and *in vivo*.<sup>29,30</sup>

### **Other Effects**

The high temperatures also induce the creation and release of chemically reactive free radicals. These have direct and indirect activity on surviving cells, namely in the induction of apoptosis and activity on nuclear DNA. Nearby tissues are also believed to undergo apoptosis induced by the lower levels of acoustic radiation and heat experienced during HIFU treatment. Necrosis and cavitation take days to months to peak and are believed to correlate with PSA nadir.

### **Limitations**

Despite being a noninvasive modality in the treatment of prostate cancer, it is not without any untoward side effects. Because HIFU works best in contiguous tissues, its use is limited to localized prostate cancer; it is not meant to treat disseminated, widespread, or otherwise inoperable cancers. In addition, because ultrasound is the basis of HIFU, unwanted effects of diagnostic ultrasound imaging also apply to its higher-energy use: shadowing and refraction. Shadowing can result from large prostatic calcifications (>10 mm in diameter), which can interfere with the delivery of acoustic energy. This could potentially impact the ability to completely ablate larger glands greater than 40 mL, limiting clinical efficacy. Reflection of sound waves into nearby tissues outside the focal plane, although normally of no consequence in diagnostic imaging, could produce burns in tissues adjacent to the treatment zone (rectum, bowel, bladder).

### **Clinical Use of HIFU**

Much of the literature focuses on the use of HIFU in the setting of primary treatment of clinically localized prostate cancer (T1c–T2a). The minimally

invasive characteristics of HIFU also make it suitable as a salvage treatment option for patients with biochemical failure after other types of primary treatment, namely after radical prostatectomy or external-beam radiotherapy. HIFU does not preclude the use of other future treatment modalities; that is, prostatectomy<sup>31</sup> and radiotherapy<sup>32</sup> have been safely performed following HIFU treatment.

### **PATIENT SELECTION**

Criteria for individuals who qualify for HIFU have not been clearly defined. In general, they are individuals with localized disease and who do not want or do not qualify for surgical or radiation treatment. Several HIFU studies have included individuals more than 70 years-old and who were not candidates for prostatectomy or radiation or who did not desire these treatment options.<sup>7,33–35</sup>

The prostate size of individuals receiving HIFU treatment must be less than or equal to 40 mL<sup>7,34</sup>; however, the anterior-posterior diameter of the prostate should not exceed 45 mm using the Sonablate device and should be no longer than 25 mm with the Ablatherm instrument. Greater prostate volume is one of the primary contraindications for HIFU. Prostate volumes larger than 40 mL may lead to incomplete treatment of the gland. HIFU waves do not penetrate beyond 19 to 26 mm, which in larger prostates would make reaching the anterior and anterobasal regions of the prostate impossible. However, these regions of the prostate have low incidence of CaP and size may not be as important a factor; improved HIFU technology may overcome the size limitation.<sup>36</sup> Some studies have used transurethral resection of the prostate (TURP) or 5 $\alpha$ -reductase inhibitors to decrease the size of the prostate before HIFU treatment.

Other criteria for HIFU treatment include clinical stage and PSA level. Most studies include only individuals with clinical stage T1 to T2 or localized CaP.<sup>7,12,13,34,35,37,38</sup> The clinical stage is independent of the Gleason score. The criteria for PSA level of candidates enrolled in multiple studies are variable. Study criteria for PSA include PSA level less than 10 ng/mL, PSA level less than 15 ng/mL,<sup>12,13</sup> PSA level less than 20 ng/mL. Several studies have set a PSA level of less than 15 ng/mL as their PSA criteria, however, there are no clear data on an absolute maximum PSA level.<sup>7</sup> Several clinical trials in the United States have set a PSA level less than 10ng/mL and Gleason score of less than or equal to 6.

Other relative contraindications for HIFU treatment include high volume of intraprostatic calcifications,

as mentioned previously. These calcifications can lead to scattering of the ultrasound waves, which may decrease the safety and efficacy of the treatment. Anatomic or pathologic conditions of the rectum that may interfere with the placement of the HIFU probe into the rectum are contraindications for HIFU therapy.

**TREATMENT OUTCOMES**  
**Studies**

Initial studies of HIFU in the treatment of localized CaP are nearing completion in the United States, and several international trials with longer-term outcomes have been published showing positive clinical outcomes with low morbidity. Most studies reveal that PSA nadirs are reached within 3 to 4 months.<sup>7</sup> In a systematic review of the French literature on primary HIFU using the Ablatherm device, negative biopsy rates after 3 months ranged from 80% to 90% in most studies (51%–96% in all studies). Negative biopsy rates for the Sonablate device ranged from 64% to 87% (Fig. 2). Long-term disease-free rates with HIFU for the 2 devices are shown in Fig. 3. PSA nadirs of 0.5 ng/mL or less were achieved in 42% to 84% of patients treated with the Ablatherm device. A study in the United Kingdom found that PSA nadirs of 0.2 ng/mL or less and 0.5 ng/mL or less were achieved in 80% and 60%, respectively, for the Sonablate device. The data are similar to several trials demonstrating biochemical or pathologic disease-free rates after 5 years, ranging from 66% to 78%.<sup>37</sup>

Follow-up data on the Ablatherm device are more extensive than the Sonablate device. In a series by Blana and colleagues<sup>39</sup> with the longest follow-up to date (mean 6.4 years), the

actuarial disease-free survival was 59% after 6 years. Eight-year cancer-specific and overall survival were 98% and 83%, respectively. Even with longer follow-up time, the authors cannot state whether HIFU improves survival over active surveillance; longer follow-up periods are needed.

**Important Markers**

Pretreatment PSA level has been shown to correlate with biochemical disease-free survival (BDFS).<sup>38,40,41</sup> More recently, more focus has been brought to the intuitive relationship between PSA nadir and clinical outcomes, specifically BDFS and negative biopsy rate. Ganzer and colleagues<sup>42</sup> demonstrated that a PSA nadir of 0.2 ng/mL or less is associated with improved disease-free survival, based on analysis of data for 103 men who underwent HIFU as primary treatment of localized CaP.

**Lack of Appropriate HIFU-Specific Biochemical Failure Definition**

Unfortunately, no standard definition of BDFS exists specific to primary treatment of clinically localized CaP with HIFU, a point of often contentious debate. In addition, among the various studies reporting long-term results, there is no consensus on which definition is the most appropriate and valid. Many studies cite the definitions used for primary radiation treatment, that is, the American Society for Therapeutic Radiology and Oncology (ASTRO) definitions. The original definition (3 consecutive increases in PSA after reaching nadir) is cited in studies from the late 1990s and early 2000s. Unfortunately, this definition is flawed on the premise that it precludes early biochemical

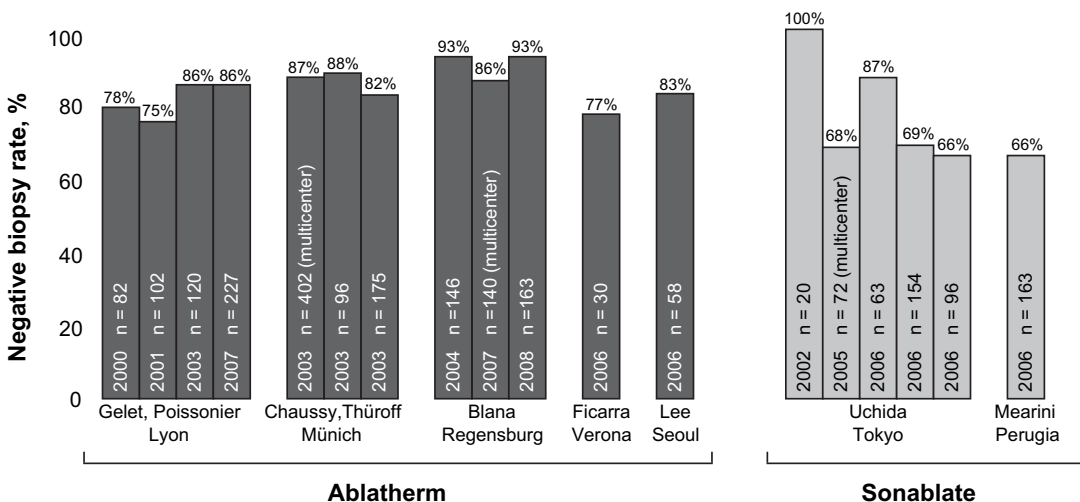
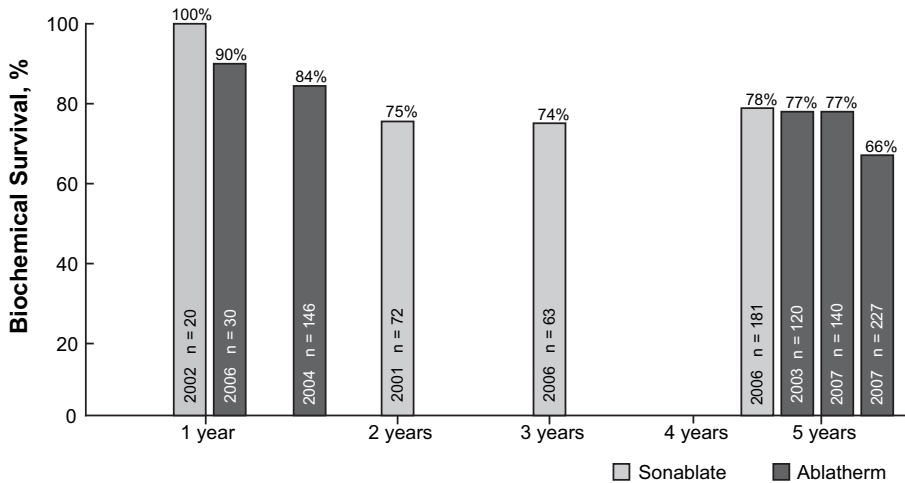


Fig. 2. Negative biopsy rates with HIFU for the Ablatherm and Sonablate devices.



**Fig. 3.** Long-term disease-free rates with HIFU for the Ablatherm and Sonablate devices.

reoccurrence. More recent studies have cited the ASTRO Phoenix criteria for BDFS: PSA nadir + 2 ng/mL constitutes biochemical failure.<sup>43</sup> Other end points cited in HIFU studies include PSA nadir, negative biopsy rates after a specific interval after treatment, and changes from baseline in International Prostate Symptom Score (IPSS) scores. The relationship between BDFS and overall survival, however, remains elusive. It is hoped that more long-term study results will resolve this unanswered question.

### FOLLOW-UP

Follow-up after primary or salvage HIFU therapy is not well defined outside the research protocols used by clinical studies. Most studies use a combination of serum PSA checked every 3 to 4 months for the first 2 years after treatment and transrectal ultrasound-guided prostate biopsies at specific intervals (usually 1 or 2 years after treatment). Whether these strict protocols are necessary or applicable to the clinical use and practice of HIFU treatment has not been analyzed. Until the efficacy of HIFU is better resolved, generalization of the follow-up schemes used in the studies in the literature to standard practice remains undetermined.

### COMPLICATIONS

The most common complications after HIFU as primary therapy are urinary incontinence, bladder outlet obstruction, urethral strictures, and erectile dysfunction. Many studies also report (low) rates of rectourethral fistulas (as low as <1% in primary HIFU and <3% in salvage HIFU). Urinary incontinence has been observed in 8% to 25% of patients

undergoing primary treatment by HIFU without preoperative TURP, and 6% to 13% of patients who underwent primary HIFU with TURP.<sup>7</sup> Rates of urinary stricture also favor primary HIFU with TURP as only 8% of patients developed stricture when TURP was performed beforehand as opposed to 30% in patients who underwent HIFU without TURP. Although TURP has no bearing on disease control (as measured by PSA nadir, negative biopsy rate, or biochemical failure), it is indicated to reduce rates of incontinence, stricture, and bladder outlet obstruction.<sup>12</sup> The rate of impotence varies from 20% to 77% of patients treated with HIFU, depending on patient selection and device used, with several Italian and French studies showing moderate erectile dysfunction after treatment.<sup>40,44</sup>

### SUMMARY

#### *Current Recommendations*

HIFU fills a niche role in the treatment of CaP for a select group of patients who are either unsuitable for more invasive interventions (prostatectomy, radiotherapy), or unwilling to enter into active surveillance. HIFU is also an alternative treatment for men who do not want to undergo radical prostatectomy or radiation therapy. In some patients with low-risk disease, HIFU is an option in the armamentarium of urologists in the treatment of prostate cancer. HIFU also may play a role as a salvage therapy in men who fail other localized primary treatments. As HIFU has not been approved by the FDA in the United States, clinical trials showing promising long-term clinical outcomes are currently underway.

## Ongoing Studies

In a multicenter, nonrandomized phase III study for clinically localized CaP (T1c–T2a) in the United States, HIFU (Sonablate 500) is being compared with brachytherapy with target enrollment of 466 men between the ages of 45 and 75 years, Gleason score less than or equal to 6, and PSA less than or equal to 10 ng/mL. Absence of biochemical recurrence, defined by the ASTRO Phoenix criteria in addition to negative biopsy at 24 months, is the primary end point.

A phase III, multicenter, single-arm study investigating the safety and efficacy of salvage HIFU (Sonablate) for recurrent localized prostate cancer after external-beam radiation failure is currently underway. Target enrollment is 212 men between the ages of 40 and 85 years, with a PSA level between 0.5 ng/mL and 10 ng/mL, who received electron beam radiation therapy 2 or more years prior, and have biopsy-confirmed prostate cancer.

Another nonrandomized phase II/III trial will compare primary HIFU (Ablatherm) to cryoablation. Target enrollment is 446 men aged 60 years or more with Gleason score of 6 or less, and PSA level 10 ng/mL or less, and T2a or lower grade disease. The primary outcome is PSA nadir less than 0.5 ng/mL, stable PSA, and negative biopsy at 24 months. These end points are far more stringent than many previous trial definitions of biochemical and pathologic disease-free states. Secondary end points will include PSA nadir less than 0.5 ng/mL at 6 months, disease-specific and overall survival, change from baseline UCLA Prostate Cancer Index and IPSS.

## Future

Imaging techniques continue to improve in the setting of HIFU treatment. Doppler or blood-flow ultrasound guidance and magnetic resonance-guided HIFU are currently under investigation in the treatment of hepatic masses and uterine fibroids, and may improve precision of treatment. In addition to technical improvements, longer-term clinical trials with standard measures of clinical efficacy are needed to bring HIFU into the fold of accepted treatments for men with localized prostate cancer.

## Overview

- HIFU is an investigational treatment modality for prostate cancer in the United States. Several phase III trials are ongoing.
- HIFU technology is well understood in its effect on tissues, the resulting coagulative

necrosis, and mechanical disruption of cell membranes.

- HIFU is generally well tolerated, and the most common side effect is acute urinary retention.
- The guidelines for PSA and transrectal ultrasound-guided biopsy of the prostate after treatment are not well elucidated outside clinical trials. Interpretation of PSA after HIFU treatment is still not well understood.
- HIFU therapy for low-risk clinically localized prostate cancer seems increasingly attractive for men who turn down the option of active surveillance but who are also poor surgical candidates.

## REFERENCES

1. Jemal A, Siegel R, Ward E, et al. Cancer statistics 2007. *CA Cancer J Clin* 2007;57:43–66.
2. Scattoni V, Zlotta A, Montironi R, et al. Extended and saturation prostatic biopsy in the diagnosis and characterization of prostate cancer: a critical analysis of the literature. *Eur Urol* 2007;52:1309–22.
3. Crawford ED, Barqawi A. Targeted focal therapy: a minimally invasive ablation technique for early prostate cancer. *Oncology* 2007;21:27–32.
4. Etzioni R, Penson DF, Legler JM, et al. Overdiagnosis due to prostate-specific antigen screening: lessons from U.S. prostate cancer incidence trends. *J Natl Cancer Inst* 2002;94:981–90.
5. Hou A, Sullivan K, Crawford ED. Targeted focal therapy for prostate cancer: a review. *Curr Opin Urol* 2009;19:283–9.
6. Gelet A, Chapelon JY, Bouvier R, et al. Local control of prostate cancer by transrectal HIFU therapy: preliminary results. *J Urol* 1999;161:156–62.
7. Rebillard X, Soulie M, Chartier-Kastler E, et al. High-intensity focused ultrasound in prostate cancer: a systematic literature review of the French Association of Urology. *BJU Int* 2008;101:1205–13.
8. Challacombe BJ, Murphy DG, Zakri R, et al. High-intensity focused ultrasound for localized prostate cancer: initial experience with a 2-year follow up. *BJU Int* 2009;104:200–4.
9. Association of Italian Urologists. Guidelines on prostate cancer: diagnosis, staging and therapy. *Pietra Ligure (Italy): Association of Italian Urologists*; 2008. Available at: <http://www.auro.it/wp-content/uploads/al10.pdf>.
10. Heidenreich A, Aus G, Bolla M, et al. EAU guidelines on prostate cancer. *Eur Urol* 2008;53:68–80.
11. Warwick R, Pond J. Trackless lesions in nervous tissues produced by high intensity focused ultrasound (high-frequency mechanical waves). *J Anat* 1968;102:387–405.

12. Chaussy C, Thuroff S. The status of high-intensity focused ultrasound in the treatment of localized prostate cancer and the impact of a combined resection. *Curr Urol Rep* 2003;4:248–52.
13. Blana A, Walter B, Roggenhofer S, et al. High-intensity focused ultrasound for the treatment of localized prostate cancer: 5-year experience. *Urology* 2004; 63:297–300.
14. Tanter M, Pernot M, Aubry FJ, et al. Compensating for bone interfaces and respiratory motion in high-intensity focused ultrasound. *Int J Hyperthermia* 2007;23:141–51.
15. Watkin NA, ter Haar GR, Rivens I. The intensity dependence of the site of maximal energy deposition in focused ultrasound surgery. *Ultrasound Med Biol* 1996;22:483–91.
16. Chen L, ter Haar GR, Hill CR, et al. Effect of blood perfusion on the ablation of liver parenchyma with high-intensity focused ultrasound. *Phys Med Biol* 1994;38:1661–73.
17. Illing RO, Leslie TA, Kennedy JE, et al. Visually directed HIFU for organ confined prostate cancer—a proposed standard for the conduct of therapy. *BJU Int* 2006;98:1187–92.
18. Lindstrom PA. Prefrontal ultrasonic irradiation: a substitute for lobotomy. *AMA Arch Neurol Psychiatry* 1954;72:399–425.
19. Ballentine HT Jr, Bell E, Manlapaz J. Progress and problems in the neurological applications of focused ultrasound. *J Neurosurg* 1960;17:858–76.
20. Fry W, Barnard K, Fry F, et al. Ultrasonic lesions in the mammalian central nervous system with ultrasound. *Science* 1955;122:517–8.
21. Chassy C, Brendel W, Schmiedt E. Extracorporeally induced destruction of kidney stones by shock waves. *Lancet* 1980;2:1265–8.
22. Gelet A, Chapelon JY, Margonari J, et al. Prostatic tissue destruction by high-intensity focused ultrasound: experimentation on canine prostate. *J Endourol* 1993;7:249–53.
23. Bihle R, Foster RS, Sanghvi NT, et al. High-intensity focused ultrasound in the treatment of prostatic tissue. *Urology* 1994;43:21–6.
24. Kincaide LF, Sanghvi NT, Cummings O, et al. Noninvasive ultrasonic subtotal ablation of the prostate in dogs. *Am J Vet Res* 1995;57:1225–7.
25. Dewhirst MW, Viglianti BL, Lora-Michiels M, et al. Basic principles of thermal dosimetry and thermal thresholds for tissue damage from hyperthermia. *Int J Hyperthermia* 2003;19:267–94.
26. Coussios CC, Fanny CH, Haar GT, et al. Role of acoustic cavitation in the delivery and monitoring of cancer treatment by high-intensity focused ultrasound (HIFU). *Int J Hyperthermia* 2007;23: 105–20.
27. Holland CK, Apfel RE. Thresholds for transient cavitation produced by pulsed ultrasound in a controlled nuclei environment. *J Acoust Soc Am* 1990;88: 2059–69.
28. Vaezy S, Shi X, Martin R, et al. Real-time visualization of high intensity focused ultrasound treatment using ultrasound imaging. *Ultrasound Med Biol* 2001;27:33–42.
29. Kennedy JE, ter Haar GR, Wu F, et al. Contrast-enhanced ultrasound assessment of tissue response to high-intensity focused ultrasound. *Ultrasound Med Biol* 2004;30:851–4.
30. Kennedy JE. High-intensity focused ultrasound in the treatment of solid tumours. *Nature Rev* 2005; 10:1039.
31. Liatsikos E, Bynens B, Rabenalt R, et al. Treatment of patients after failed high intensity focused ultrasound and radiotherapy for localized prostate cancer: salvage laparoscopic extraperitoneal radical prostatectomy. *J Endourol* 2008;22:2295–8.
32. Pasticier G, Chapet O, Badet L, et al. Salvage radiotherapy after high-intensity focused ultrasound for localized prostate cancer: early clinical results. *Urology* 2008;72:1305–9.
33. Archer PL, Hodgson KJ, Murphy DG, et al. High-intensity focused ultrasound for treating prostate cancer. *BJU Int* 2006;99:28–32.
34. Murat FJ, Poissonnier L, Pasticier G, et al. High-intensity focused ultrasound for prostate cancer. *Cancer Control* 2007;14:244–9.
35. Tsakiris P, Thuroff S, Rosette J, et al. Transrectal high-intensity focused ultrasound devices: a critical appraisal of the available evidence. *J Endourol* 2008;22:221–9.
36. Barqawi A, Crawford ED. Emerging role of HIFU as a noninvasive ablative method to treat localized prostate cancer. *Oncology* 2008;22:123.
37. Uchida T, Ohkusa H, Yamashita H, et al. Five years experience of transrectal high-intensity focused ultrasound using the Sonablate device in the treatment of localized prostate cancer. *Int J Urol* 2006; 13:228–33.
38. Lee HM, Hong JH, Choi HY. High-intensity focused ultrasound therapy for clinically localized prostate cancer. *Prostate Cancer Prostatic Dis* 2006;9: 439–43.
39. Blana A, Thuroff S, Murat FJ, et al. First analysis of the long-term results with transrectal HIFU in patients with localised prostate cancer. *Eur Urol* 2008;53:1194–203.
40. Poissonnier L, Chapelon JY, Rouvière O, et al. Control of prostate cancer by transrectal IFU in 227 patients. *Eur Urol* 2007;51:381–7.
41. Gelet A, Chapelon JY, Murat FJ, et al. Prostate cancer control with transrectal HIFU in 124 patients: 7-years' actuarial results. *Eur Urol Suppl* 2005;5:133.
42. Ganzer R, Roggenhofer S, Walter B, et al. PSA nadir is a significant predictor of treatment failure after



- high-intensity focused ultrasound (HIFU) treatment of localised prostate cancer. *Eur Urol* 2008;53: 547–53.
43. Roach M III, Hanks G, Thames H Jr, et al. Defining biochemical failure following radiotherapy with or without hormonal therapy in men with clinically localized prostate cancer: recommendations of the RTOG-ASTRO Phoenix Consensus Conference. *Int J Radiat Oncol Biol Phys* 2006;65:965–74.
44. Mearini L, D'Urso L, Collura D, et al. Visually directed transrectal high intensity focused ultrasound for the treatment of prostate cancer: a preliminary report on the Italian experience. *J Urol* 2009;181:105–11 [discussion: 111–2].