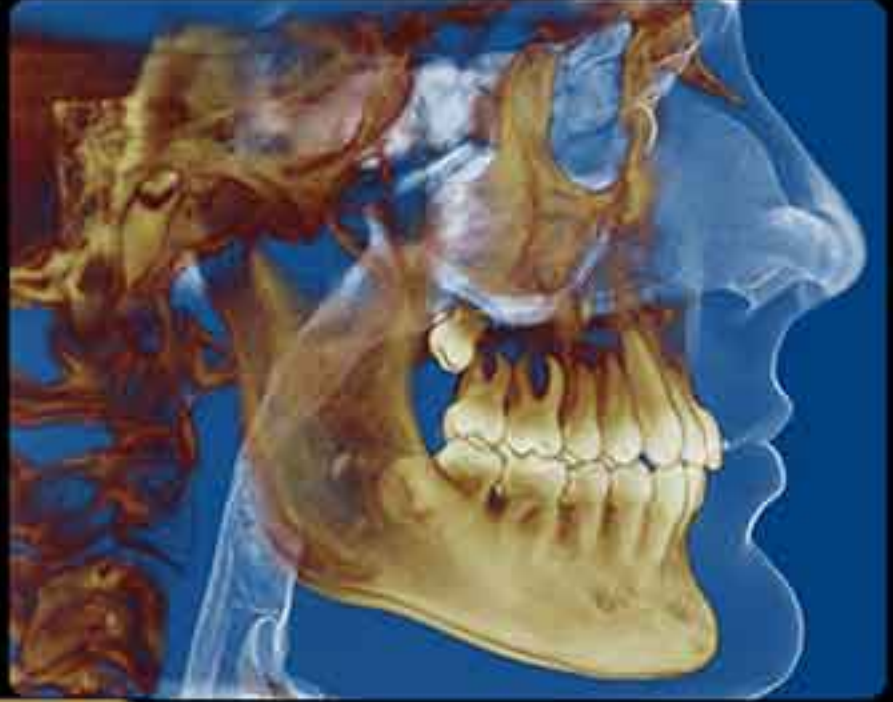
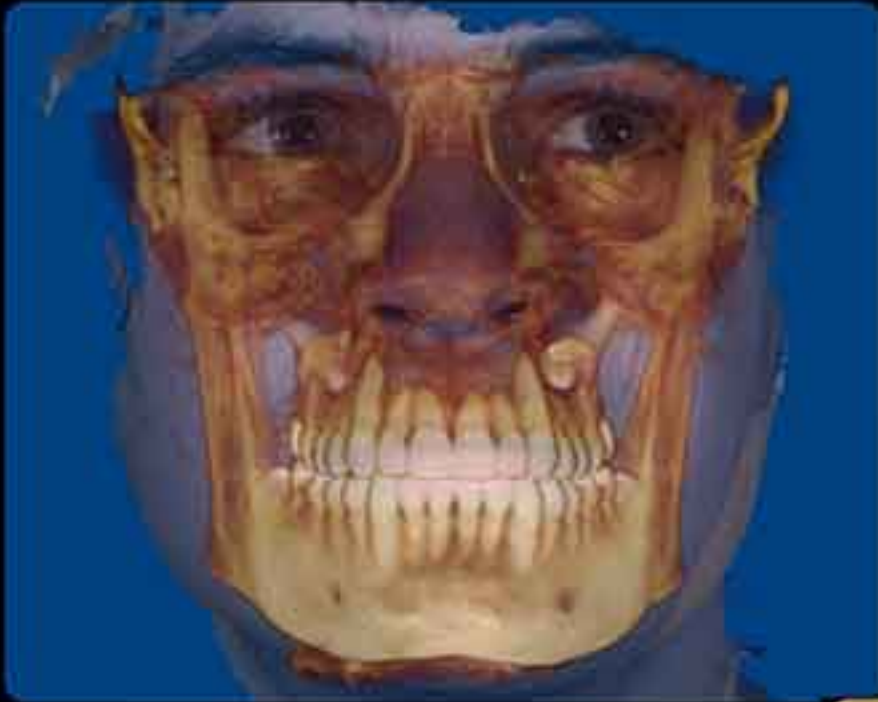
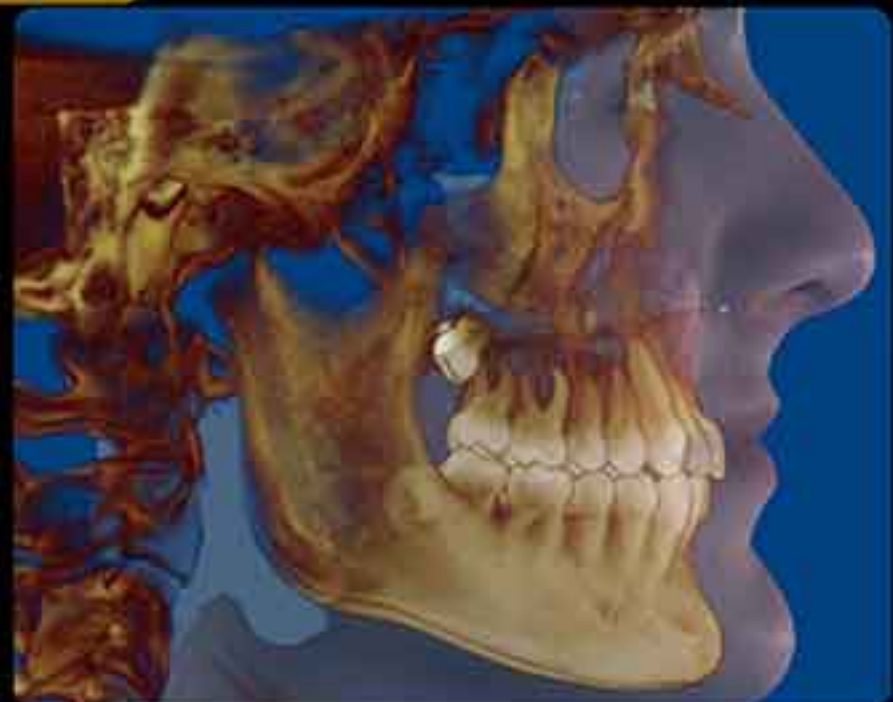
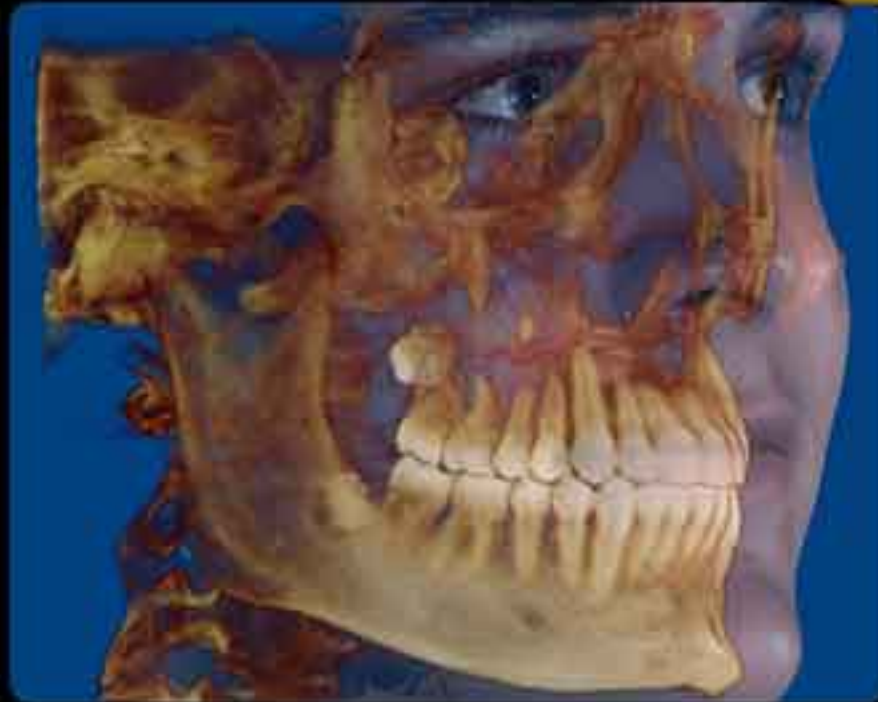
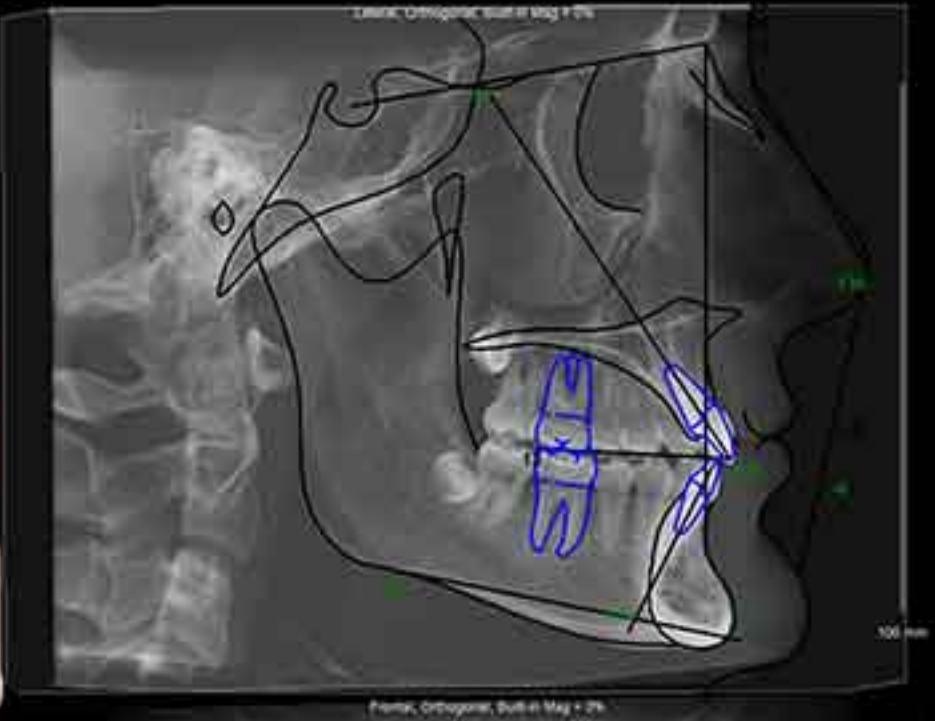
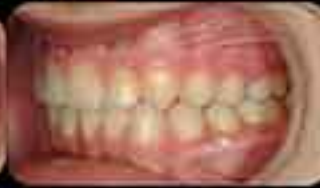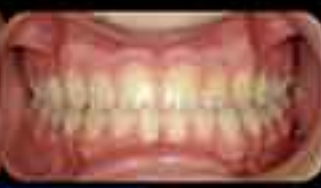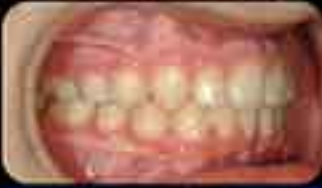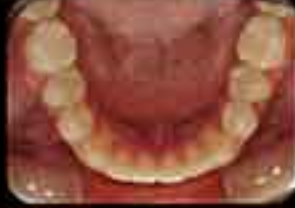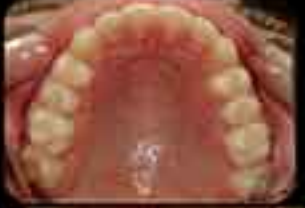Logo

Name: _____ Age: 15 y 8 m
Date: 6/12/2007 Sex: Male ID: 2-33037
Ref by: _____

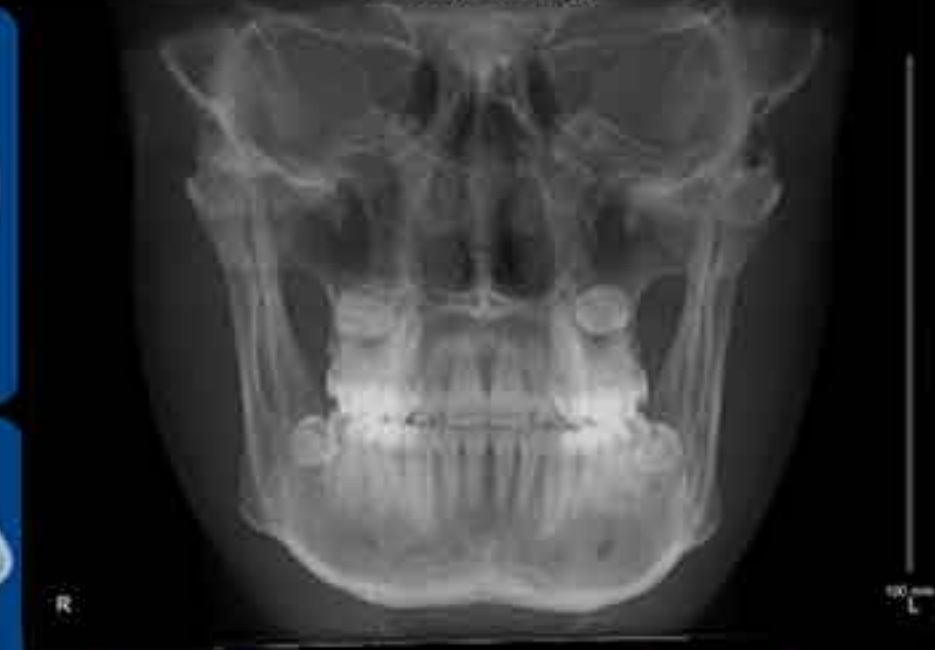
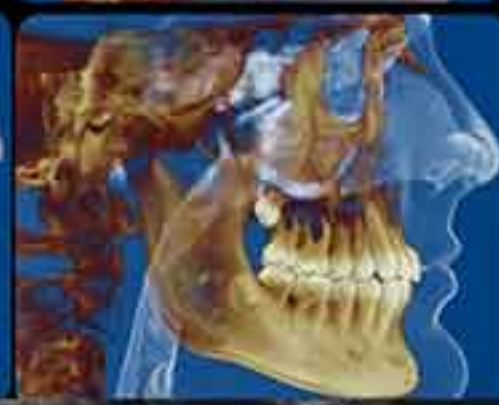
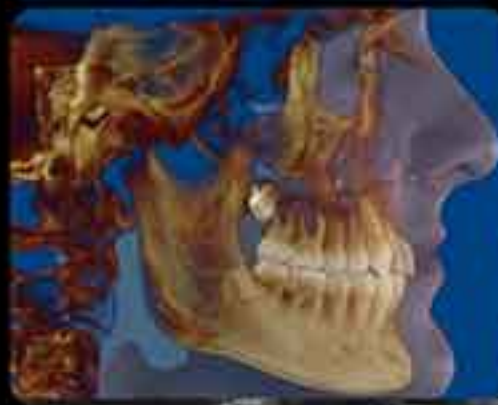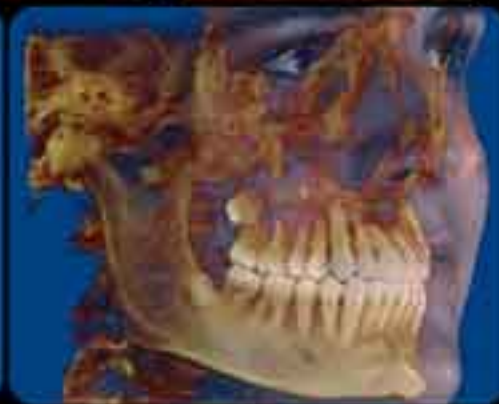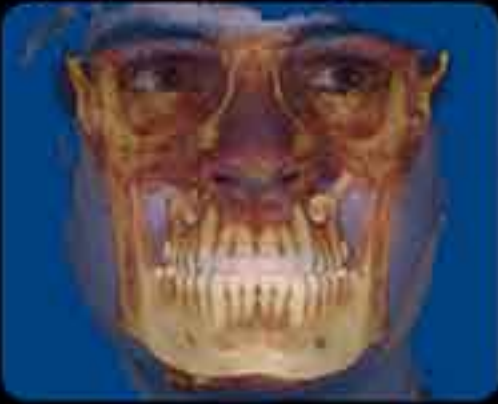Age: 15 y 8 m

6/12/2007

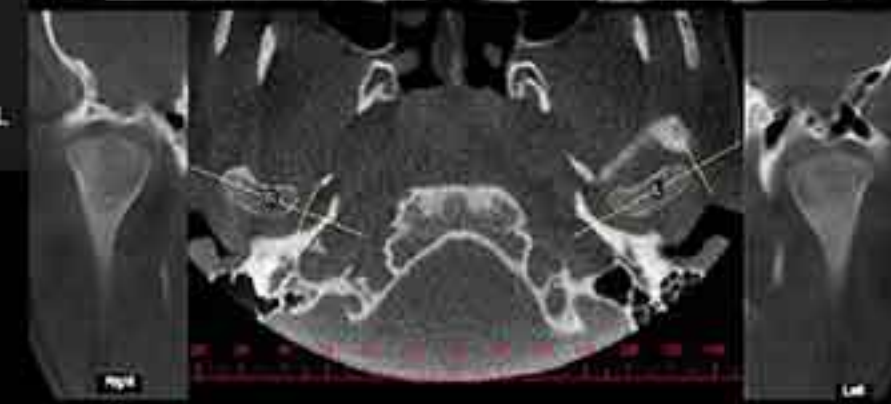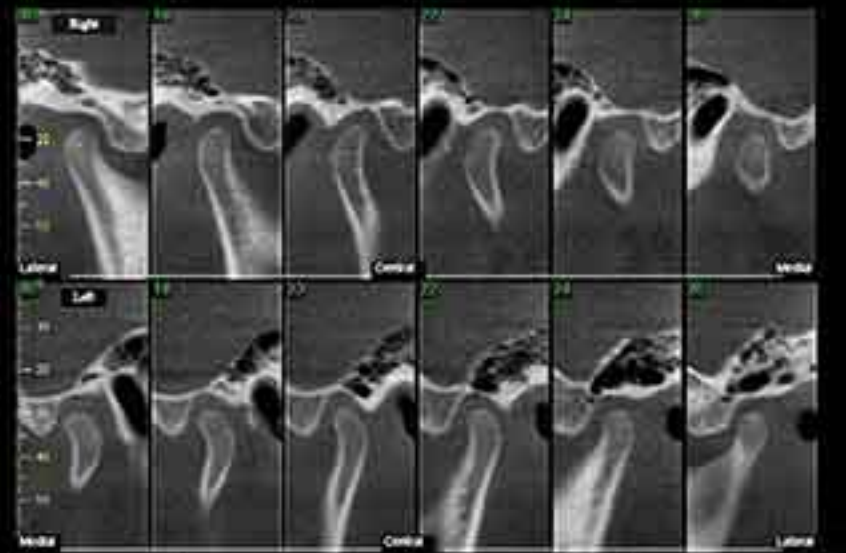

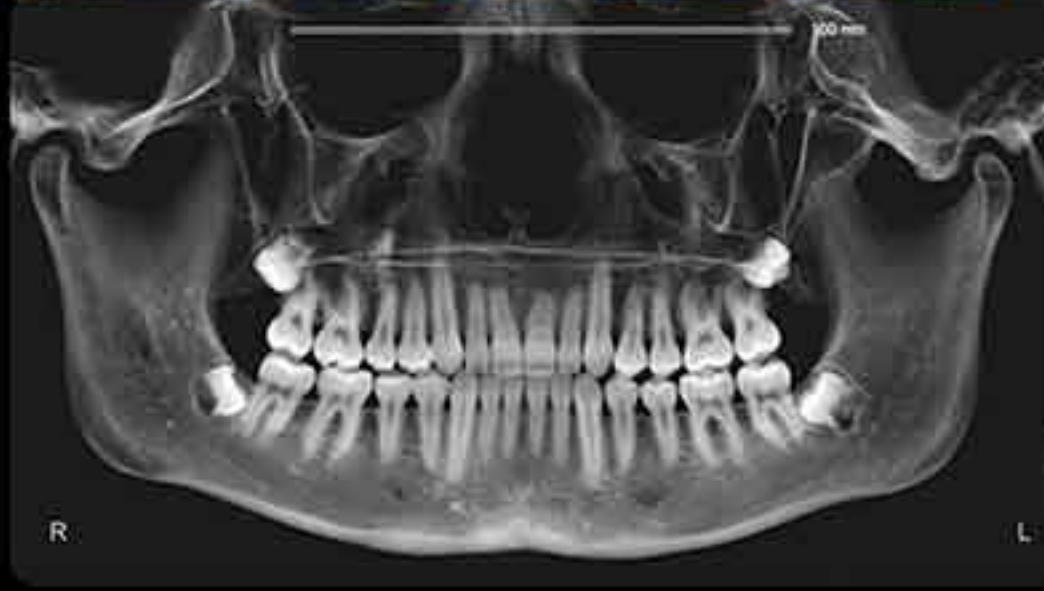
Frontal, Orthodontic, Built-in May + 2%



R

L





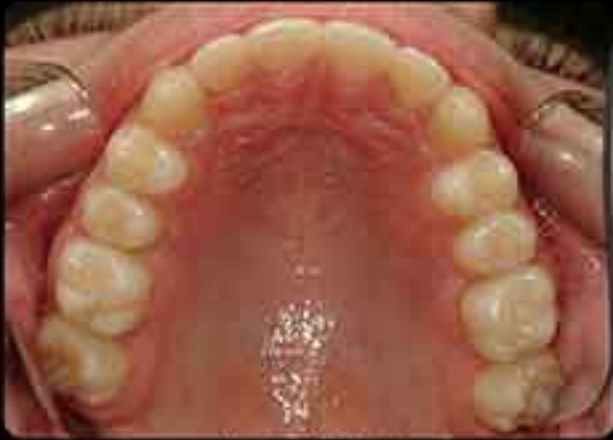Lateral Portrait



Frontal Portrait



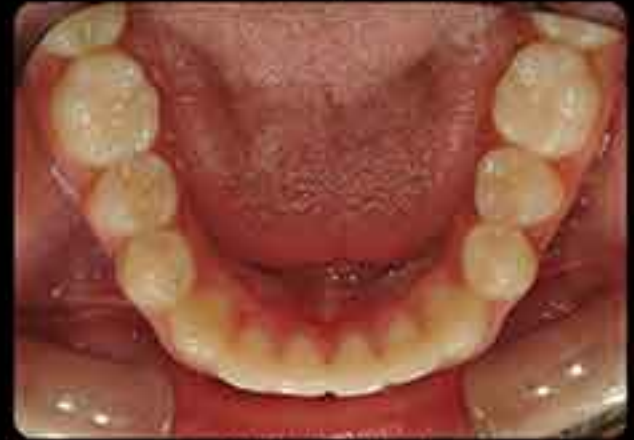Frontal Portrait (Smile)



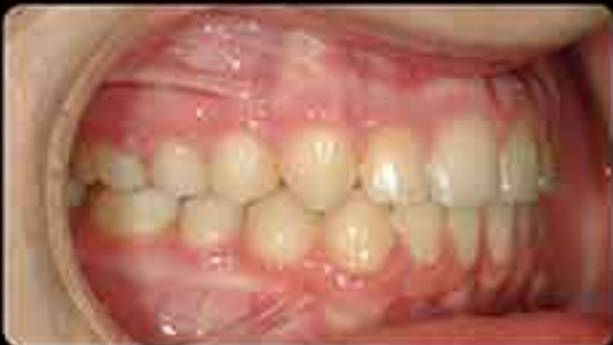Maxillary Occlusal

Logo

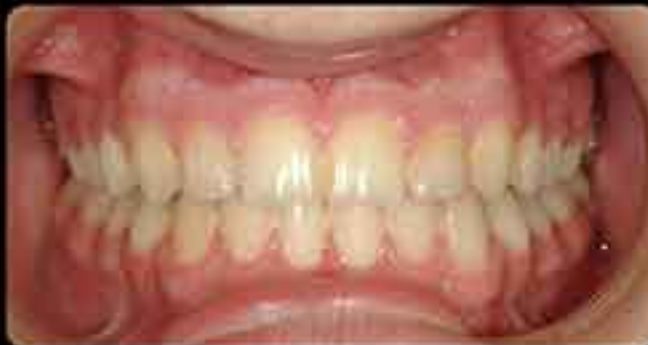Name: _____	Sex: <u>Male</u>
Date: <u>6/12/2007</u>	Age: <u>15 y 8 m</u> ID: <u>2-33037</u>
Ref by: _____	



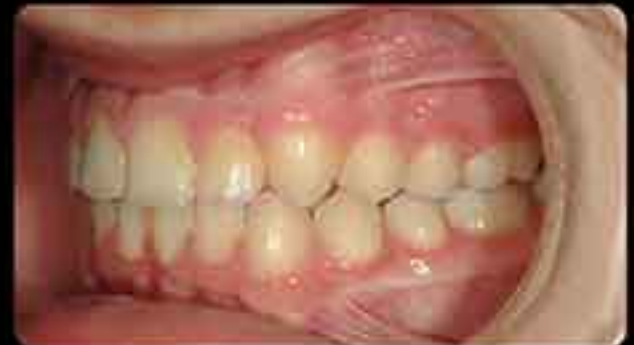Mandibular Occlusal



Right Buccal



Frontal

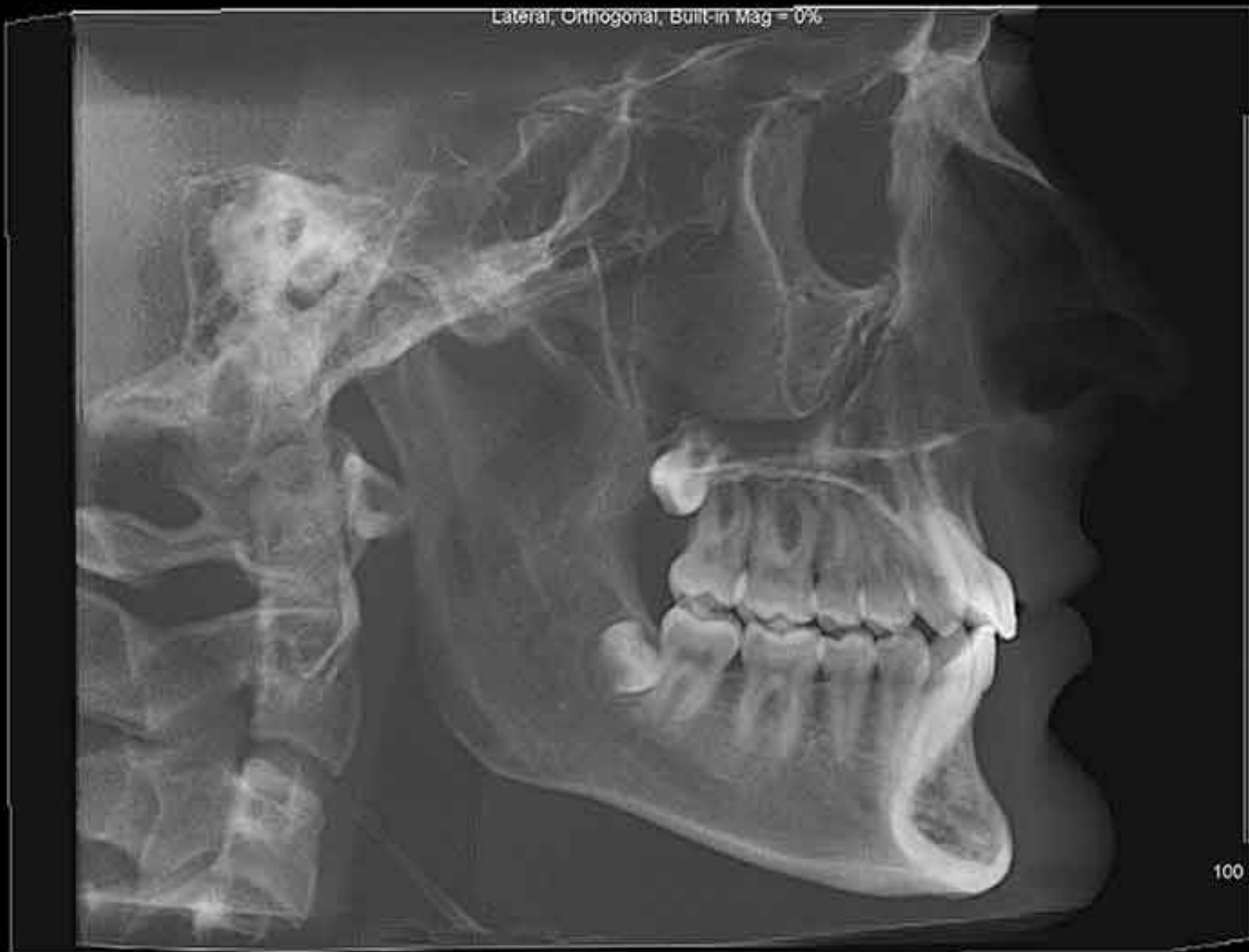

Left Buccal

Logo

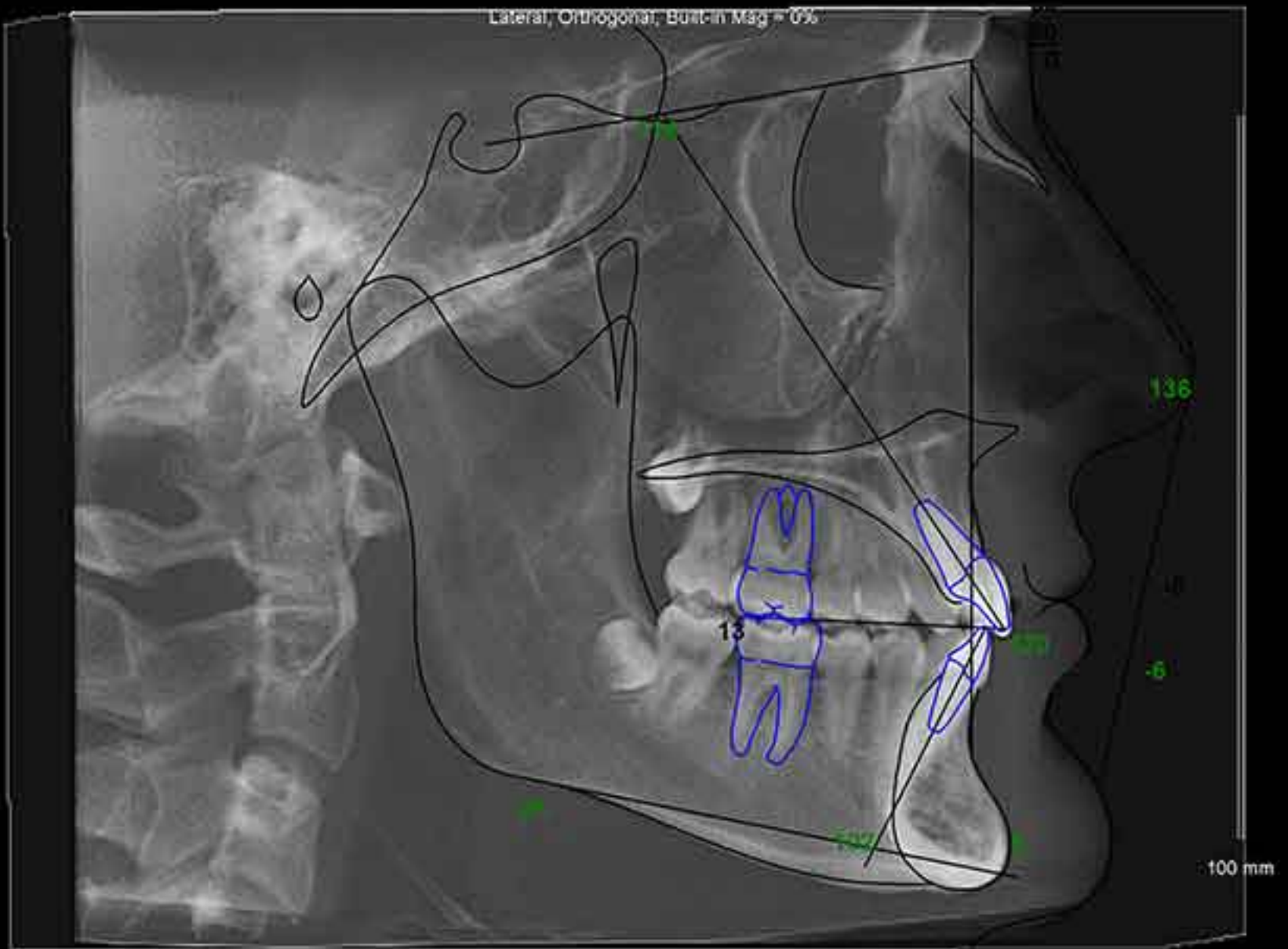
Patient: Sex: Male
Date: 6/12/2007 DOB: 15 ID: 2-33037
Referred by:

Lateral, Orthogonal, Built-in Mag = 0%



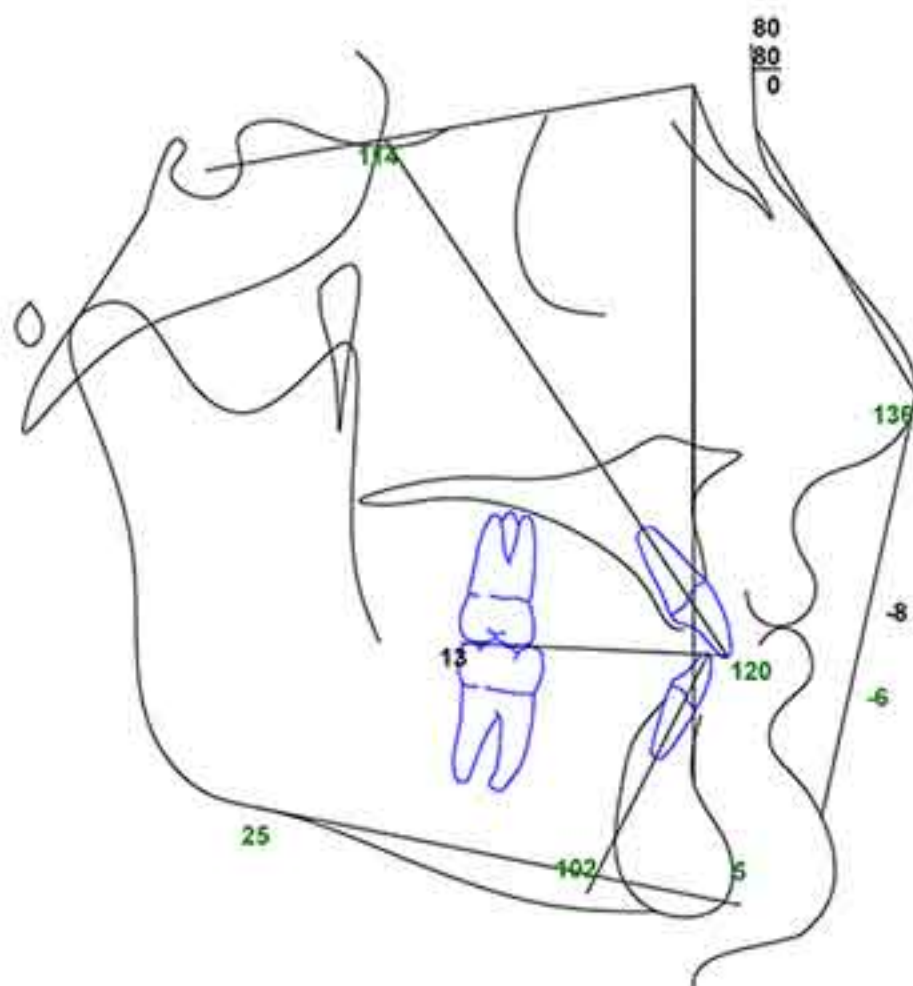
100 mm

Lateral Ceph, Final 6/12/2007,



Patient: ID 2-33037, Male, Age: 15y 8m (Birth: 9/25/1991)
 9/12/2007 Final Analysis: Steiner Norm: Other

	Value	Norm	Std Dev	Dev Norm
Interincisal Angle (U1-L1) (°)	119.7	120.0	2.0	-1.7 *
IMPA (I1-MP) (°)	102.1	95.0	7.0	1.0 *
ANB (°)	-0.2	1.6	1.5	-1.2 *
Lower Lip to E-Plane (mm)	-5.7	-2.0	2.0	-1.9 *
Upper Lip to E-Plane (mm)	-7.8	-6.5	2.0	-0.7
MP - SN (°)	24.4	33.0	6.0	-1.8 *
SNA (°)	80.0	82.0	3.5	-0.6
SNB (°)	80.1	80.9	3.4	-0.2
U1 - SN (°)	113.6	102.0	5.5	2.8 **
Occ Plane to SN (°)	12.6	14.4	2.5	-0.7
L1 - NB (mm)	2.0	4.0	1.8	-1.1 *
U1 - NA (mm)	4.9	4.3	2.7	0.2
U1 (labial surface) to NA (mm)	5.8	4.3	2.7	0.6
U1 - RA (°)	33.4	22.8	5.7	1.9 *
L1 - NB (°)	26.8	25.3	6.0	0.3
Prog - NB (mm)	0.0	2.5	1.7	-1.3 *
Soft Tissue Convexity (°)	130.2	131.9	4.0	-1.1 *
SN - GoGn (°)	21.2	32.0	5.0	-2.2 **

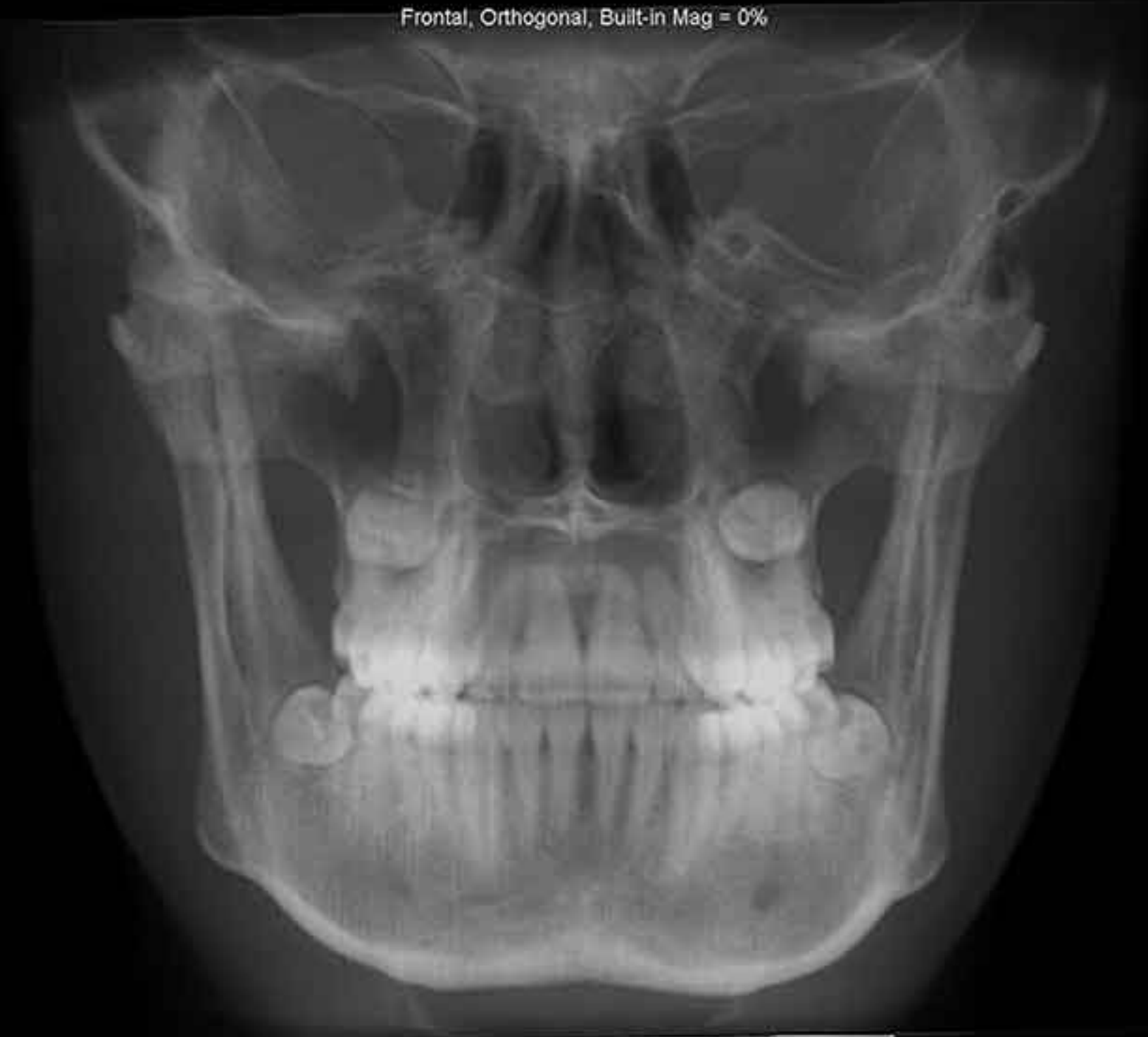

Company + Address

Logo

Patient: Sex: Male
Date: 6/12/2007 DOB: 15 ID: 2-33037
Referred by:

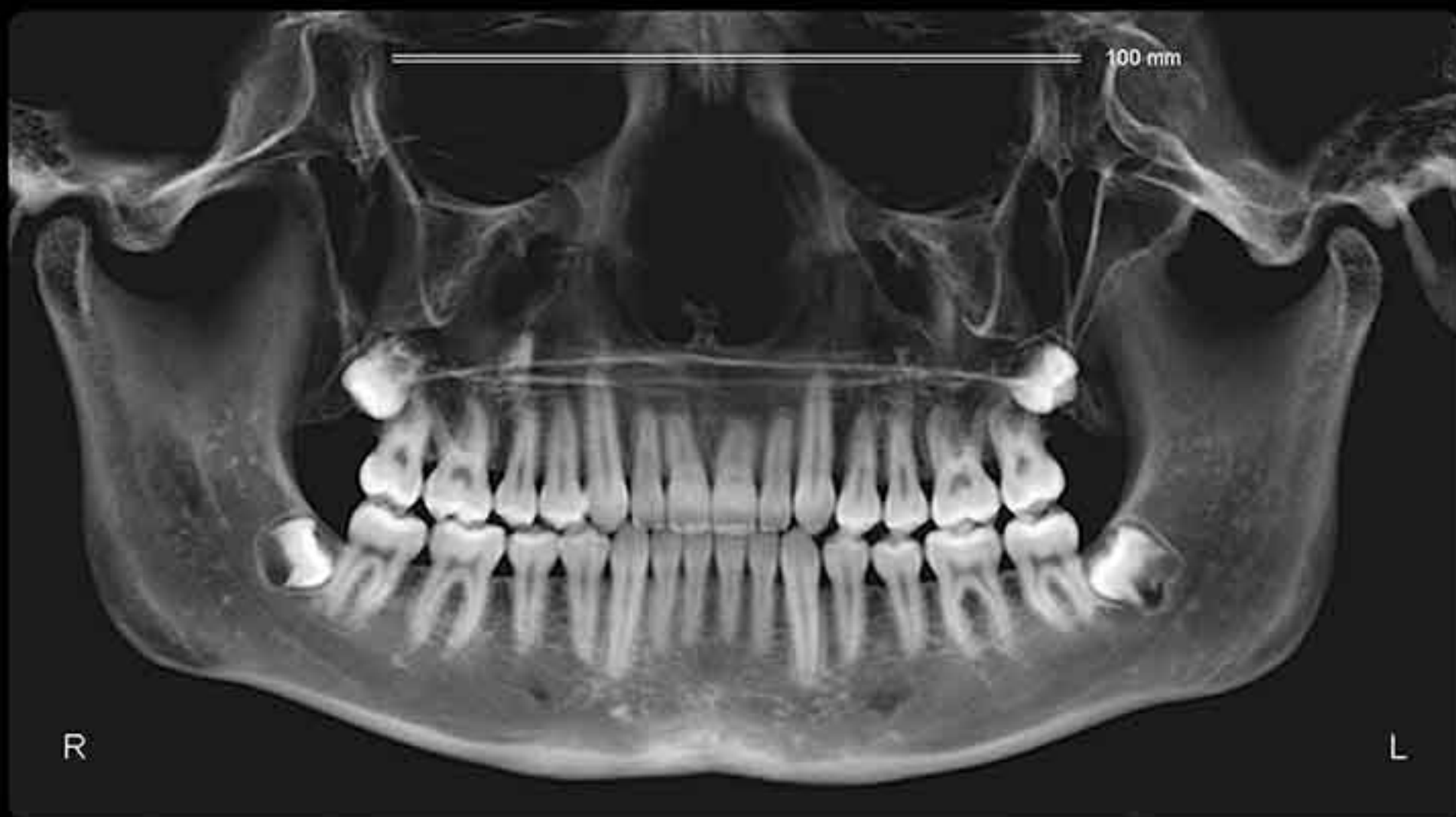Frontal, Orthogonal, Built-in Mag = 0%



R

100 mm
L

Logo

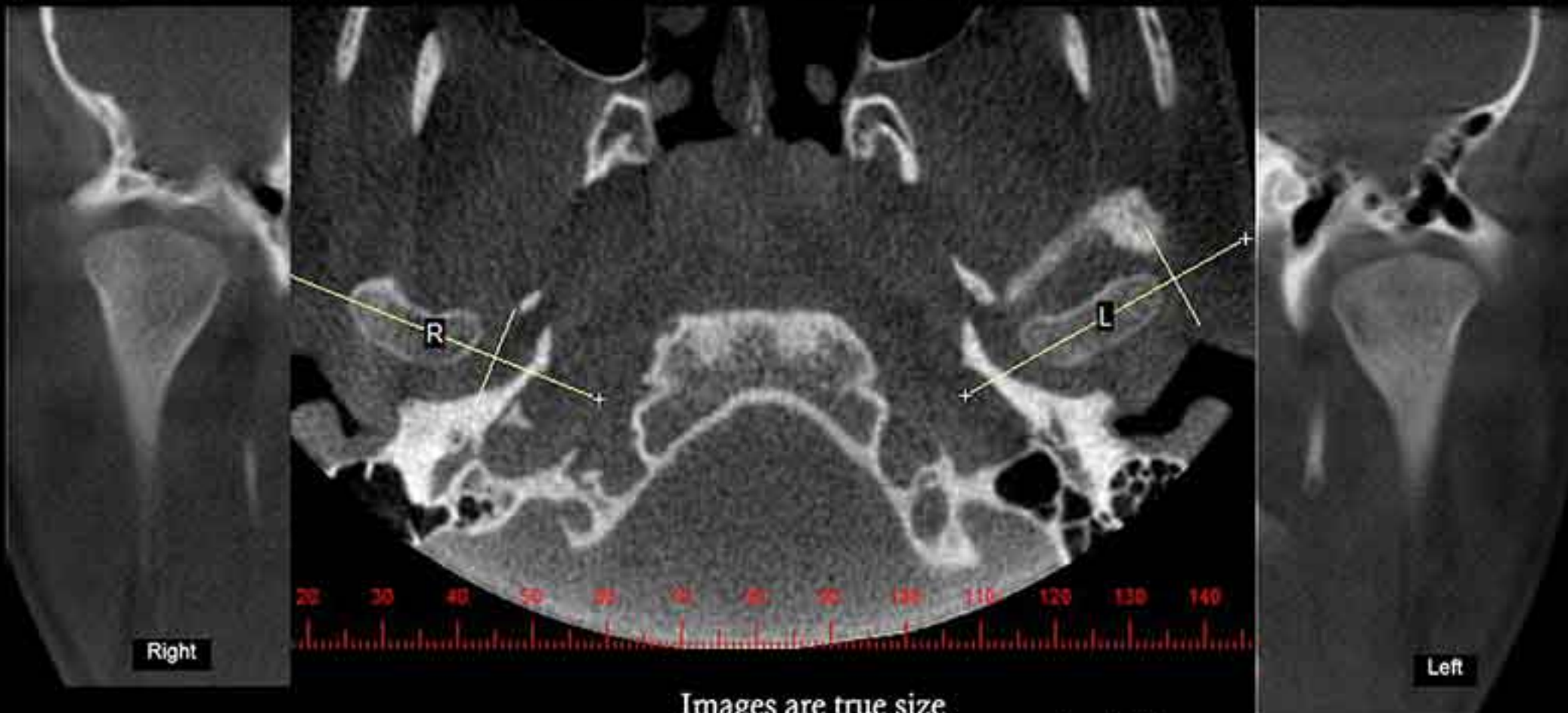
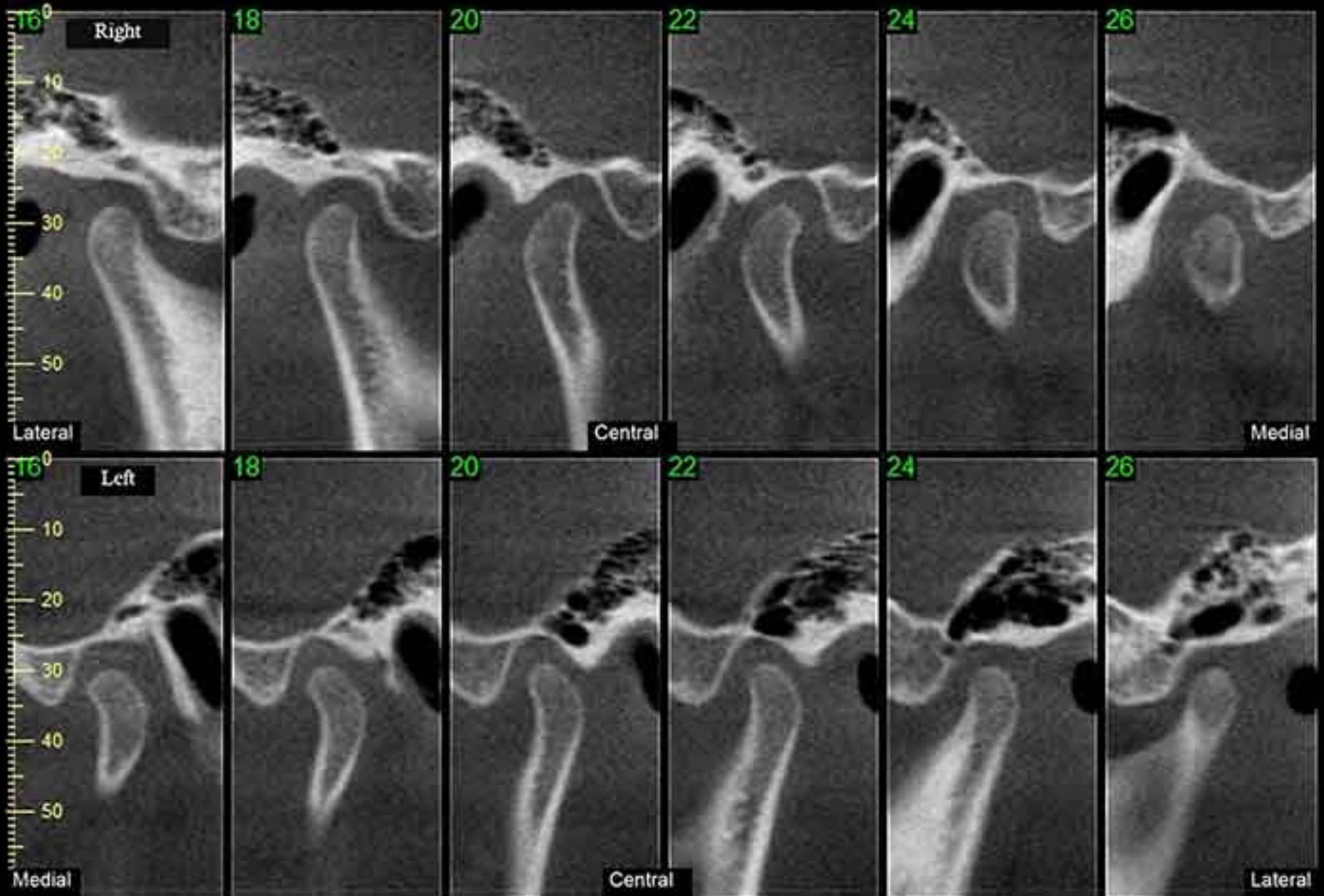


Name: _____ Sex: Male
Date: 6/12/2007 Age: 15 y 8 m ID: 2-33037
Ref by: _____

Image was reconstructed from Cone Beam Volume Scanner

Logo

Patient:
DOB: 09/25/1991 Study Date: 06/12/2007
Referred by:



Images are true size

Cross Section Final 6/12/2007,

