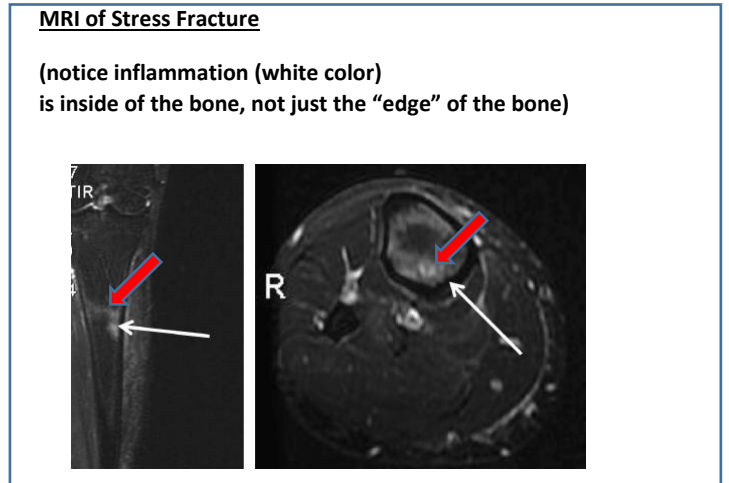
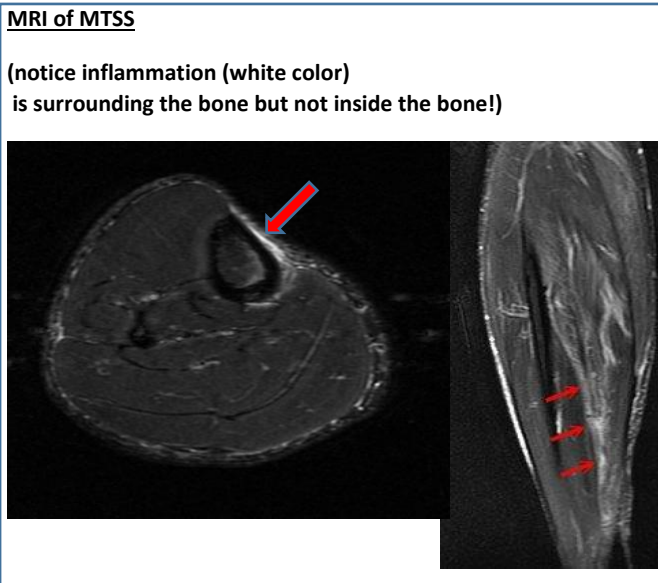
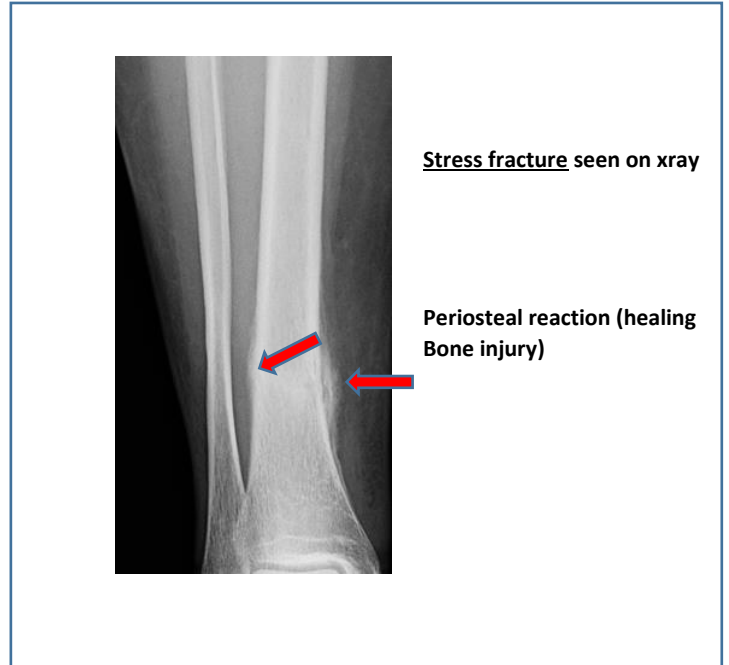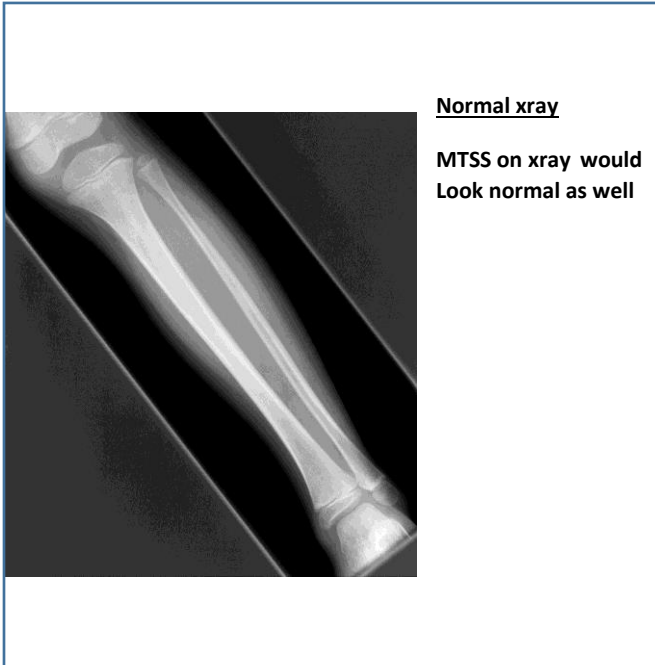
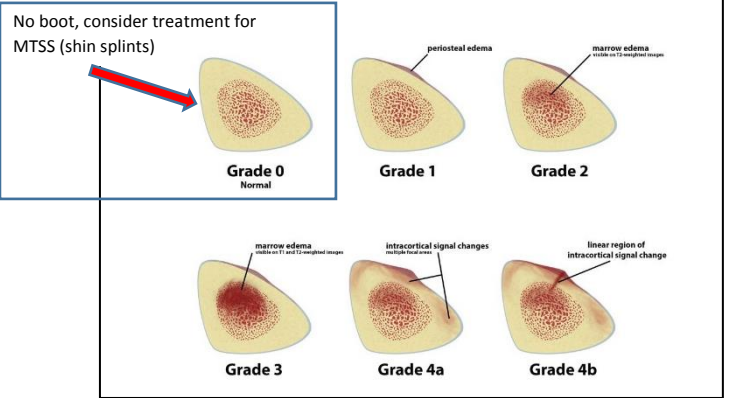


Radiologic Abnormalities for MTSS and Stress Fractures of Tibia (shin)



This is one "staging" system used with an MRI to help decide "diagnosis and treatment" for stress injury- all except "Grade 0" should have a period of time of NO IMPACT



Always consider using a sport's doctor familiar with the athlete's sport, level, and age group!