



When to load an implant?

The guide to monitoring
implant stability

Table of Contents

Objectives

Introduction by Prof. Neil Meredith

Chapter 1. Dental implants: History, trends and developments

Chapter 2. What is implant stability?

1. Stability and various types of mobility
2. Factors that influence treatment outcomes
 - a. Patient parameters
 - b. Surgical parameters
 - c. Treatment protocol
 - d. Clinician's experience

Chapter 3. Why measure implant stability?

1. Help determine when an implant is ready for loading and avoid premature loading
2. Manage patient with risk factors
3. Avoid unnecessarily long treatment times
4. Achieve more predictable outcomes
5. Identify situations in which it is best to unload a provisional and delay a final restoration
6. Optimize communication and increase trust with colleagues and patients
7. Improve case documentation and quality assurance

Chapter 4. How is implant stability measured?

1. The clinician's perception
2. Torque
 - a. Insertion torque
 - b. Seating torque
 - c. Reverse torque testing
3. CBCT
4. Percussion testing
5. Radiographs
6. Implant Stability Quotient

Chapter 5. What is the Implant Stability Quotient?

1. RFA – how does it work?
2. The concept of ISQ
3. The importance of ISQ
4. ISQ used with RFA

Chapter 6: Clinical Guidelines

1. How to interpret the ISQ Scale?
2. ISQ Values over time
3. ISQ best practices
4. ISQ in a full digital workflow
5. ISQ to support Immediate loading

Chapter 7: Clinical Cases

ISQ Scale References & References

Objectives

Dental implant treatments are safe. On average, more than 90% are successful. But that's an average success rate that may or may not hold true for each patient, each implant and each case, so success is not guaranteed. Of course, a failed dental implant can be agonizing for everyone involved. With today's new and innovative techniques, reductions in treatment times and opportunities for patients with risk factors to have successful implant therapy have improved significantly. But correctly assessing implant stability and osseointegration is still a challenge.



THIS EBOOK WILL HELP YOU:

1. Understand the process behind osseointegration.
2. Understand the factors that influence implant treatment outcomes.
3. Understand implant stability and the clinical benefits of measuring it to improve treatment outcomes.
4. Establish clinical guidelines to help you determine when to load an implant.



Introduction

It is hard to believe that it is 26 years since resonance frequency analysis was first used to measure implant stability and Osstell was conceived. Since that time the technique has evolved as the most widely used and researched method to measure dental implant stability, clinical parameters and success. Many thousands of research papers have been written utilising RFA and millions of patients have benefited from this measurement and evaluation technique.

I would like to congratulate the authors of this e-book in making a substantial addition to the knowledge base and providing excellent information and guidance for clinicians.

So what of the future?

The power in the world today is about data, leading to knowledge and communication; a CD player is of no value without music and a phone nothing without a SIM card. So will be true in the fields of medicine and dentistry. Communication will be king, and the sharing of knowledge and information to guide both inexperienced users and specialists alike will prove invaluable. Osstell has developed a knowledge base of data in the cloud enabling a unique and immensely powerful tool for the clinician. I look forward to seeing how the next 26 years evolve; hopefully.

There will always be usurpers to the Throne but Osstell is Resonance Frequency Analysis and ISQ is Osstell.

Professor Neil Meredith
BDS., MSc., PhD., PhD., FDS RCS
Co-inventor of RFA and Osstell.



CHAPTER 1

Dental implants: History, trends and developments

The discovery of osseointegration more than half a century ago led directly to the invention of the functional dental implant. Since then, lasting functionality, good aesthetics and improved quality-of-life for patients have consistently been associated with this solution. Nevertheless, a strong case can be made that improved diagnostic techniques are necessary to maintain a high level of treatment quality and consistently positive results.

Dental implants: History, trends and developments

Progress driven by parallel needs

Over the years, there have been many developments in the field of implant dentistry, spearheaded by implant companies. Examples include implant surfaces that integrate faster, innovative designs that make it easier to achieve high stability and the development of artificial bone material. Together these put implants in reach for more patients. New surgical methods have also been developed, such as sinus-lift surgery, flapless surgery and one-stage protocols. In addition, as implants gain wide acceptance, the number of clinicians offering them continues to increase.

Much of the progress has been driven by patient need: people want well-functioning, good-looking teeth, and they want them as soon as they can possibly have them. The implant industry's desire to create better products that not only improve treatment, but also increase profitability, has been another important driver. New products and methods have made implants a realistic choice for more patients, such as those with poor bone quality or volume.



Progress brings improvement – and new challenges

Change brings improvement, but it has also brought new challenges. Steady replacement of the traditional two-stage protocol with the new one-stage protocol is an example of a development that offers additional treatment possibilities while simultaneously raising the bar for achieving good results.

The increasingly common use of bone grafts is another example. They make it possible to provide the benefits of dental implants to people who may not have previously been candidates for the treatment. At the same time, however, they increase the number of higher-risk patients being treated.



Digitalization

Patient focused implant dentistry is changing and protocols, especially for immediate and early loading, are being redefined to accommodate the benefits of digital planning/ diagnostic tools.

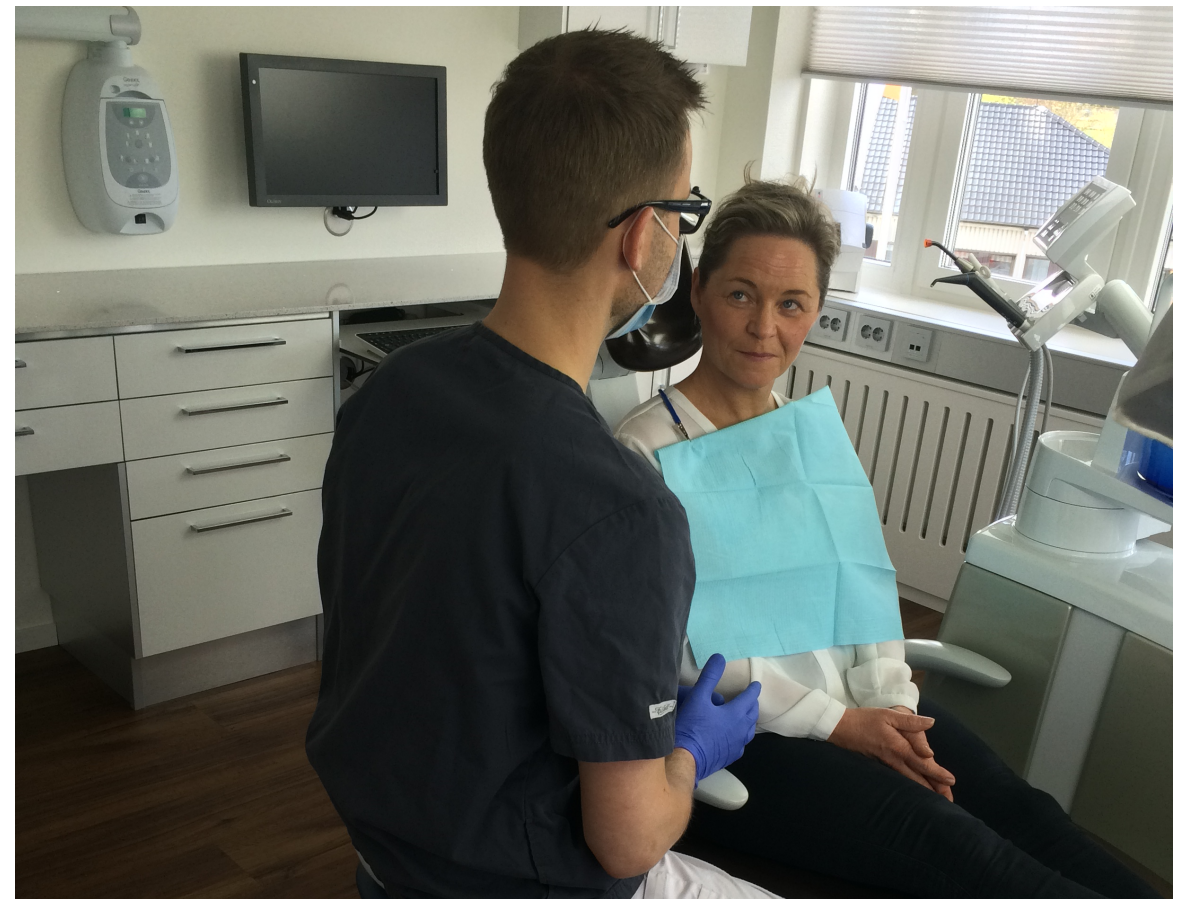Digital dentistry is today not only for early adopters anymore. A majority has already implemented digital dentistry in their daily practice, at least to some extent, and this number is growing day by day.

Digital protocols are providing more predictable and easier workflows for clinicians. Communication with the dental laboratory technician is clearly an asset when using a digital workflow, and also the improved interaction with the patient.

Better diagnostics for reliable quality and safety

New developments clearly fulfill demand for faster, less disruptive treatment options for more patients. In the vast majority of cases, they have been proven safe and effective. They also allow more dentists to treat more patients and to increase practice revenue. However, questions remain about how to achieve reliable quality and predictable outcomes in one-stage protocols, in more complicated cases and for less-experienced clinicians.

This eBook explores how better diagnostics in the form of objective measurement of implant stability levels can help clinicians to provide safe and predictable implant procedures for all patients.



What is implant stability?



The process of osseointegration is a critical part of implant therapy. This section discusses how the osseointegration and implant stability are related and the biological processes that are involved.

What is implant stability?

HIGHLIGHTS

1. Understand the process behind the osseointegration.
2. What happens after an implant is placed.
3. Factors that may have a direct impact in the osseointegration process.



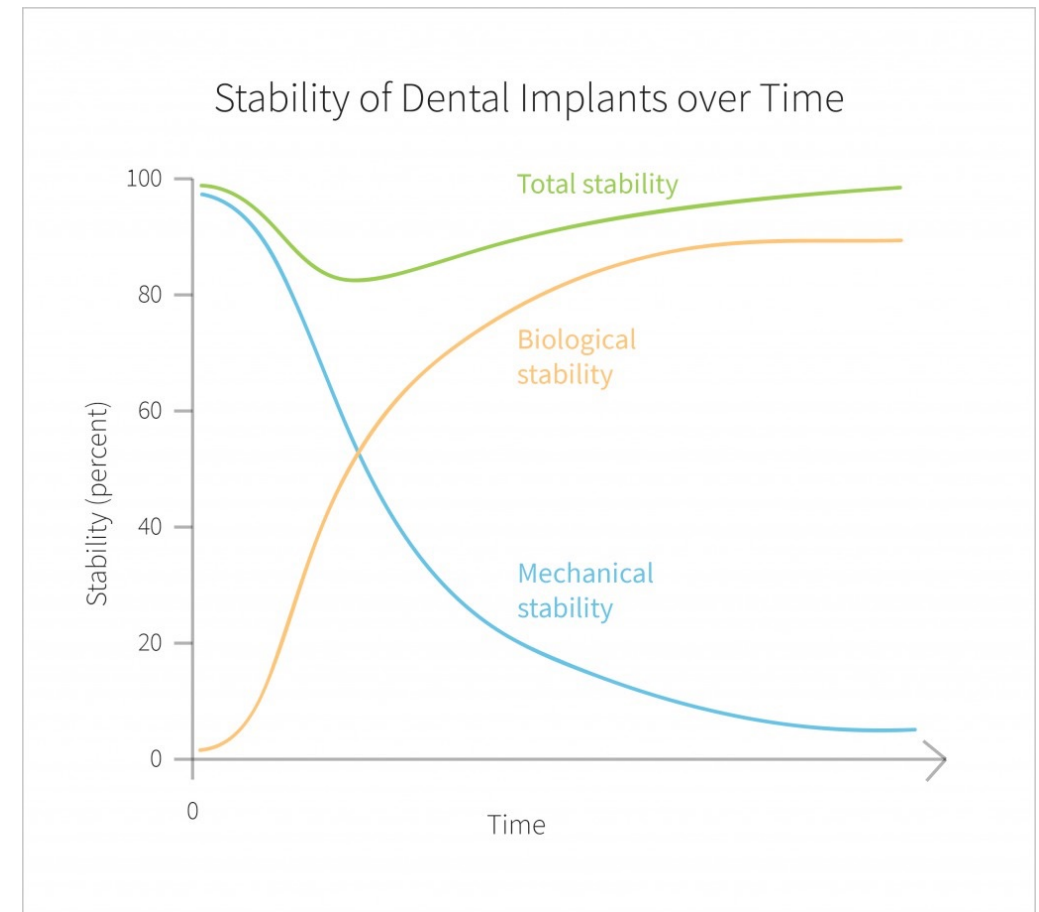
The demand for shorter treatment times along with a growing number of patients with risk factors require more from the dentists and the available technology. There is an increasing need to evaluate implant stability before final restoration that cannot be achieved using traditional methods such as torque and percussion tests (more on this in chapter 4).

It has long been recognized in the dental implant profession that implant stability is a critical factor in predictable treatment outcomes. First, let's define implant stability.

Implant stability can be seen as a combination of:

- **Mechanical stability**, which is the result of compressed bone holding the implant tightly in place. Mechanical stability is normally referred to as **primary stability**, the initial resistance to micro motion and micro mobility of a dental implant immediately upon its placement in the bone.
- **Biological stability**, or **secondary stability**, is the result of new bone forming around the implant and integrating the implant into the bone. Biological stability is the result of osseointegration. One ideally wants to achieve sufficient secondary stability in as little time as possible so that patients can return to normal function with their implant-supported restorations.

Mechanical stability (primary stability) is generally high immediately after implant placement, in the presence of sufficient quality and quantity of bone. This is among else due to mechanical compression of the bone when the implant is placed, and it often decreases in the short term.



Biological stability (secondary stability), on the other hand, does not play a role immediately after placement. It becomes apparent only as new bone forms around the implant, and it usually increases with time (if osseointegration takes place to a sufficient degree). It ultimately determines whether or not the implant-retained restoration will withstand the functional forces in the mouth and become an integrated part of a patient's overall dentition.

In other words, as a result of osseointegration, initial mechanical stability is supplemented and/or replaced by biological stability, and the final stability level for an implant is the sum of the two. Stability does not generally remain constant in the immediate period after implant placement. For example, there is likely to be an initial decrease in stability followed by a subsequent increase as the implant becomes biologically stable.

Osseointegration normally starts to show in a couple of weeks after implant placement and can be measured at patient check-ups. This will ensure that the stability level is high enough before the implant is loaded with the final restoration.

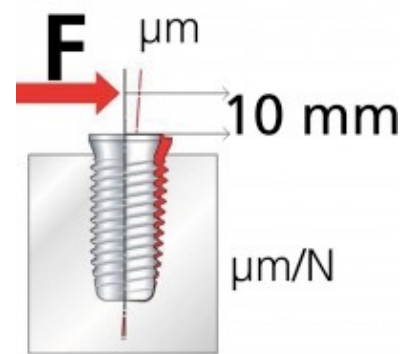
What happens after an implant is placed?

Osseointegration process regarding the articles from Berglundh and Abrahamsson 2003 and 2004.



Stability and various types of mobility

Even though implant stability is sometimes described as the “absence of clinical mobility” (Sennerby & Meredith 2000, 2008) in practice, a clinically mobile implant would be so obviously unstable that no responsible clinician would consider loading it. Therefore, the absence of clinical mobility is not a very practical definition for determining treatment outcomes.

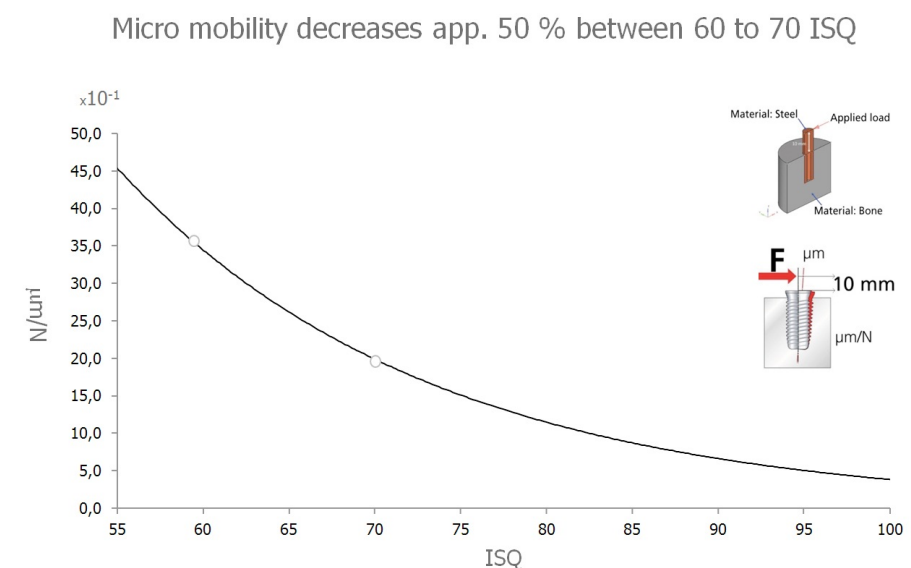


In addition, an implant that is stable enough to be loaded will nevertheless not be 100% immobile. It can be rotationally mobile due to the fact that when an implant is newly placed, bone has yet to be formed to fully integrate with the implant surface. With time, bone formation will lead to increased integration with the

implant surface and a stronger bone to implant interface.

An implant will also always exhibit some amount of lateral micro mobility. It is the amount of lateral micro mobility at various stages of treatment that seem to have a decisive effect on treatment outcomes. Therefore when discussing the potentially positive effects of precisely determining implant-mobility levels, we refer to levels of lateral micro mobility.

ISQ and micro mobility FEA 2013-02-11, Semcon



Factors that influence treatment outcomes

It has been clinically demonstrated that implant stability plays a significant role in determining treatment outcomes (Sennerby & Meredith 1998, Esposito et al. 1998). Implants show high success rates if certain preconditions are fulfilled (Sennerby & Meredith 2000, 2008).

Because they determine the level of implant stability (primary and secondary), clinical parameters (including both patient and surgical parameters) and treatment protocol are important factors in determining treatment outcomes.

It can also be argued that because implant stability is crucial to satisfactory treatment outcomes, being able to objectively determine levels of implant stability at various stages of treatment will increase satisfactory outcomes.

● Patient parameters

The single most significant patient parameters are bone quality and quantity. Risk factors associated with bone quality and quantity include:

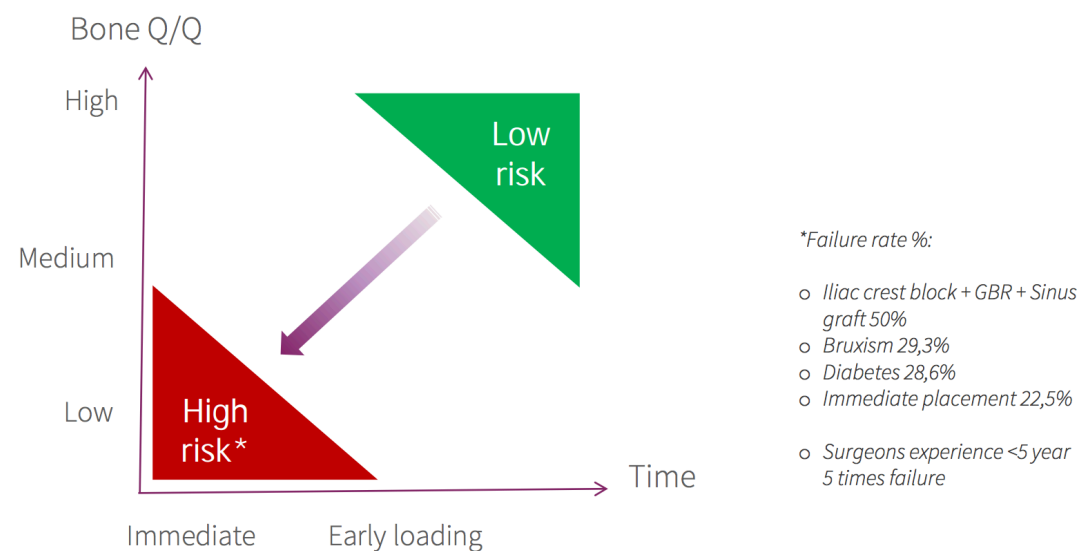
- The use of bone grafts
- Irradiated bone
- Lack of bone
- Poor quality bone
- Bone affected by medications or other patient systemic conditions



All of these conditions are increasingly common as more patients are given the option of being treated with dental implants.

Other patient parameters influencing outcomes are:

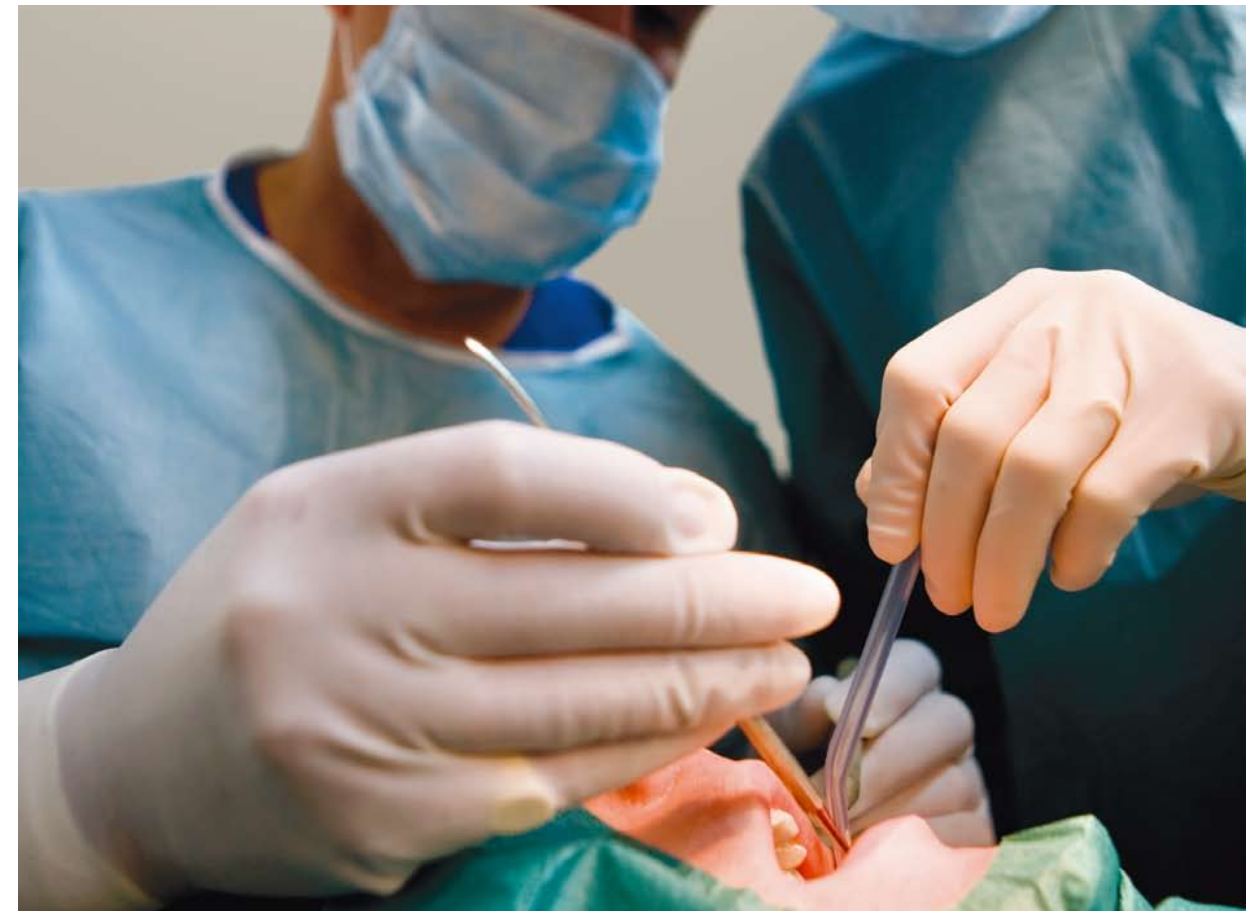- Smoking
- Diabetes
- Periodontal condition
- Bruxism



*Ting-Jen Ji, Joseph Y. K. Kan, Kitichai Rungcharassaeng, Phillip Roe, Jaime L. Lozada, Immediate Loading of Maxillary and Mandibular Implant-Supported Fixed Complete Dentures: A 1- to 10-Year Retrospective Study, Journal of Oral Implantology. 2012;38(S1):469-477.

● Surgical techniques

Surgical technique plays a role in determining implant stability and thus treatment outcomes as well. Risk factors here primarily involve instances of traumatic surgical technique that cause injury to the bone. It can be argued that this too is becoming increasingly common as more and more clinicians venture into the field of implant dentistry with less training and experience.

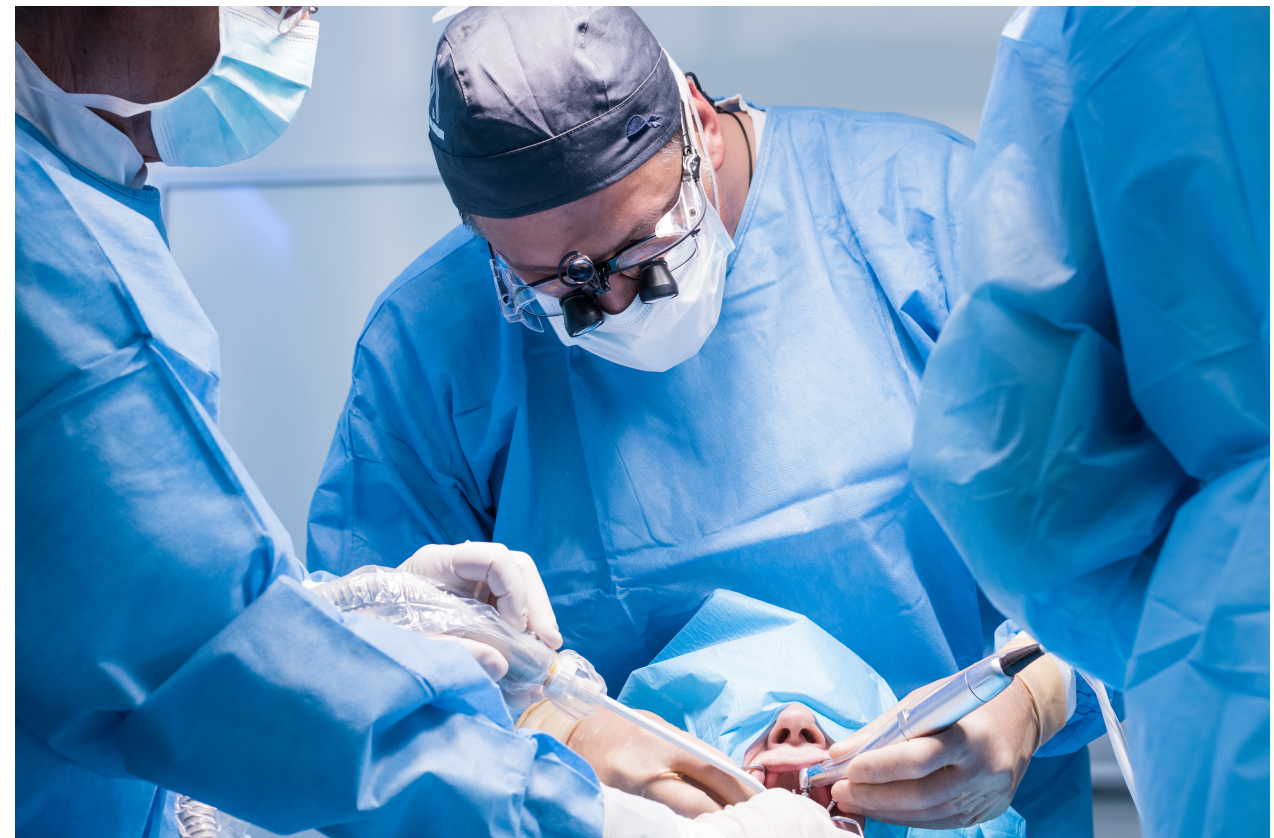

● Surgical protocols

The original two-stage protocol for implant surgery provided an initial healing period before loading, in which stability was enhanced by new bone formation resulting from osseointegration. Today, a one-stage protocol has become more common. In many cases, initial mechanical stability is sufficient to justify immediate loading. However, the lack of a pre-loading healing period arguably increases the risk of insufficient stability at the time of loading.

● Clinician parameters

Two parameters that are also important in factors influencing treatment outcomes are the amount of training and level of experience of the clinician. The results of a study by the University of Loma Linda in 2012 suggested that surgeons with limited experience (< 5 years) had a 12.2% failure rate, whereas experienced surgeons' failure rate was 2.4%. Another study by Da Silva in 2014 found that success rates “in general dental practices may be lower than those reported in studies conducted in academic or specialty settings”. The study from Payer et al. (2008) also indicated that the surgeon's experience “is the most relevant factor in precise implant placement”.



Why measure implant stability?



Why is torque not enough to make critical clinical decisions? Are there any other parameters we should consider before loading an implant?

This chapter will answer some of these questions to bring insights that may have a direct impact on daily practice.

CHAPTER 3

Why measure implant stability?

HIGHLIGHTS

1. Help determine when an implant is ready for loading and avoid premature loading.
2. Manage patients with risk factors.
3. Avoid unnecessarily long treatment times.
4. Achieve more predictable outcomes.
5. Identify situations in which it is best to unload a provisional and delay a final restoration.
6. Optimize communication and increase trust with colleagues and patients.
7. Improve case documentation and quality assurance.



Objective measurement of implant stability is a valuable tool for achieving consistently predictable results first and foremost because implant stability plays such a significant role in achieving successful outcomes.

- **Help determine when an implant is ready for loading**

It is essential to know the implant stability to select the most suitable loading protocol as each patient's healing time is individual. It allows to be confident that the implant is stable enough to be loaded.

- Immediate loading involves the final restoration placement within 48 hours of implant placement.
- Early loading: final restoration placed 1 to 12 weeks after implant placement.
- Conventional loading: final restoration placed over 3 months after implant placement.

Source: Definition from ITI

When a clinician makes a decision about early loading, objective measurement of implant stability can be invaluable: A specified degree of implant stability can serve as an inclusion criterion for immediate loading.

This conclusion is supported, for example, by a study by Östman, et al in which low failure rates were reported when a minimum stability level was used as an inclusion

criterion for immediate loading in totally edentulous maxillae and in posterior mandibles (Östman et al. 2005). In another study, Sjöström, et al, found lower primary stability for 17 implants that failed within the first year compared to 195 implants that were successful (Sjöström et al. 2007).

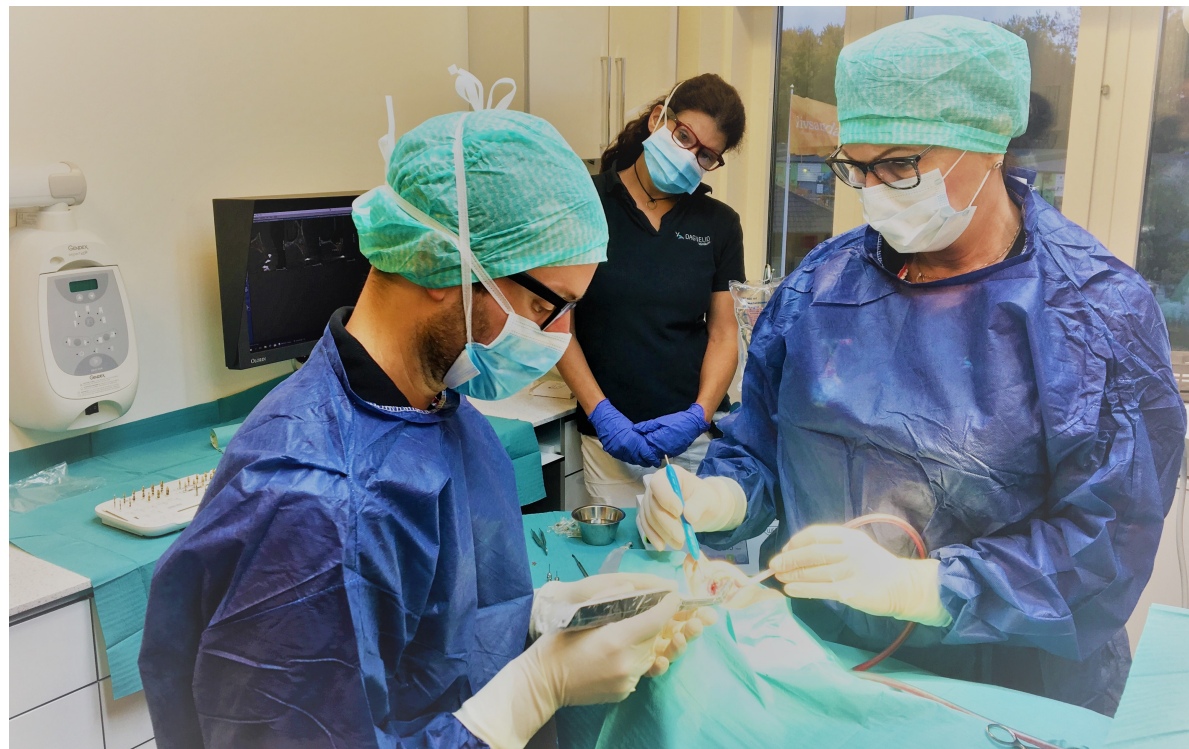- **Manage patients with risk factors**



A one-stage treatment protocol offers certain clear advantages for both patients and professionals alike: Fewer procedures are required and the patient will have well-functioning and attractive new teeth more quickly. However, because a two-stage protocol is

sometimes a better choice in higher risk situations, clinicians may avoid using a one-stage protocol in all higher-risk cases (such as cases where bone grafts have been used, for example).

With objective measurement of implant stability, clinicians can instead make well-informed decisions about protocol choices on a case-by-case basis. In other words, when low implant stability measurements indicate that immediate loading will jeopardize treatment outcomes, a two-stage protocol can be applied. In cases where high implant stability



measurements indicate that this is not the case, higher-risk patients will be able to enjoy the benefits of the faster, less disruptive one-stage protocol.

- **Avoid unnecessarily long treatment times**

Patients want well-functioning and aesthetic teeth, rather sooner than later. A personalized approach to treating patients is needed to provide optimal clinical results. Measuring implant stability allows to treat every patient individually instead of waiting a conventional period of 3 to 6 months. It gives the ability to monitor the osseointegration progress to move into the restorative phase of treatment when the patient is ready, which in many cases is much less than the 3-6 month period. A study by Kuchler et al. demonstrated that 83% of the 109 implants included in the study had an ISQ ≥ 70 (meaning high stability) after 8 weeks.

- **Achieve more predictable outcomes**

Correctly assessing implant stability and osseointegration helps provide long term functional and restorative success. The ability to have a reliable measurement analysis at the time of implant placement which can be referenced during various parts of the osseointegration process, gives the clinician the assurance that they are recommending loading protocols based on scientific data and the most favorable timelines for predictable success.

- **Identify situations in which it is best to unload a provisional and delay a final restoration**

Objective measurement of implant stability also supports making the right decisions about unloading. Sennerby and Meredith point out that when replacing an immediately loaded temporary prosthesis with a permanent prosthesis, “low (secondary) values may be indicative of overload and ongoing failure.” To avoid failure, they suggest that in such cases clinicians should


consider unloading, perhaps placing additional implants and/or waiting until stability values increase before loading the permanent prosthesis (Sennerby & Meredith 2000, 2008).

Furthermore, in a study by Glauser et al in which all implants in a sample group were loaded, those that failed showed significantly lower stability after one month than those that were successful. The authors conclude that, “this information may be used to avoid implant failure in the future by unloading implants with decreasing degree of stability with time (Glauser et al. 2003).



- **Optimize communication and increase trust with colleagues and patients**

Implant stability measurements can also help improve communication among clinicians, their dental professional colleagues and patients, which in turn can increase trust in the clinicians. When a clinician can refer to measurable values rather than subjective judgements as the basis for decision-making, it is easier to explain treatment choices. The clinician is also likely to appear more professional to patients and colleagues alike and to inspire more confidence.



Furthermore, it would be beneficial for colleagues cooperating during the treatment process to be able to refer to objective and accurate measurements, for example, when judging when an implant is stable enough to receive a final prosthesis.

- **Improve case documentation and quality assurance**

Finally, objective implant stability measurements can be used to document the clinical outcomes of implant cases, which can be useful at a later stage if a problem should occur or questions arise. In medicine, there are implant registries that are required of implant manufacturers, practitioners, etc. In the dental implant market, however, creating an implant registry for implant cases in a private practice are primarily left up to the individual clinician. Having documentation of implant cases can also serve the clinician by providing a Quality Assurance element to the practice as well as having benefits from a medico-legal point of view if needed.



How is implant stability measured?

In some clinical protocols it is absolutely mandatory to know “what is happening” with an implant that has been placed.

Implant stability is more than a perception or intuition: it has to be validated through an objective and feasible device.

How is implant stability measured?

HIGHLIGHTS

1. The clinician's perception
2. Torque
3. Radiographs
4. CBCT
5. Percussion testing
6. Implant Stability Quotient (ISQ)

Although objective measurement of implant stability clearly offers important advantages, the answer to the question of how to best obtain such measurements has perhaps been less obvious. Over the years a number of methods have been used to measure implant stability with varying degrees of success:

● The clinician's perception

One method of trying to evaluate primary stability is quite simply the perception of the clinician. This is often based on the cutting resistance and seating torque of the implant during insertion. A perception of “good” stability may be heightened by the sensation of an abrupt stop when the implant is seated. The geometry of an implant with a fixed collar creates just such a firm stop and thus lends itself to a perception of high stability (Sennerby & Meredith 2000, 2008).

An experienced clinician's perception is of course invaluable and should under no circumstances be discounted. However, perception is

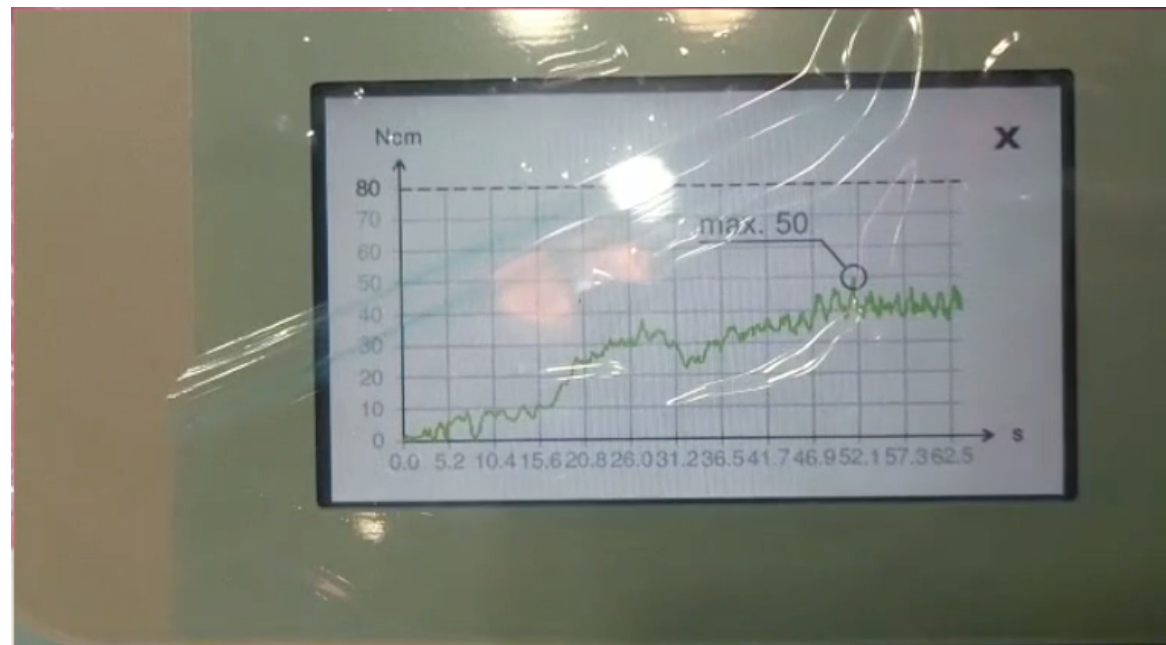
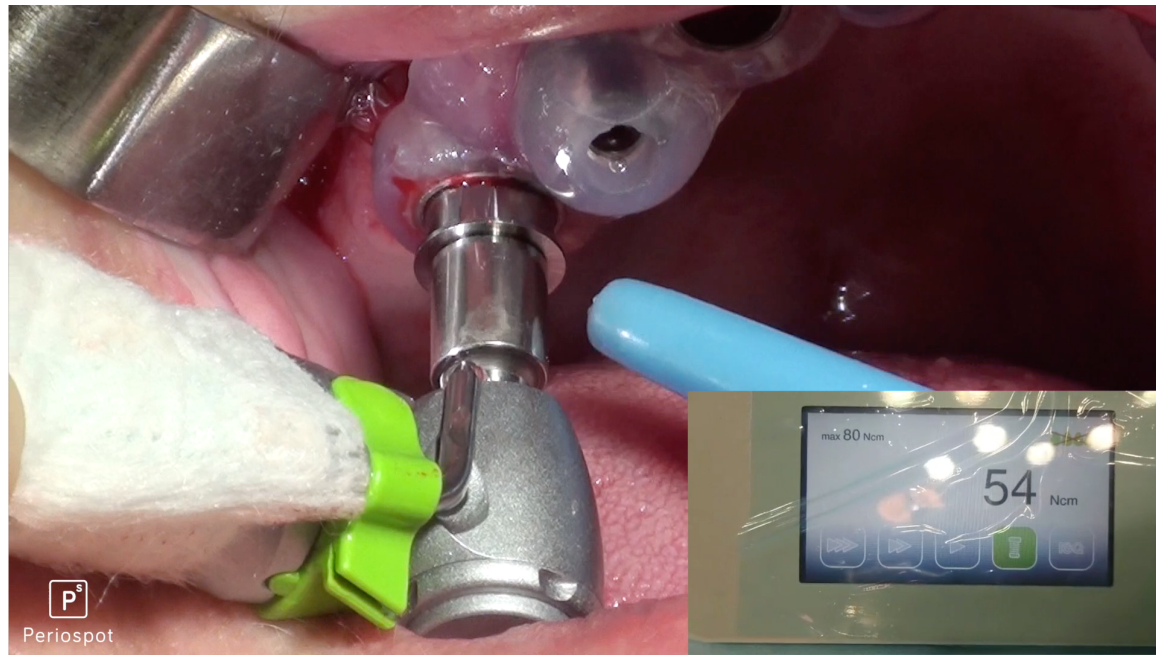obviously not possible to quantify, to consistently and effectively teach to others or to use as a basis for future comparison. Particularly in higher-risk cases, relying on perception is often not sufficient to ensure positive treatment outcomes. In addition, one's personal perception is difficult to communicate to others. But most importantly, this type of measurement can only be made when the implant is inserted – it cannot be used later, for example, before loading the implant (Degidi et. al. 2009).

● Torque

Torque is sometimes used to describe the stability of an implant. However, torque does not necessarily correlate to implant stability as previously described. Torque measures the rotational friction between the implant surface and the bone combined with the force required to cut the bone if that is the case, and the pressure force from the surrounding bone.

● Insertion torque

Measuring insertion torque when installing the implant is an attempt to quantify the clinician's tactile perception. A disadvantage of this method is that the insertion torque varies depending on the cutting properties of the implant and the presence of fluid in the preparation. However, the method does yield some information about the energy used when installing the implant. Its main disadvantage is that, like the clinician's perception, insertion torque measurements can only be used when the implant is inserted and are not possible at later stages of the treatment process.



Picture 1- 2: Torque control. W&H Implantmed® device allows monitoring the exact insertion torque during implant placement.

● Seating torque

Like insertion torque, the final seating torque gives some information about the primary stability of the implant. The main disadvantage is that it cannot be repeated at a later stage, and thus it cannot serve as a reference for the next treatment stage. Seating torque can also be misleading in a case of high final torque caused by the top or the apical part of the implant hitting cortical bone.

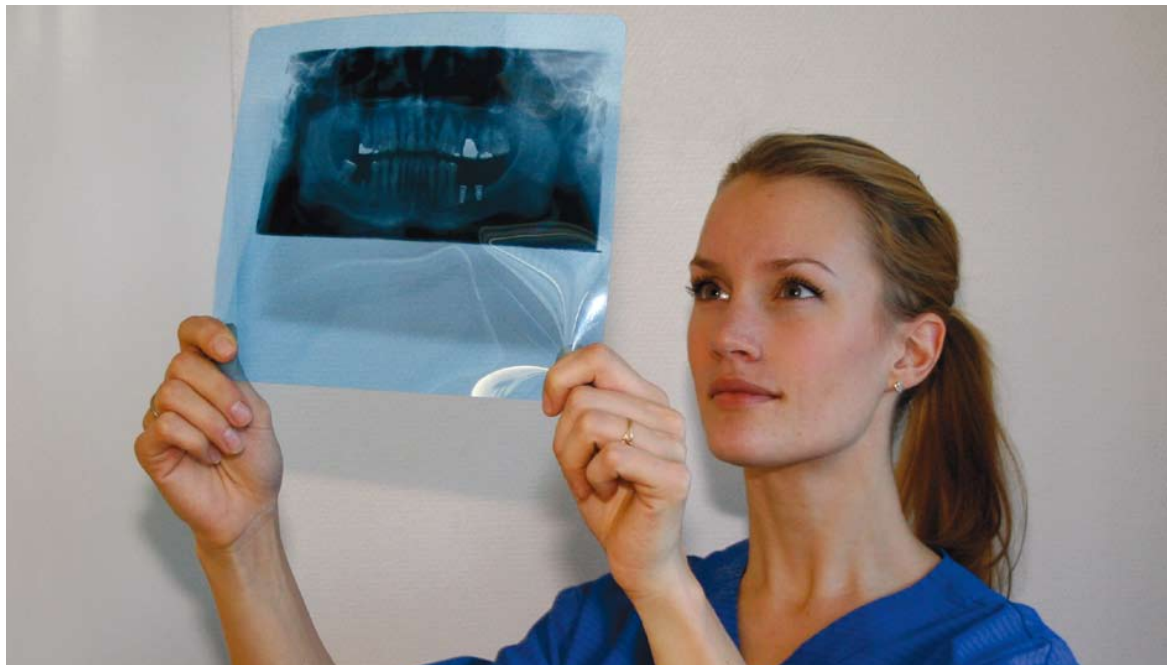
● Reverse torque testing

Application of reverse torque has been used to assess secondary implant stability at the abutment connection. Implants that rotate when reverse torque is applied are removed. However, this method has fallen into disrepute for a number of reasons: As demonstrated in one study, the stress of the applied torque may in itself be responsible for the failure (Sullivan et al. 1996). In addition, work with animals has demonstrated reintegration of loosened

and rotationally mobile implants (Ivanoff et al. 1996).

Finally, measurement of lateral mobility is more useful than measurement of rotational mobility as an indicator of a successful treatment outcomes. A rotationally mobile implant can be laterally stable and reverse torque testing fails to measure – or take into account – lateral mobility.

● Radiographs



Radiographic evaluation is a semi-invasive method that can be performed at any stage of healing. Radiographs

can yield other information such as implant position, but neither implant stability, bone quality or bone quantity can be determined with this method. Even changes in bone mineral cannot be radiographically detected until several months have passed and until at least 40% of mineralisation has occurred. Moreover, excessive radiographs can unnecessarily expose patients to radiation and adds to the cost of the treatment for the patient.

● CBCT



By Scott D. Ganz, DMD

Prosthodontics, Maxillofacial
Prosthetics & Implant Dentistry

CBCT imaging and interactive software provide the foundation for proper diagnosis and treatment planning based on bone topography, thickness of cortical plates, bone density, and

proximity to adjacent vital structures. Clinicians must use this invaluable tool to assess potential implant receptor sites to avoid complications and provide accurate outcomes.



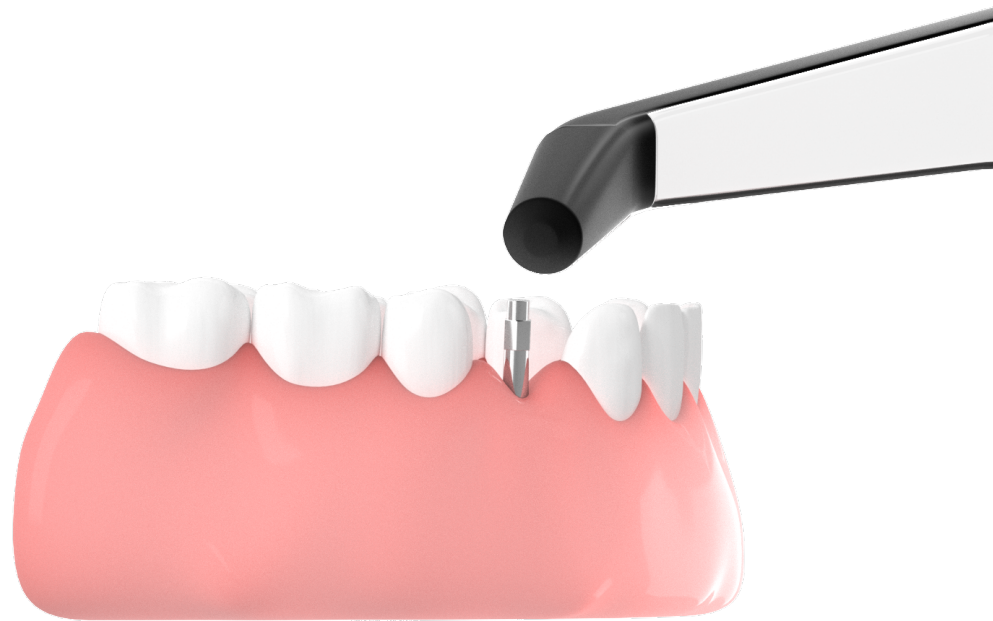However, the diagnostic and planning phase can only subjectively estimate whether an implant will be stable within the bone. At the time of surgery it is essential to have a true objective measurement of implant stability. RFA/ISQ imparts this crucial knowledge. Additionally, the non-destructive methodology reveals the status of the integration process at insertion, uncovering, loading, final restoration, and the lifespan of the implant(s).

● Percussion testing

Percussion testing is a tool-based method for testing implant stability. This method involves tapping the implant with a tool, such as a mirror handle, and listening for a (“good”) ringing tone. There are also electromechanic devices for this purpose, such as Periotest.

This type of test is highly subjective and has largely been discredited. As pointed out by Sennerby and Meredith, percussion testing: “... probably provides more information about the tapping instrument and at best yields only poor qualitative information.”(Sennerby & Meredith 2000, 2008) The disadvantages of the electronic percussion tests are that they are rather insensitive to changes in implant stability and the results are user-dependent.

- **Implant Stability Quotient (ISQ)**



The Implant Stability Quotient is based on Resonance Frequency Analysis to determine implant stability and osseointegration. The result is presented as an ISQ value of 1-100. The higher the ISQ, the more stable the implant.

The measurements are objective and can be repeated in a non-invasive, dynamic way to monitor the development of osseointegration. It measures the stiffness of the implant-bone interface, throughout the entire body of the implant.

Currently, over 900 scientific studies support the RFA/ISQ method.

In the following chapter, we will describe exactly how ISQ works and examine its usefulness as a diagnostic tool.



What is the Implant Stability Quotient?



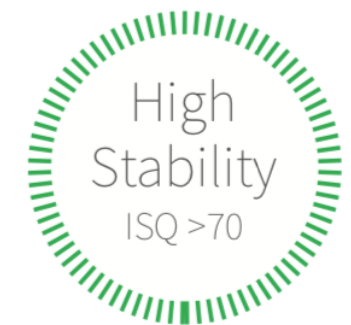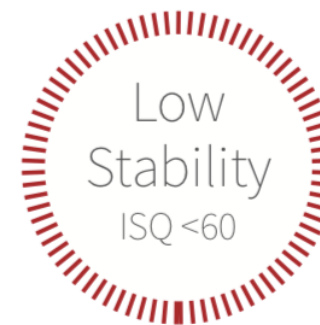RFA (Resonance Frequency Analysis) is the only way to objectively and non-invasively determine implant stability and to assess the progress of osseointegration – without jeopardizing the healing process. The clinical decision before loading a final restoration should be taken after measuring ISQ.

What is the Implant Stability Quotient?

HIGHLIGHTS

1. How does it work?
2. The importance of ISQ
3. Benefits of using ISQ

Implant Stability Quotient (ISQ) is an objective industry standard for measuring implant stability. It is based on Resonance Frequency Analysis (RFA). The result is presented as an ISQ value of 1-100. The higher the ISQ, the more stable the implant.



How does it work?

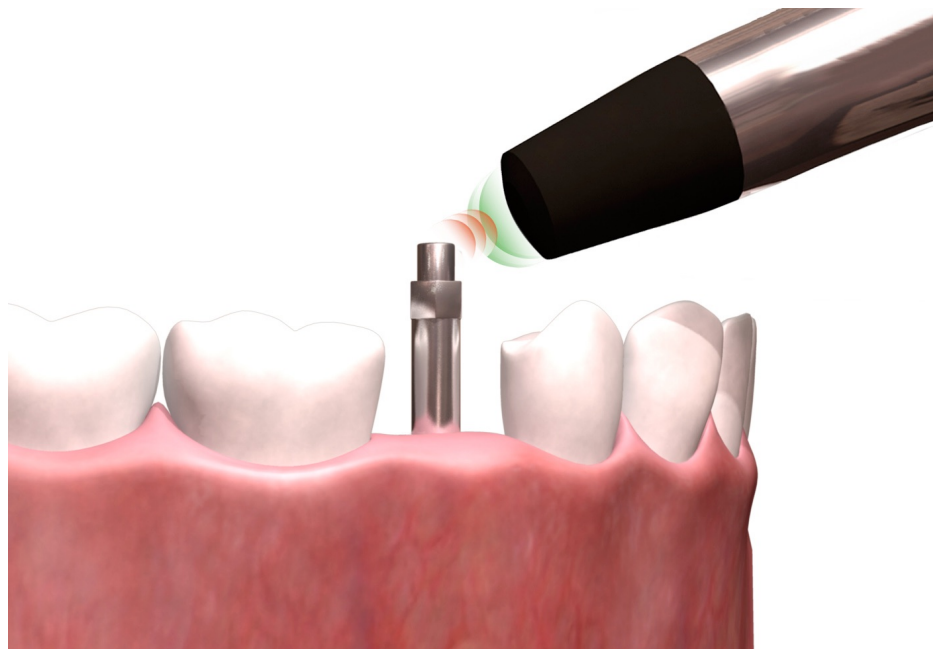
The technology is based on the tuning fork principle.

A new, sterile and disposable SmartPeg is attached to the implant and made to vibrate, just like a tuning fork. The



purpose is to find the resonance frequency i.e. the frequency with the strongest vibration.

The higher the resonance frequency, the higher the ISQ value and the more stable the implant is. This measurement is done quickly; it takes only a few seconds and is non-invasive. The result is presented as an ISQ value between 1-100.



The importance of ISQ

The development of ISQ makes it possible to determine a standard clinical range within which

stability values should fall to achieve a successful treatment outcome. The studies mentioned in Chapter 4 of this paper (Sennerby and Meredith; Östman, et al; Sjöström, et al and Glauser, et al) were based on measurements made with RFA and ISQ. More than 900 studies provide good indications that the acceptable stability range lies between 55 and 85 ISQ, with an average ISQ level of 70 when loading the implant.

ISQ also makes it possible to attach specific values to the graph from Chapter 3, making it a useful tool for determining if an implant is sufficiently stable at any stage of the treatment process.

Benefits of using ISQ

- Help determine when an implant is ready for loading and avoid premature loading
- Manage patient with risk factors
- Avoid unnecessarily long treatment times
- Achieve more predictable outcomes

- Identify situations in which it is best to unload a provisional and delay a final restoration
- Optimize communication and increase trust with colleagues and patients
- Improve case documentation and quality assurance

ISQ is the only objective, reliable and non-invasive way to measure implant stability at placement and multiple times during the healing phase, thereby monitor the level of biological stability before proceeding to final restoration.

Why they measure ISQ



"Osstell has become my personal guide in determining the appropriate time to load patients' implants, and I now use it for every implant case."

Prof. Peter Moy



"In daily practice, we never measure the insertion torque since we use Osstell instead to monitor implant stability. For non-splinted implants, we want the second ISQ value to be ≥ 70 to initiate the prosthetic rehabilitation with functional loading. In most implant patients, this is either at 4 or 8 weeks of healing allowing an early loading protocol."

Prof. Daniel Buser



"Osstell use is critical for my implant practice. This device more than pays for itself as there are always several patients who heal slowly or who have implants placed with extremely low insertion torque. This confounds my ability to predict when healing has been adequate to proceed to the restorative phase. No longer am I the villain who slows up patient care, but it is objective data about the patient's healing that becomes the determining factor."

Paul S. Rosen, DMD, MS, FACD

Clinical Guidelines

In this section, clinical guidelines are presented based on all literature and clinical best practices using ISQ.



Clinical Guidelines

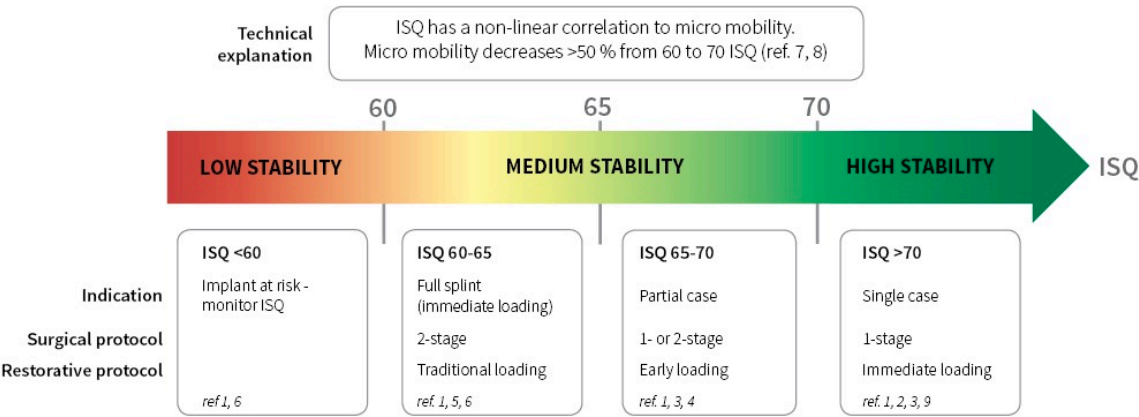
HIGHLIGHTS

- 1. How to interpret ISQ Values?
- 2. ISQ values over time.
- 3. ISQ best practices.
- 4. ISQ to support immediate loading.

1. How to interpret ISQ values?

ISQ, or Implant Stability Quotient, is a scale from 1 to 100 and is a measure of the stability of an implant. The ISQ scale has a non-linear correlation to micro mobility. With more than 900 scientific references, we now know that high stability means >70 ISQ, between 60-69 is medium stability and < 60 ISQ is considered as low stability.

The ISQ scale



1. Sennerby L. Prof. Implantologie 2013;23(1):21-33
2. Kokovic V, Jung R, Feloutz A, Todorovic V, Jurisic M, Hammerle C. Clinical Oral Implants Research, 00, 2013, 1-6
3. Michael M. Bornstein, Dr. med. dent.; Christopher N. Hart, DMD; Sandro A. Halbritter, Dr. med. dent.; Dean Morton, BDS, MS; Daniel Buser, Prof. Dr. med. dent. Clin Implant Dent Relat Res 2009
4. Serge Baltayan, Joan Pi-Anfruns, Tara Aghaloo, Peter Moy J Oral Maxillofac Surg 74:1145-1152, 2016
5. Par-Olov Östman DDS, PhD, MD, Private practitioner, Falun- and Biomaterial group, Sahlgrenska. Academy, Gothenburg, Clinical Implant Dentistry and Related Research, Volume 7, Supplement 1, 2005
6. Daniel Rodrigo, Luis Aracil, Conchita Martin, Mariano Sanz. Clin. Oral Impl. Res. 21, 2010; 255-261
7. Pagliani L, Sennerby L, Petersson A, Verocchi D, Volpe S & Andersson P. Journal of Oral Rehabilitation 2012
8. Paolo Trisi PhD, Teodoro Cariesi DDS, Marco Colagiovanni DDS, Giorgio Perfetti MD, DDS. Journal of Osteology and Biomaterials, Volume 1, Number 3, 2010
9. Stefan Paul Hicklin, Esther Schneebell, Vivianne Chappuis, Simone Francesco Marco Janner, Daniel Buser, Urs Brägger Clin. Oral Impl. Res 00, 2015; 1-9

The above is a summary of scientific data and not an official recommendation by Osstell.
To monitor osseointegration measure at placement and before final restoration.



Implant Stability Quotient (ISQ) is an objective world standard for measuring implant stability. Higher values are generally observed in the mandible than in the maxilla due to the normally more dense bone in the mandible.

Check page 54 for the summary of the references to the ISQ Scale.

2. ISQ values over time

The overall average value of all implants over time is approximately 70 ISQ. If the initial ISQ value is high, a small drop in stability normally levels out with time. A drop in stability or a decrease should be taken as a warning sign. Lower values are expected to become higher after the healing period. The opposite could be a sign of an unsuccessful implant and actions should be considered.

High initial stability (ISQ values 70 and above) tends to not increase with time, even if the high mechanical

stability will decrease to be replaced by a developed biological stability.

Lower initial stability will normally increase with time due to the lower mechanical stability being enforced by the bone remodeling process (osseointegration). Values such as ISQ 55 or lower should be taken as a warning sign and actions to improve the stability might be considered (larger implant diameter, prolonged healing time etc.) (Sennerby & Meredith 2000, 2008).

3. ISQ best practices

ISQ should be measured at implant placement for a baseline reading and then again before decision to proceed to final restoration. This is needed to see a trend and assess if osseointegration is happening or not. The measurement can be repeated at any time during the treatment. Documenting ISQ measurements using Osstell technology such as the online service Osstell Connect provides guidance on predicting healing time and keeping track of the data.

4. How ISQ Influences My Decisions Regarding Immediate Loading



By Barry P. Levin, D.M.D.

Diplomate, American Board of Periodontology

Private Practice, Jenkintown, PA

Many factors are integral in decision-making for immediately loading implants. In the maxillary anterior sextant, patients often refuse removable temporary restorations, and opt for conventional fixed prosthodontics over implant therapy, when faced with losing an anterior tooth. The emergence of immediate implant placement and provisionalization (IIPP), enables clinicians to avoid removable, provisional restorations.

One criterion for immediate restorations is insertion torque. Investigators recommend a wide range of ITV's as criteria for when to temporize implants. Unfortunately, this practice is empirical rather than evidence-based. Another method of determining an

implant's level of primary stability is ISQ. This value has been shown not be correlated with ITV for non-molar, immediate implants (Levin 2016).

In this clinical study of 59 consecutively-placed immediate implants in 52 patients, no correlation between the two values was confirmed. In a subset of 14 implants receiving immediate provisional crowns, ITV's was 23.2 Ncm, considerably lower than most recommendations in the literature. ISQ values however, were quite high, averaging 69.4, within the range of "safety" recommended by many clinicians.

All of these implants successfully osseointegrated without complications. If ITV was the only criteria used, none of these patients would have received fixed provisionals. This highlights the value of recording ISQ at time of implant placement and not to rely on ITV as the sole criterial for immediate temporization.

Clinical Cases

This chapter is dedicated to show how Osstell is helpful in different clinical situations. Through this guide, different approaches are exposed so clinicians can start using these protocols in their daily practice to increase predictability and reliability in different treatments options.



Clinical cases

HIGHLIGHTS

1. When To Immediately Load an Immediate Implant, by Barry P. Levin, D.M.D.
2. How To Confidently Reduce Treatment Time, by Charles D. Schlesinger, DDS.
3. Maxillary Central Incisor Implant Supported Crown Brief Case Report - by Scott D. Ganz, DMD.

When To Immediately Load an Immediate Implant



By Barry P. Levin, D.M.D.

Diplomate, American Board of Periodontology

Private Practice, Jenkintown, PA

Temporizing immediate implants in the esthetic zone is quite common. Assuring safety and predictability is critical and decision-making regarding when to perform IIPP is critical. Achieving primary stability is a prerequisite for providing a provisional restoration at the time of implant placement. Many surgeons rely on measurable parameters to base their clinical decisions. Commonly, insertion torque value (ITV) is used to gauge how “stable” an implant is within the osteotomy. This is strictly a measurement of rotational stability. Another method of quantifying stability is resonance frequency analysis or RFA, which measures axial stability. This is measured with the Osstell devices and is delivered an implant stability quotient or ISQ score in a range of 0-100.

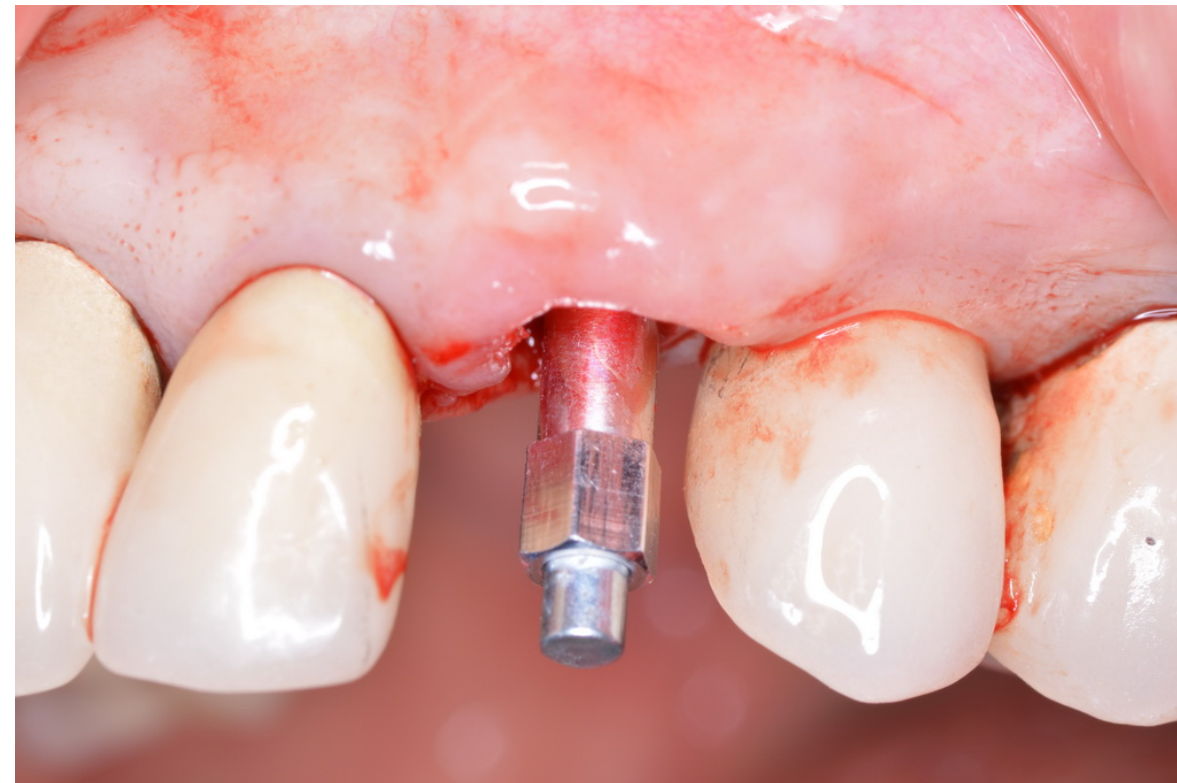A clinical study of immediate implants in non-molar sites failed to demonstrate a correlation between ITV and ISQ (Levin). In this study of 59 consecutively placed implants in 52 patients, the ITV's ranges from 20-50 Ncm with an average of 28 Ncm. The ISQ values ranged from 51-80, with an average of 68.

Interestingly, a subset of 13 patients received immediately provisionalized implants, with an average ITV of 23.2 Ncm and average ISQ of 69.4. Had the ITV been the sole criteria for immediate loading, and the value of 40 Ncm been arbitrarily chosen, only two of these 14 implants would have been considered “safe” to temporize at time of implant placement.

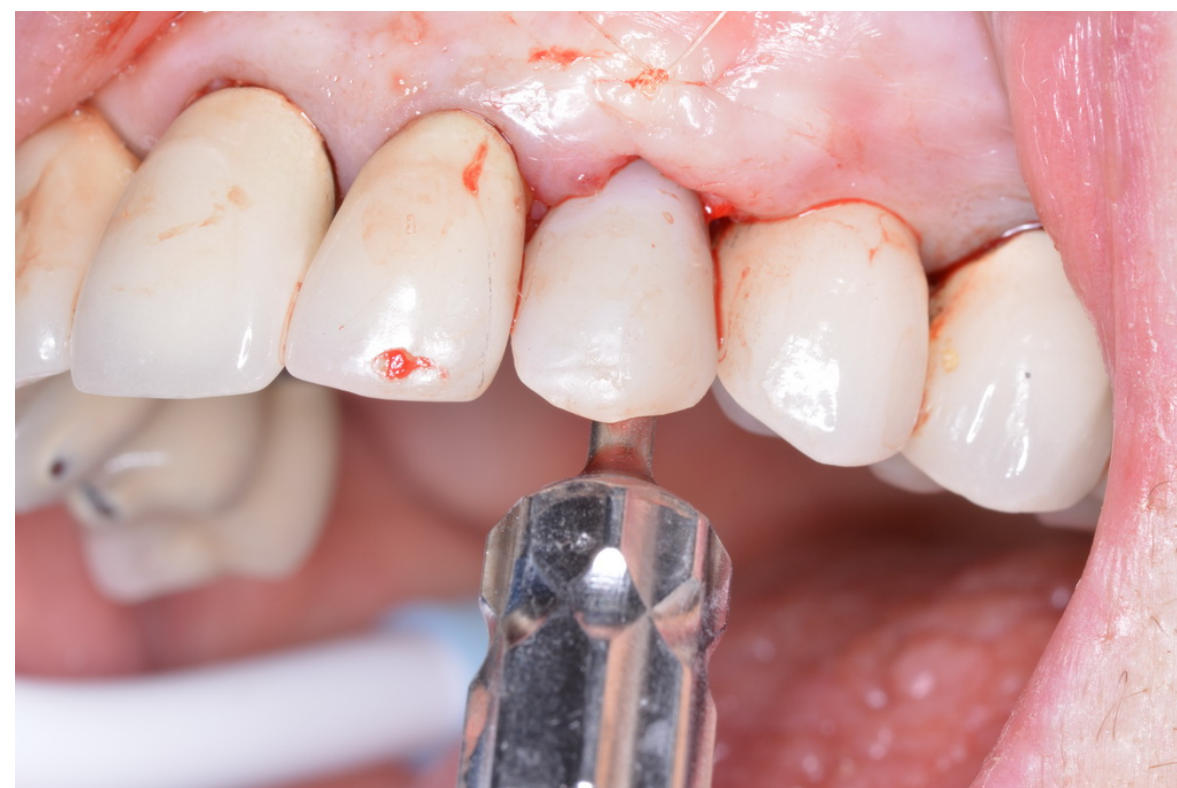The ability for clinicians to determine which implants are able to successfully load/temporize at time of placement is critical. Techniques which objectively determine the stability of implants, and repeatable methods capable of gauging progression of digression of osseointegration are extremely valuable.

Clinical Example:

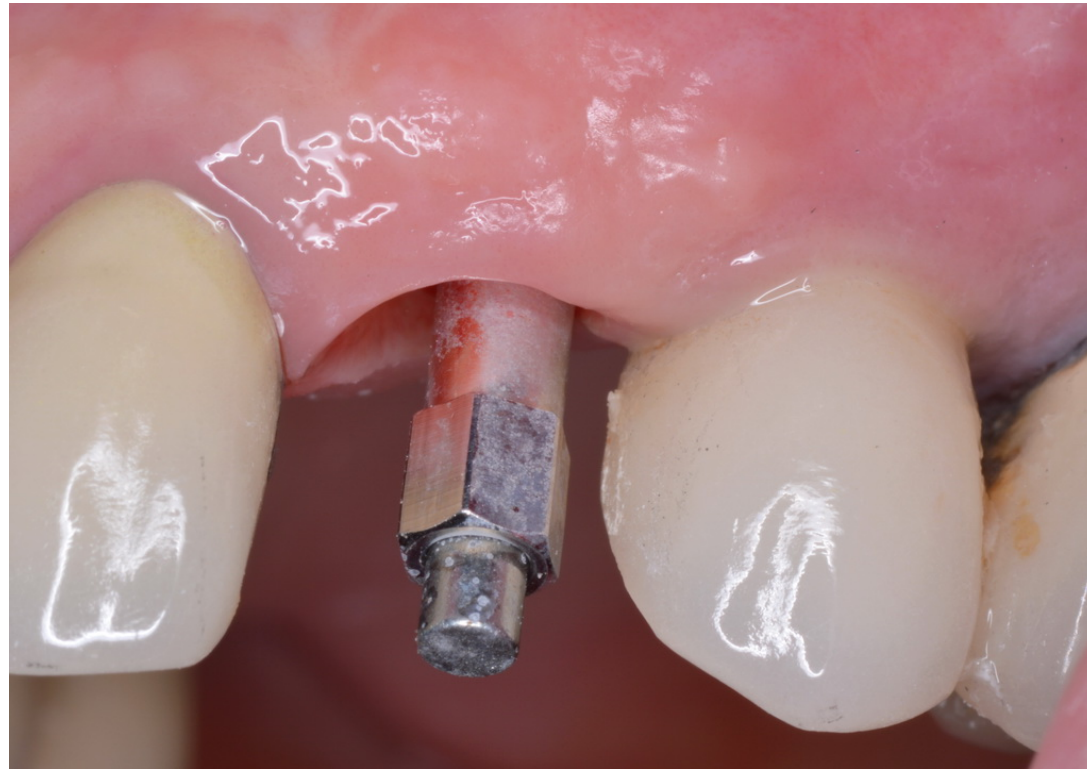
Tooth #11 required extraction and immediate replacement. Following flapless extraction, a 3.6mm x 13.0mm implant was placed with an insertion torque value of 20 Ncm. ISQ was recorded with a score of 66 with the Osstell device. The procedure was performed with a Dermal Apron Technique. The temporary restoration was out of occlusal contact with the antagonist, mandibular teeth and the patient was instructed to avoid function for 6 weeks in this area. At 10 weeks, the provisional crown was removed for follow-up ISQ measurements. The second value was ISQ of 73. This increase demonstrated enhanced secondary stability or osseointegration. The crown was restored and has been in function for over 4 years without complications.



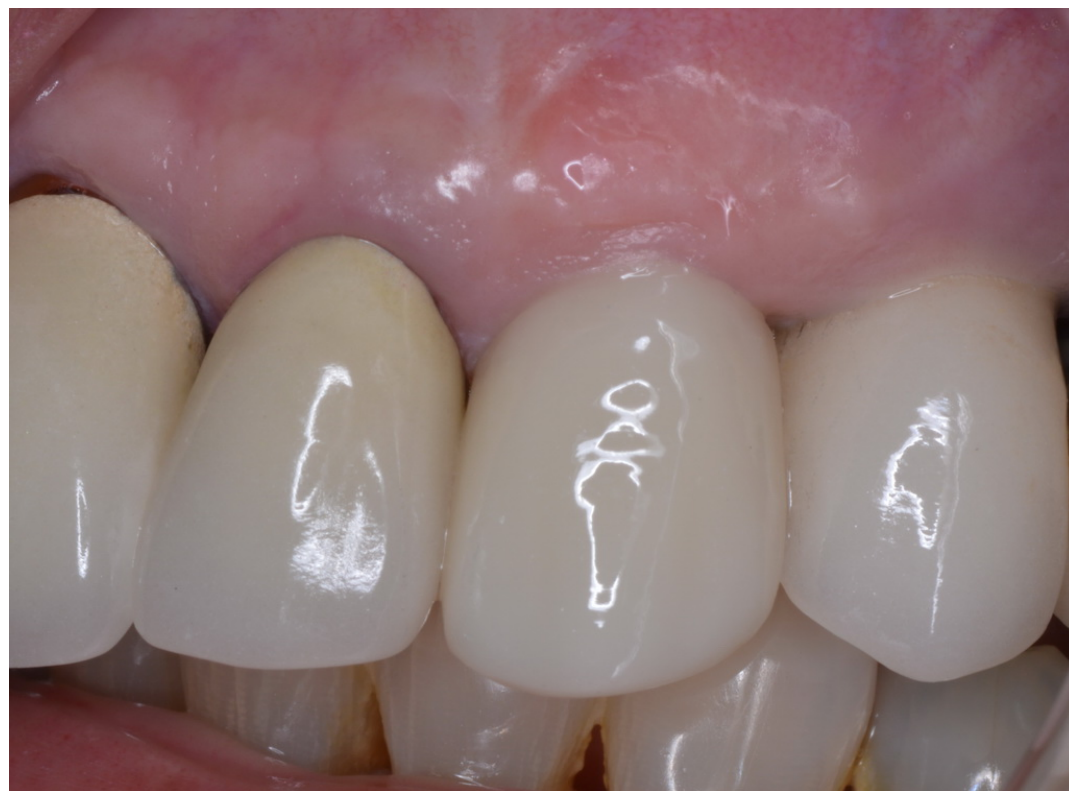Initial ISQ of 66 at time of immediate placement



Immediate temporization via Dermal Apron Technique



Follow up ISQ at ten weeks of 73



Final Restoration

How to Confidently Reduce Treatment Time



By Charles D. Schlesinger, DDS

The patient presented with a non-restorable #8 which was scheduled for extraction and immediate placement of a dental implant (Fig. 1). The tooth was atraumatically extracted and the site thoroughly debrided (Fig. 2). As per the Hahn Tapered Implant protocol an osteotomy was created approximately 4mm below the crest through the palatal wall (Fig. 3). Once allograft was placed against the facial wall to fill the ensuing gap, a 5 x 10mm implant was placed with a seating torque of 40N/cm was achieved. Normally, this torque value would be enough to possibly immediately load in the anterior, but experience has taught me to always check the ISQ first. In this case the ISQ value was only 50 therefore immediately loading this implant would be a risky endeavor.

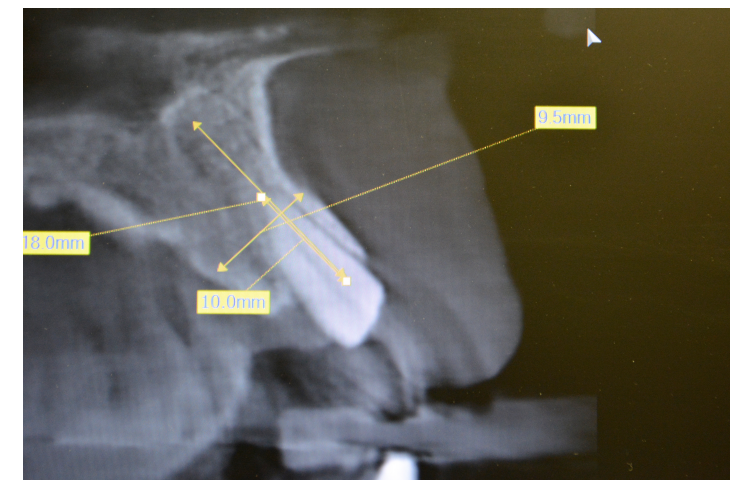


Fig. 1: CBCT of #8

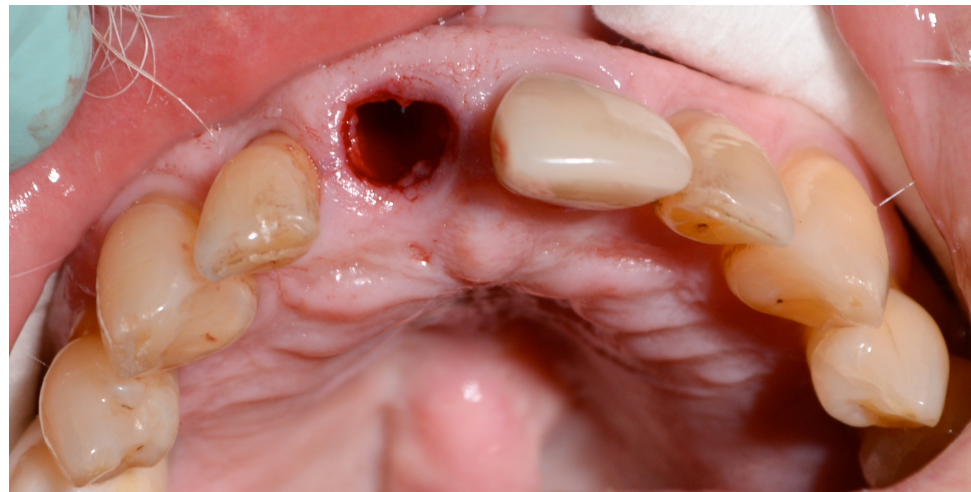

Fig. 2: Site after extraction

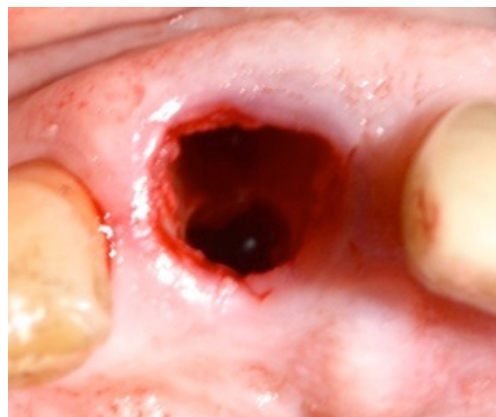

Fig. 3: Completed osteotomy

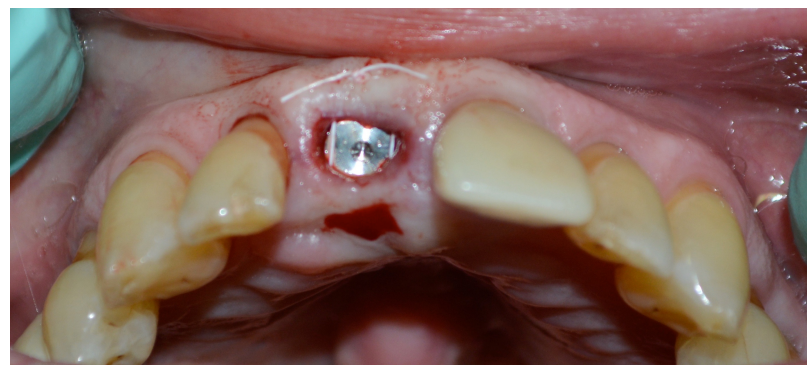

Fig. 4: Occlusal view of healing abutment

The reason I rely more heavily on the ISQ value vs torque is that RFA is a much better predictor of potential lateral instability. This lateral instability, when it exceeds 150 microns, will result in soft tissue encapsulation and eventual loss of the implant.

A tissue forming healing abutment was placed and the soft tissue secured with a single sling suture (Fig. 4, 5). At approximately 2 months post-operatively the patient was brought in and a new ISQ was recorded. The value was climbing, but was not quite at the level necessary for restoration. Normally, a value of 68 would be OK in my opinion to load, but tooth #8 will be subjected to a lot of lateral loading due to its position in the mouth. At 2 months 3 weeks the patient returned. The soft tissue needed to be removed from over the abutment and this was done with a diode laser (fig. 6). An ISQ of 84 (Fig. 7) was recorded and the restorative phase of treatment was commenced (Fig. 8).

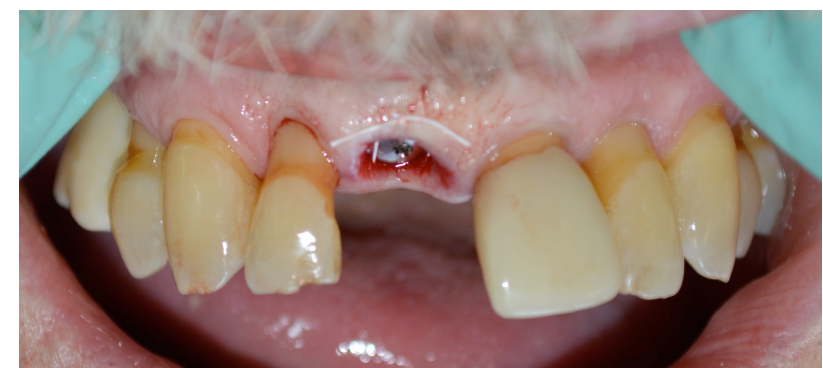

Fig. 5: Facial view of sling suture

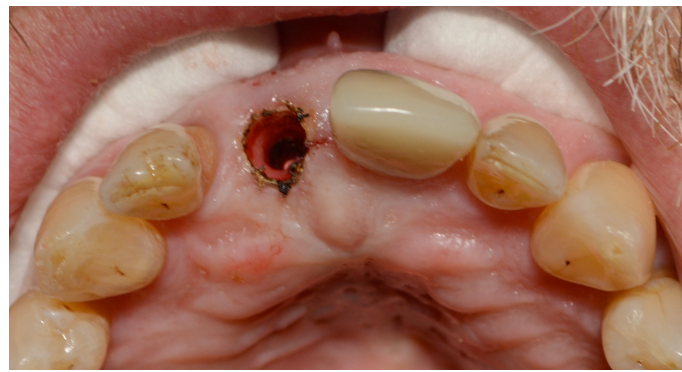

Fig. 6: Area after removal of soft tissue with laser

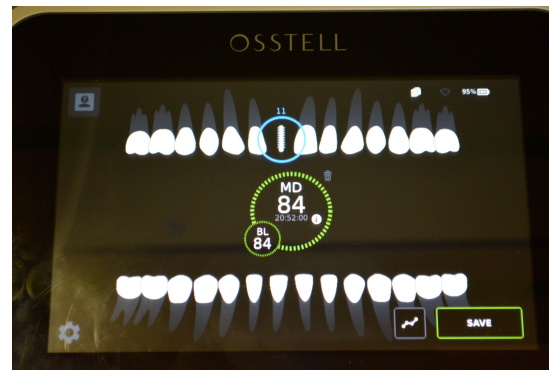


Fig. 7: Final Osstell reading

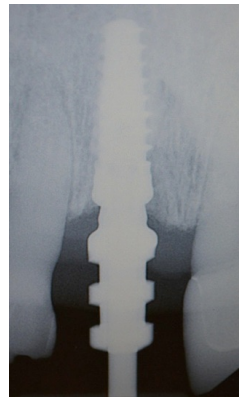


Fig. 8 Impression coping placed for start of restorative phase

Day PO	ISQ Reading
0	50
52	68
81	84

We were able to rehabilitate this patient in a total of 3 months and 1 week, rather than waiting a 4-month time period. We were also able to confidently assess not only the initial primary stability, but the ongoing rate of osseointegration. The restorative doctor can now restore with complete confidence that the implant will be ready to handle the loads associated with the final restoration.

Maxillary Central Incisor Implant Supported Crown



Brief Case Report - by Scott D. Ganz, DMD

A patient presented with a failing maxillary central incisor tooth post apicoectomy. The CBCT revealed that it would be difficult to gain stability for an immediate implant. The pre-operative periapical radiograph revealed issues with both the left central and lateral incisor teeth [FIGURE 1].

The pre-operative CBCT was accomplished with the “lift-lip” cotton-roll technique to separate the lip from the alveolus (cyan arrows) to better assess the buccal plate and extent of the vestibule [FIGURE 2]. A facial concavity was evident beyond the apex of the root, limiting the buccal-palatal width of available bone for implant placement.

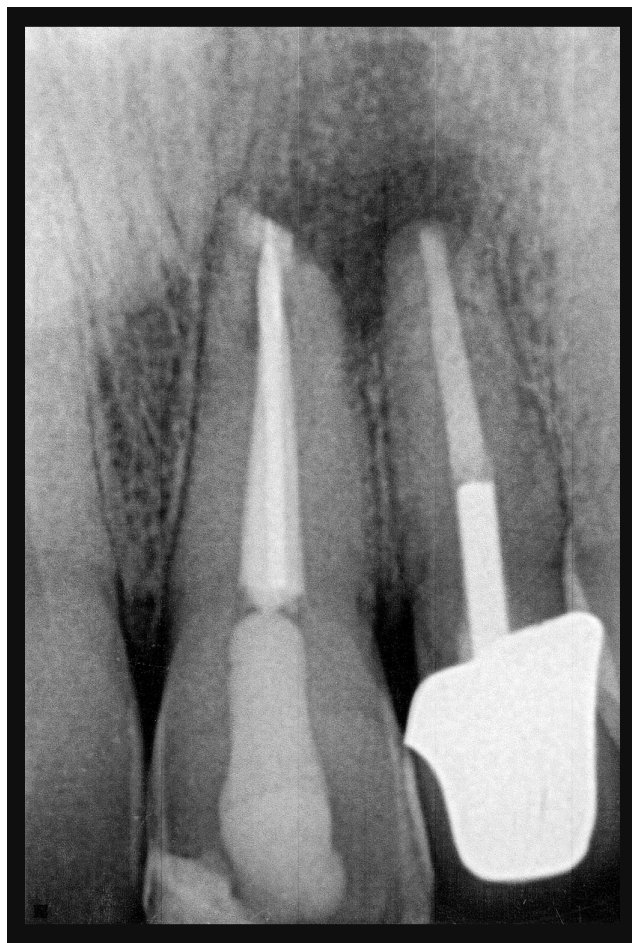


Figure 1. Pre-op periapical radiograph revealing failing central incisor tooth.

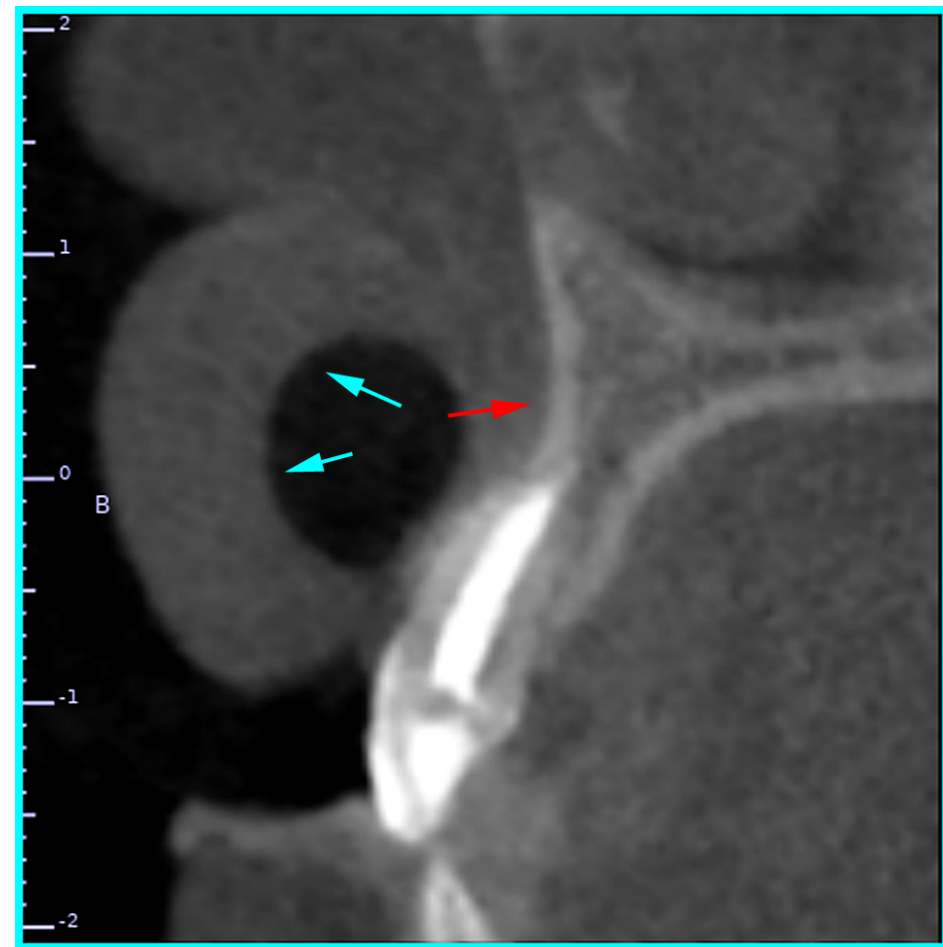

Figure 2. Pre-op CBCT illustrating the “lip-lift” technique (cyan arrows) to lift the lip off of the alveolar bone. The red arrow points to the concavity above the apex of the root.

Upon careful extraction and proper debridement, socket preservation and augmentation with corticocancellous bone was completed, along with an apicoectomy for the lateral incisor tooth. The area was allowed to heal for five months during which time the patient wore a removable partial denture.

At five months, the patient returned for implant placement (AnyRidge, Integrated Dental Systems (IDS) - MegaGen, Englewood Cliffs, NJ). As this was grafted bone it was important to have a subjective baseline for implant stability. The initial implant stability quotient (ISQ) was 68 [FIGURE 3]. It was then elected to bury the implant for two months until further integration was achieved.

The patient returned to uncover the implant at approximately 8 weeks. To assess the level of osseointegration, a secondary ISQ values were recorded at 76 buccal, and 76 palatally, indicating improved stability. The increase in ISQ provided the confidence for restorative loading with a transitional restoration fabricated to also assist in soft tissue maturation and emergence profile.

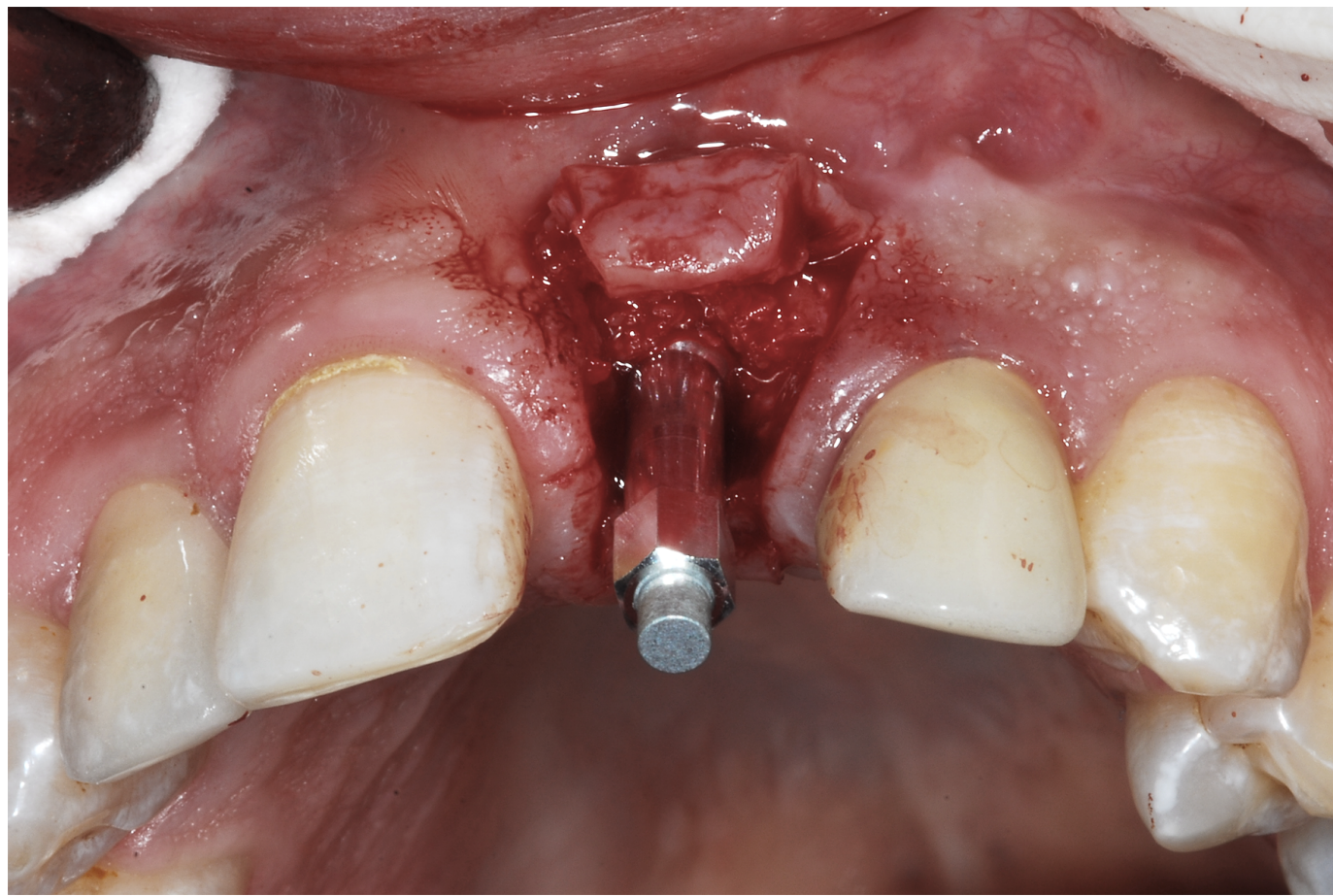


Figure 3. The SmartPeg ready for ISQ measurement after implant placement

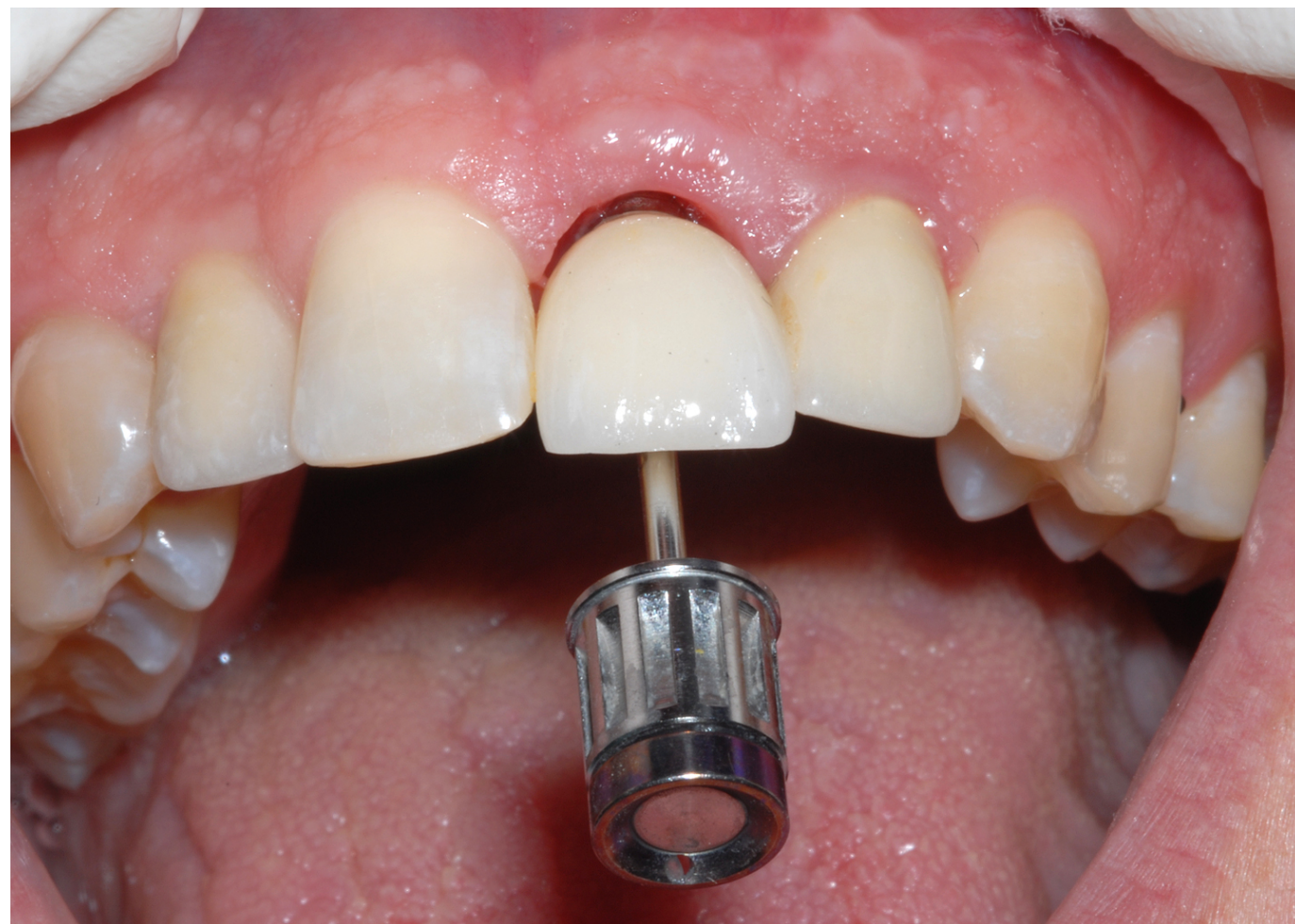

Figure 4a. The final screw-retained crown, illustrating good soft tissue emergence profile (Figure 4b).

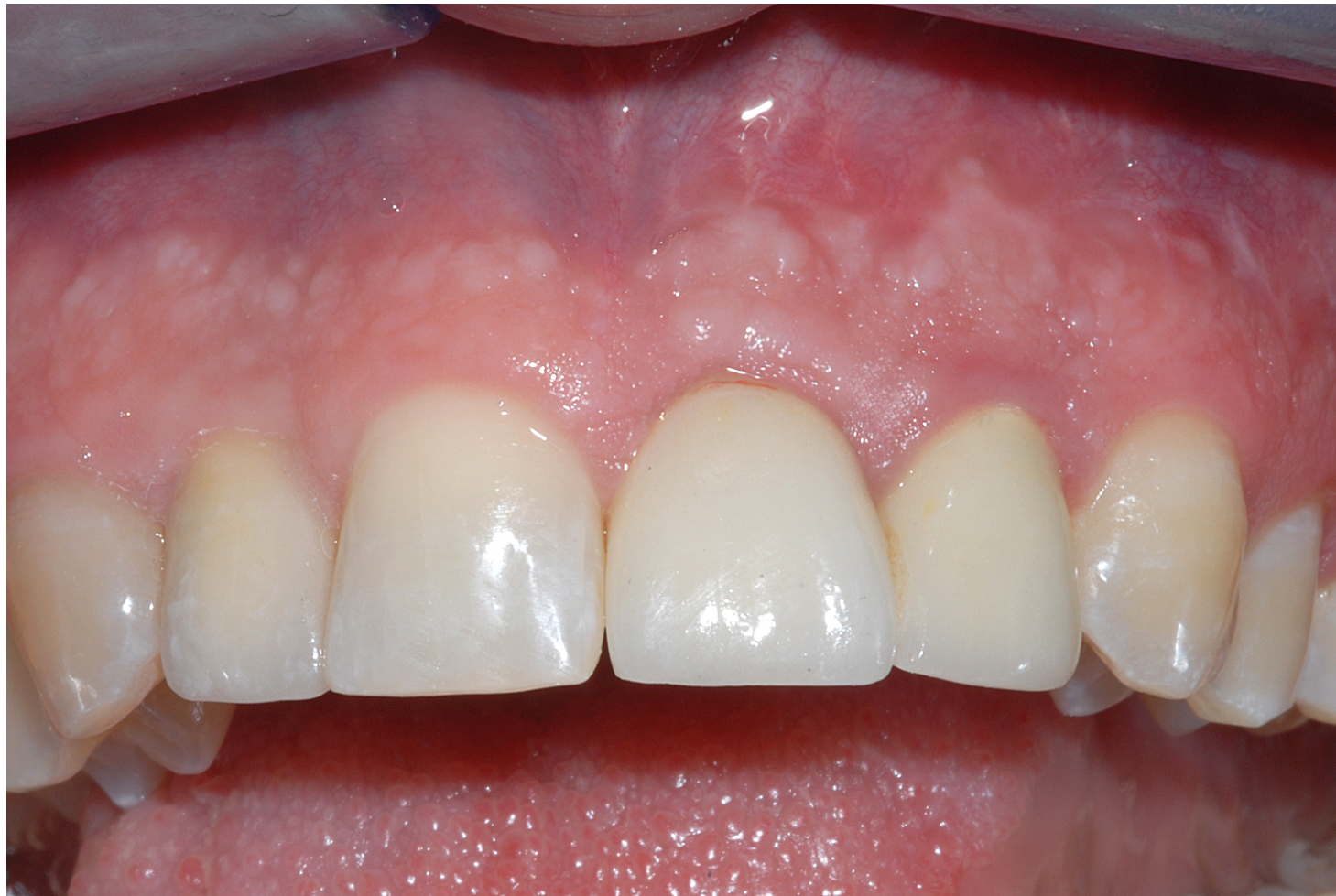

Figure 4.b.

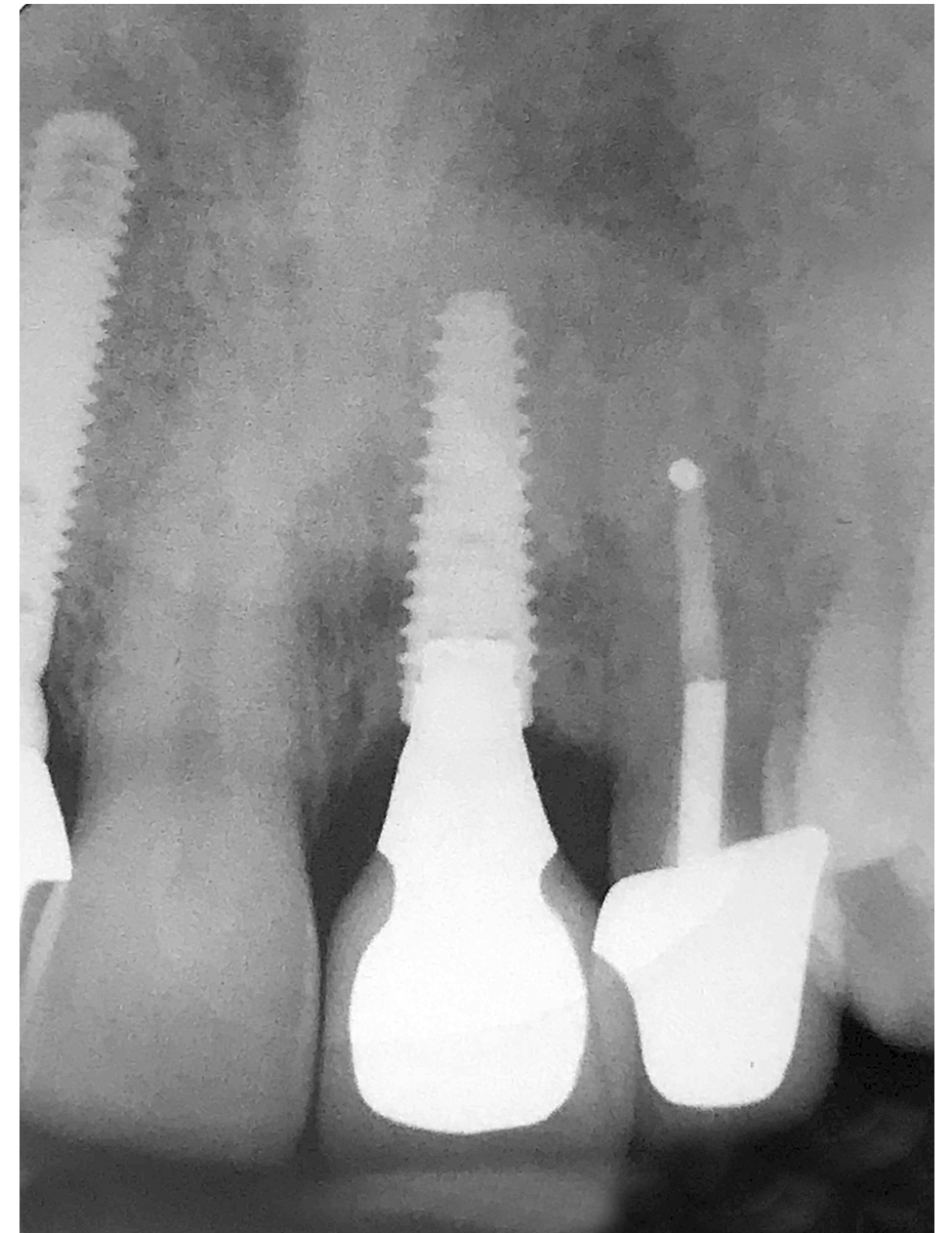


Figure 5. The final periapical radiograph reveals the interproximal levels of bone for the well-integrated implant.

The completion of the case proceeded successfully with a screw-retained prosthetic crown direct to the implant [FIGURES 4a & 4b]. The final periapical radiograph is seen in FIGURE 5. Note the similarities between shape of the natural right central incisor root and the tapered design of the AnyRidge implant, and a pre-existing implant for the right lateral incisor placed 14 years prior.

Clinical cases

HIGHLIGHTS

1. What is progressive loading.
2. When and to perform a progressive loading.

Progressive loading. What, when and how to perform it.



By Francisco Teixeira Barbosa.

DDS. T&E at Straumann

Private Practice, Barcelona, Spain.

Every day we do a lot of things based on our intuition. We make decisions based on our own or others experience.

We do not need science to help us in our daily life, and we don't have a clear indicator that shows us if our decision is the best.

Decisions based on practical experience is our way of life.

But when it comes to our profession as dentists, we do, or at least we should, evidence-based dentistry

for...almost every treatment we perform.

As the title of this chapter says, I'm going to present a case about "progressive loading."

And yes, progressive loading is supported by only a few clinical studies (Rotter 1996, Appleton 2005, Ghoweizi 2013), but -and here comes the interesting part- the rationale behind this concept makes sense from a clinical and biological point of view.

Some implants at the end of the osseointegration period have less than 25% of the overall surface in contact with the surrounding bone (Misch 1993).

Although they have a low BIC values, they are clinically stable. However, this stability may be lost in the medium or long term when the implant is loaded with the definitive restoration.

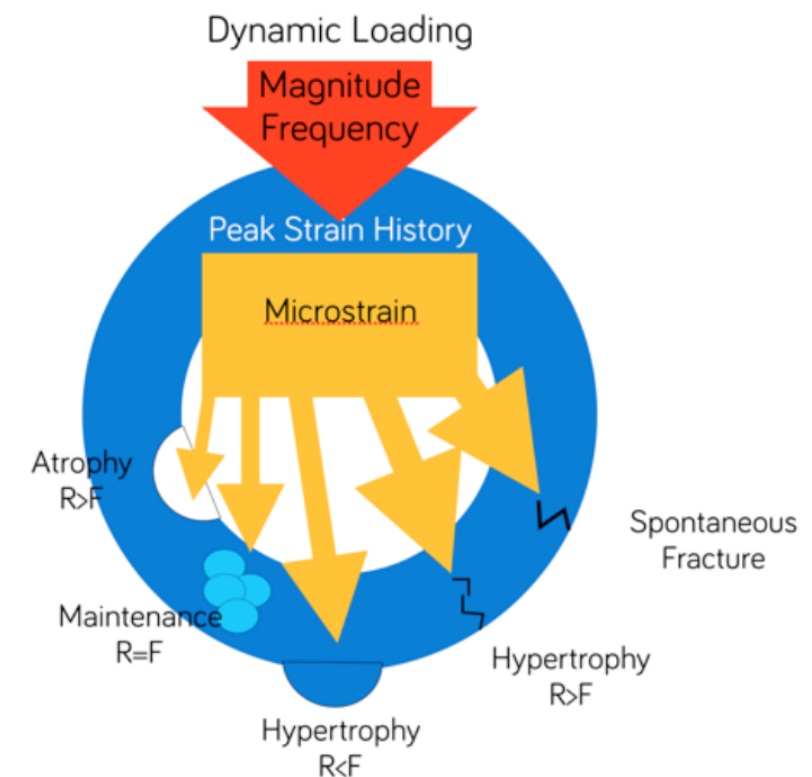
Problems are more likely to occur if the bone density around the implant is low and as we all know, poorest bone density is present in the posterior maxilla (Norton 2001) although there can be different bone density in various regions of the jaw (Parker 2008, Fuh 2010).

How to improve bone density around implants during the healing period?

At the moment no method exists that is clinically validated and predictable to augment bone density around an implant.

Regarding Frost's "mechanostat theory," the enhancement of bone density is a result of a dynamic relationship between loading and positive bone modeling response (Frost 1983, Frost 1987).

At this point, we can start introducing the concept of progressive loading:

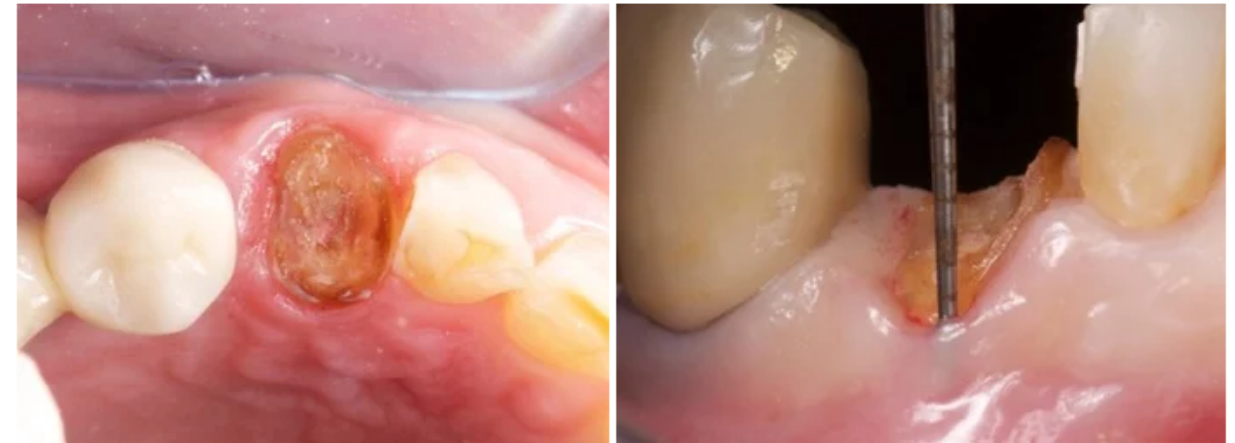

Applying forces gradually to the implant will allow a positive bone modeling response, increased peri-implant bone density which will allow the whole complex bone-implant-restoration to withstand occlusal load.

This is important mainly in the posterior maxilla where the bone quality is lower and biological complications are more likely to occur (Nevins 1993).

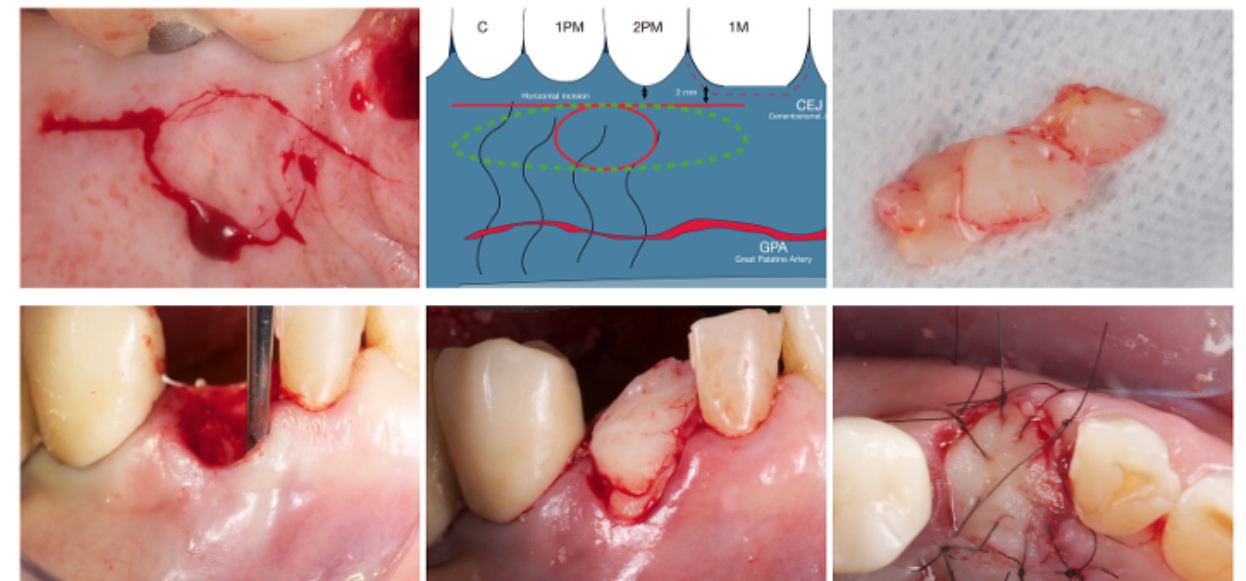
Clinical case:

A patient with a horizontal fracture of a canine. Good general health conditions, non-smoker.



Horizontal fracture of the upper canine. Socket Type I (Elia 2007).

After evaluation of the tooth remnant, we decided to carry out a ridge preservation with Bio-Oss® and close the socket with a combination epithelized-subepithelial connective tissue graft (Stimmelmayer 2010).

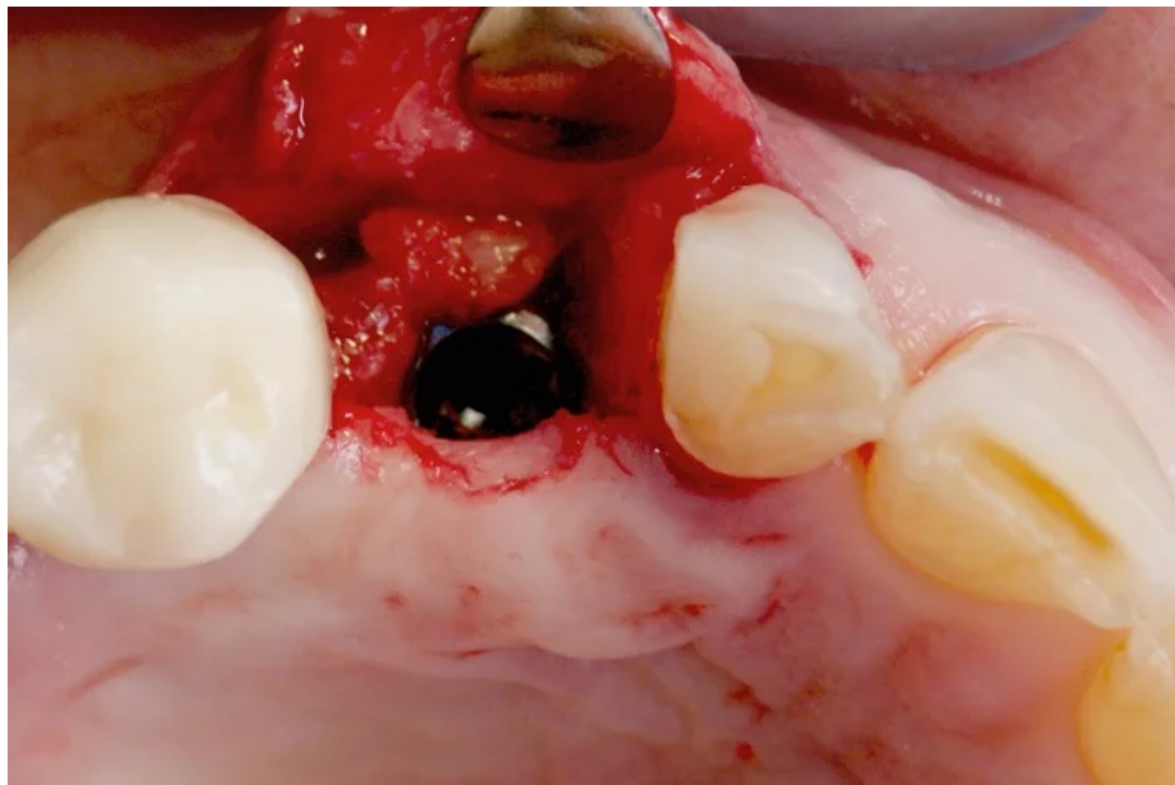

Stimmelmayer technique (Stimmelmayer 2010) is a recommended technique to perform an alveolar ridge preservation.

This combined technique has advantages over the free gingival graft (Landsberg 1994, Jung 2004):

- Reliable primary wound closure was provided after ridge preservation or immediate implant placement.
- The papillae of the neighboring teeth were supported.
- Displacement of the mucogingival junction was prevented.
- The labial and crestal soft tissue were thickened.
- Survival of the onlay component of the graft was ensured.

After waiting four months, the implant was placed in an ideal 3D position.




Implant placement in an ideal 3D position.

Lately, we are waiting no more than four months after a ridge preservation (De Risi 2013):

- There are no histological advantages in waiting more time. More information in this infographic.
- The implant can be engaged apically and meanwhile the osseointegration process is paired with the graft maturing process.

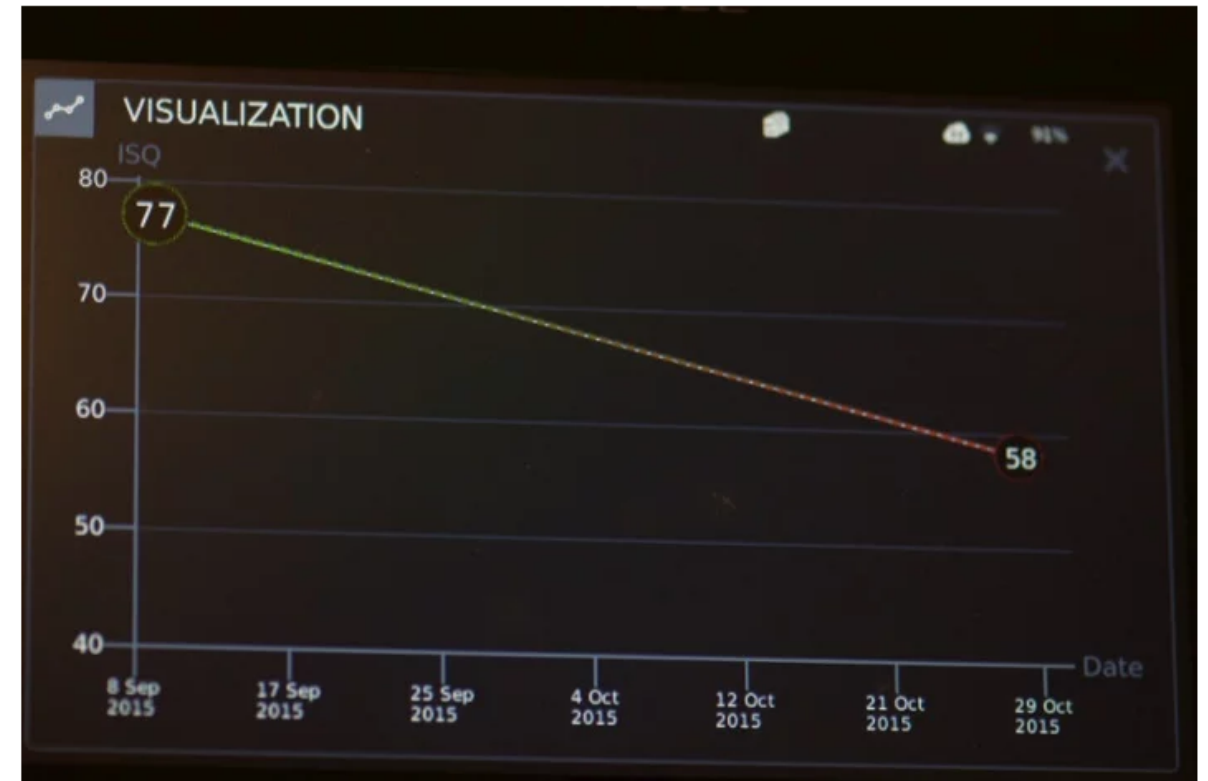After placing the implant, the ISQ value was 77 which is a high value even though it was placed in a grafted site (Zita 2017).



ISQ measurement at the implant placement.

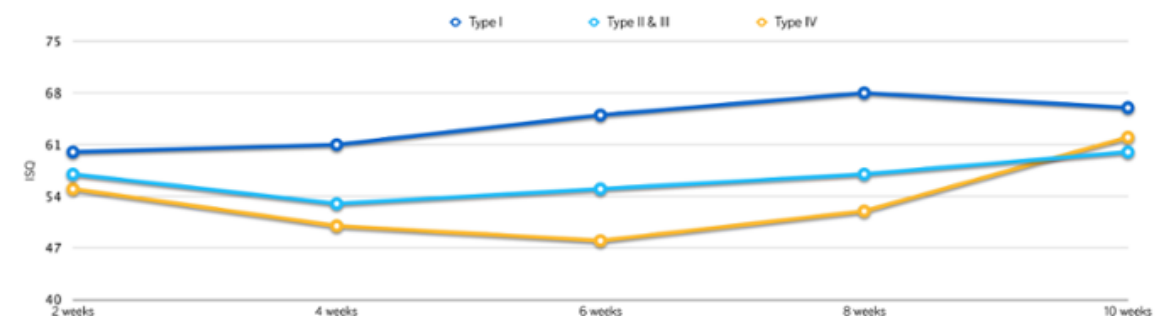
After one month and a half, the second surgery was performed, and again the ISQ was measured.

This time something unexpected was happening: The ISQ value had dropped almost 20 points, which is a sign that something is wrong.



ISQ dropdown.

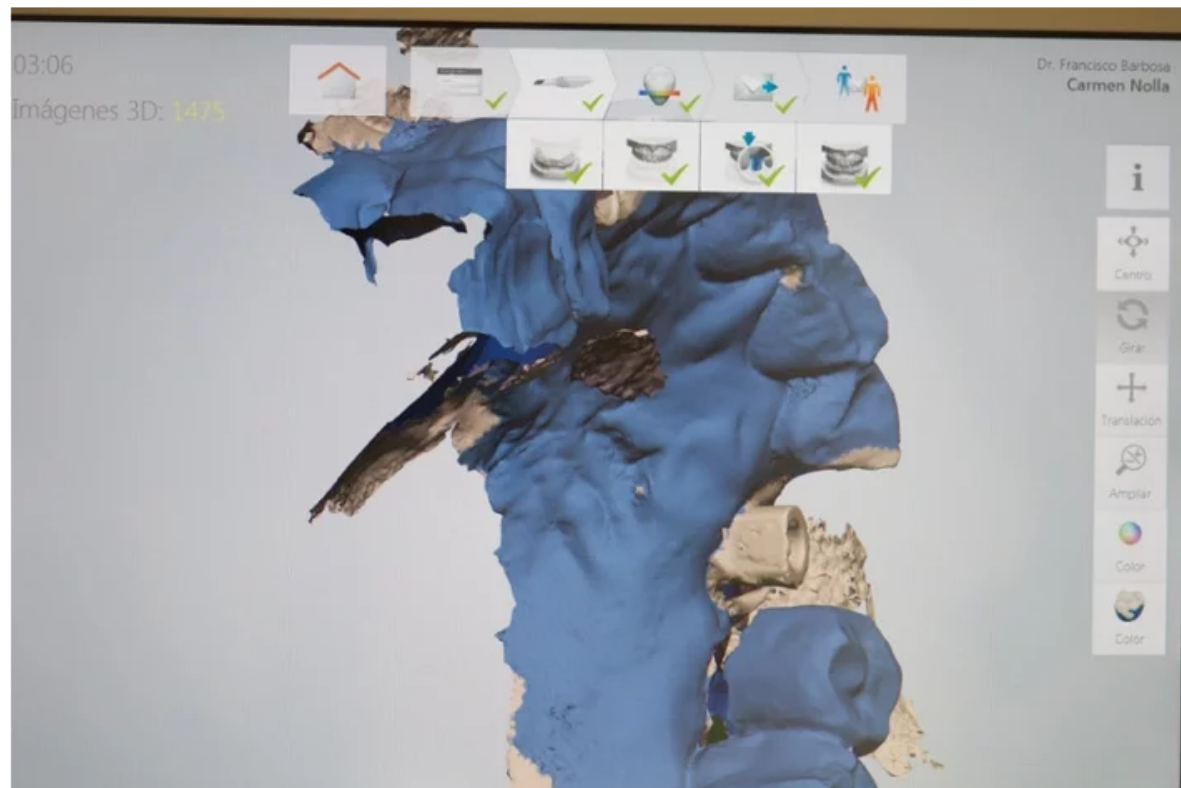There is always a variation in the ISQ during the osseointegration process, and values usually go down initially (first few weeks after implant placement), depending on the quality of the bone where the implant was placed (Barewall 2003).



Two decisions are possible here:

1. Remove the implant
2. Try a progressive loading in attempt to increase the ISQ value (from stimulating the bone remodeling).

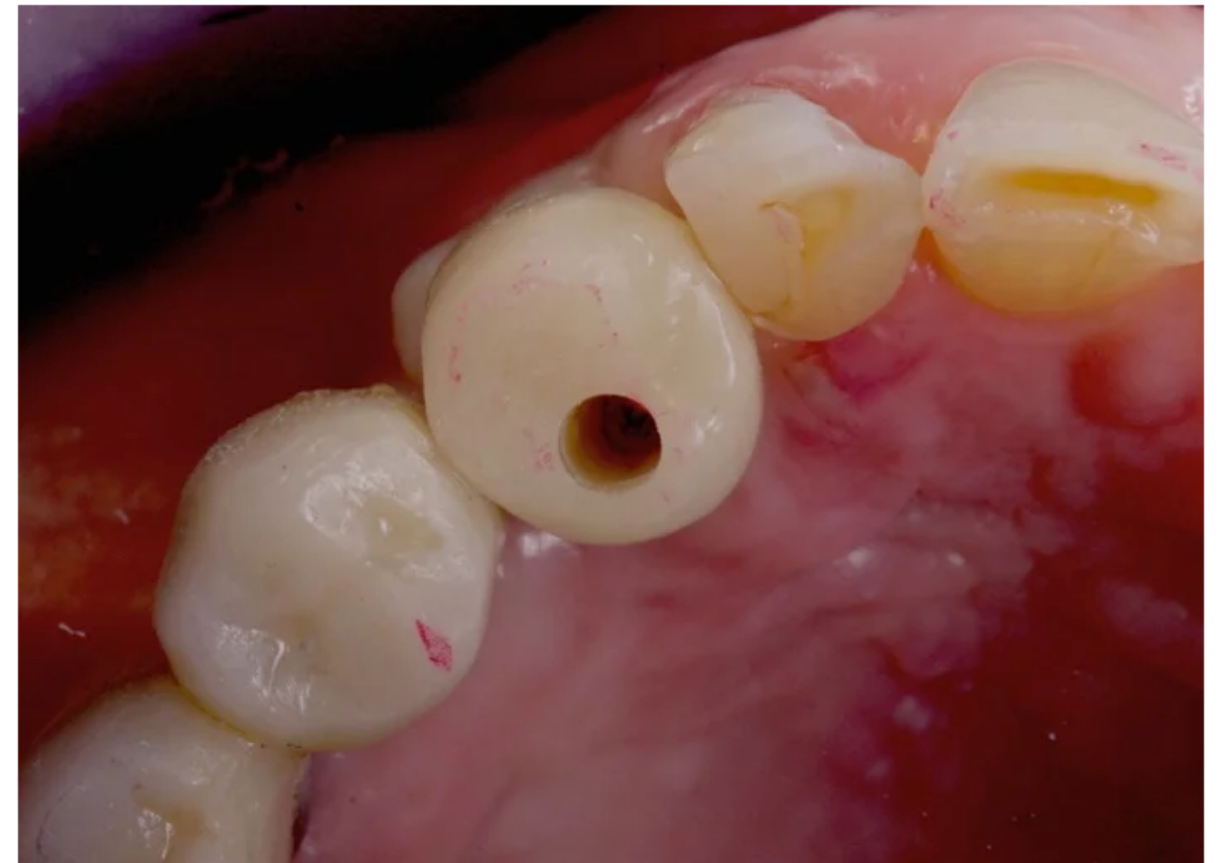
We decided to perform a digital impression with the 3Shape Trios 3 and order two PMMA provisional restorations designed and manufactured in CAD/CAM.



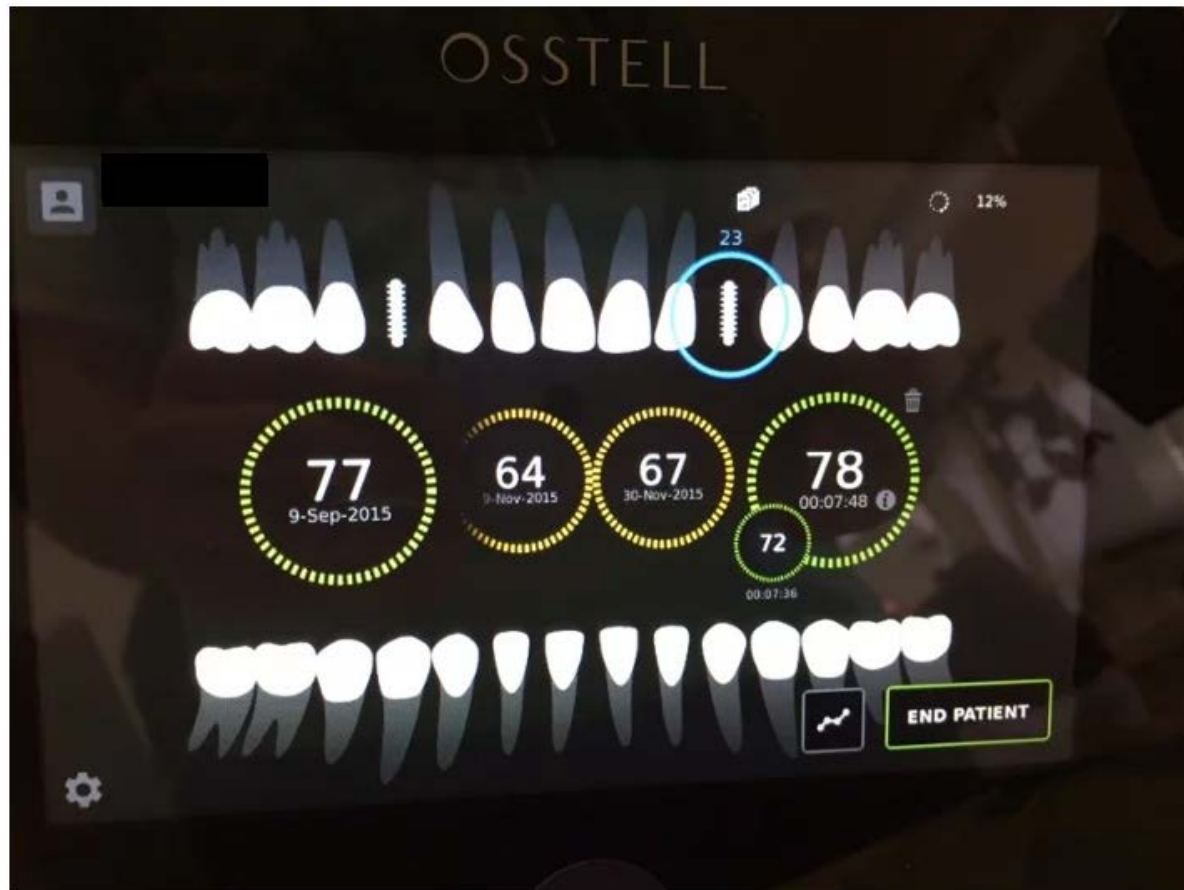Digital impression with Trios3. 3Shape.

Why two provisionals?

1) First, a provisional restoration was designed out of occlusion with the antagonist to observe if there was any ISQ value progression over time.



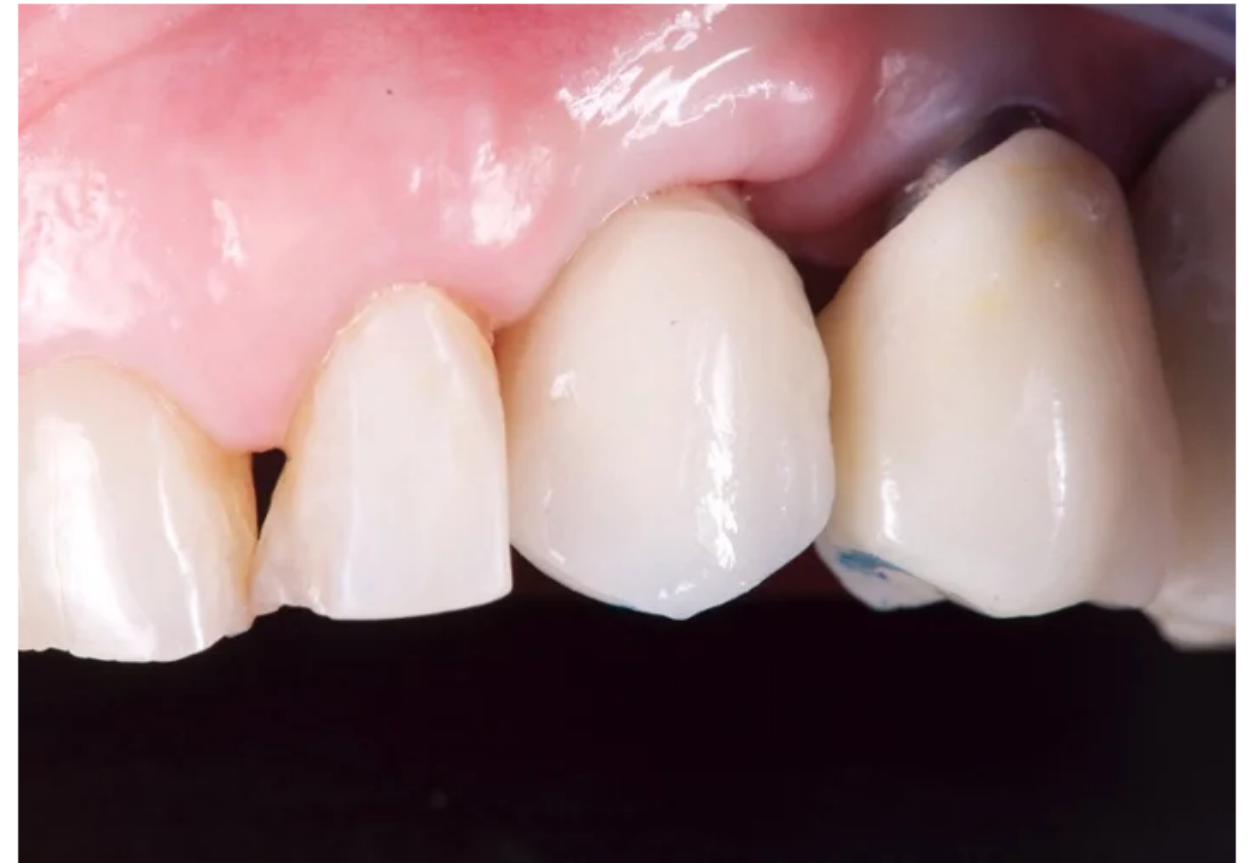2) If there was any improvement in the ISQ value, the initial provisional was then substituted with a functional provisional.



After one month, the ISQ value was up almost 10 points, and we decided to deliver the second provisional with functional contact.

Three months after the second provisional was delivered, the ISQ value was already up to 70 ISQ, and we decided to perform the definitive restoration.

It is not a beautiful outcome, but the patient accepted the definitive aesthetic result and the restoration were screw-retained with a torque of 35 NCm.



Conclusions

Although the limitations of this short case report, we conclude that using ISQ measurements (RFA) to monitor bone remodeling before delivering a definitive restoration can improve the survival rate of the global rehabilitation.

The uncertainty of the BIC (bone implant contact) between the implant and the bone and also the resistance of the implant to the micromovement at the time of the definitive loading, justifies the use of the ISQ measurement to monitor the implant behavior during osseointegration.

It was also proved that the Osstell® ISQ might also indicate information about the bone density around an implant, which can be of great value in the posterior maxilla (Manresa 2013).

Of course, a lot of questions are left to answer yet, like:

- If the ISQ value has no relation with the BIC (Abrahamsson 2009), why is it still of great value to make clinical decisions in cases where we are not sure to load the fixture?
- If the ISQ has a no direct relation with the BIC, why do values improve overtime when we perform a progressive loading?
- Should ISQ be mandatory in cases where patients have non-optimal general health conditions (diabetes, osteoporosis) or smokers?
- Should provisionalization be mandatory in cases after a guided bone regeneration?

EPILOGUE

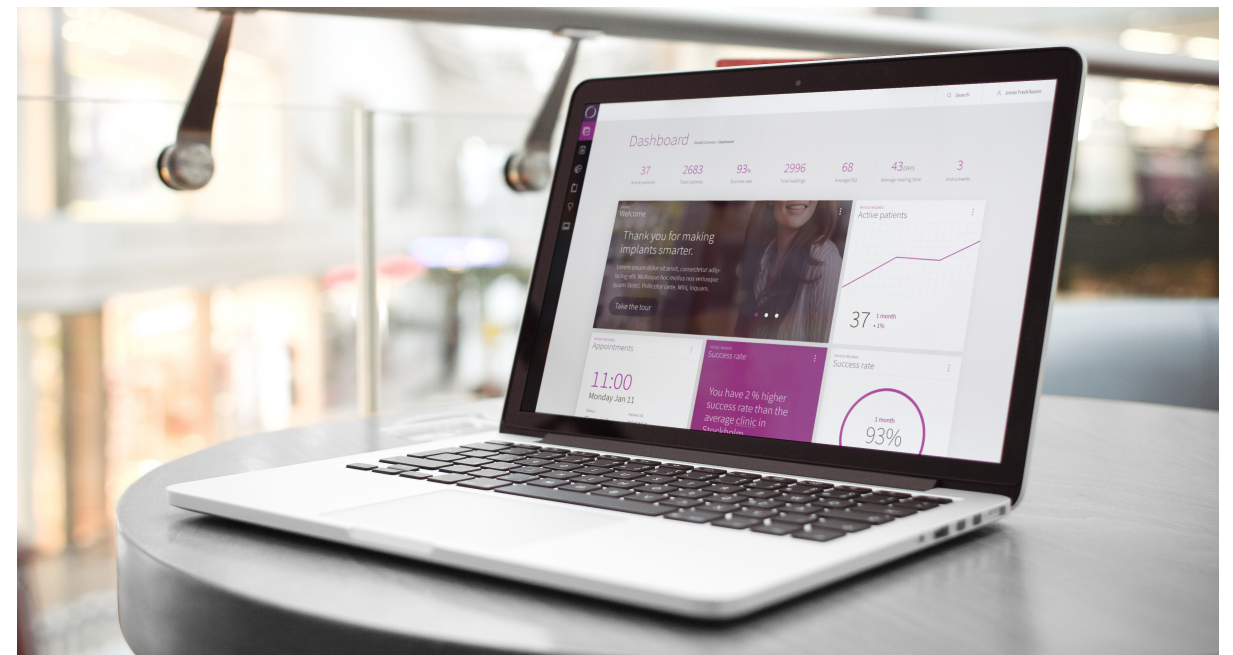What's next

What if you – a busy dentist year 2021 - have fingertip access to:

- Confidence based on >500 000 implant stability measurements
- from 300 000 implants placed
- in 250 000 anonymized patients with different attributes
- From 10 000 peers around the world

What could that do for you?

Osstell Connect data is your new tool. It provides relevant insights of your daily implant treatment performance.



Bibliography



ISQ Scale References

Jahre Erfahrung mit der Resonanzfrequenzanalyse

Sennerby L Prof, Sahlgrenska Academy, University of Gothenburg, Sweden

Implantologie 2013;21(1):21-33 (In German)

Translated from German “It is likely that ISQ measurements can be used as one additional parameter for diagnosis of implant stability

and decision-making during implant treatment and follow-up. The threshold values are the present author’s own somewhat conservative suggestions based on own experience and other values may be relevant for other clinicians and implant designs. The green zone contains “safe” implants showing primary ISQ values from, for instance 70 and above. The red zone contains “questionable” implants with an ISQ value below for instance 55. The yellow zone represents implants with an ISQ from 55 to 70”.

Immediate vs. early loading of SLA implants in the posterior mandible: 5-year results of randomized controlled clinical trial.

Kokovic V, Jung R, Feloutzis A, Todorovic V, Jurisic M, Hämmerle C
Clinical Oral Implants Research, 00, 2013, 1-6

After 5 years, survival in the both groups was 100 %. The mean value of primary implant stability was $76,92 \pm 0,79$ ISQ. In the first 6 weeks, ISQ values significantly increased in the test group as well as in the control group. Based on these results, the self-tapping implants inserted in posterior mandible can provide adequate primary stability value as the main factor for immediate and early loading protocol.

Early Loading of Nonsubmerged Titanium Implants with a Chemically Modified Sand-Blasted and Acid-Etched Surface:
6-Month Results of a Prospective Case Series Study

in the Posterior Mandible Focusing on Peri-Implant Crestal Bone Changes and Implant Stability Quotient (ISQ) Values

Michael M. Bornstein, Dr. med. dent.; Christopher N. Hart, DMD;
Sandro A. Halbritter, Dr. med. dent.; Dean Morton, BDS, MS;† Daniel
Buser, Prof. Dr. med. dent.

Clin Implant Dent Relat Res 2009

If the ISQ value at day to load is < 65, an additional healing period is recommended, and the ISQ values is measured again 3 weeks later until the required level is reached. This approach is practical and well understood by patients. (Prof. Daniel Buser prefers ≥ 70 ISQ, single teeth, early loading/Straumann, otherwise add three weeks, according to an oral presentation given at the Osstell Scientific Symposium in connection to the of the EAO 2010.)

The Predictive Value of Resonance Frequency Analysis in the Surgical Placement and Loading of Endosseus Implants

Serge Baltayan, Joan Pi-Anfruns, Tara Aghaloo, Peter Moy J Oral
Maxillofac Surg 74:1145-1152, 2016

One-stage placement of implants with ISQ values greater than 66 can be performed. Implants with ISQ values less than or equal to 66 should be placed using the two-stage protocol, which shows a higher survival rate. The computed ISQ = 66 cut-off value used to select between one-stage and two-stage placement is validated in this study. Moreover, early loading of implants with ISQ values greater

than 64 can be performed. Implants with ISQ values less than 64 should utilize traditional loading, which shows a higher survival rate. The computed ISQ = 64 cut-off value used to select between early and traditional loading is validated in this study. Higher ISQ values at osseointegration correlate with higher survival rates.

Direct Loading of Implants

Pär-Olov Östman DDS, PhD, MD, Private practitioner, Falun- and
Biomaterial group, Sahlgrenska
Academy, Gothenburg – Tandläkartidningen årg 100 nr 3, 2008

20 consecutive patients with totally edentulous maxillas were included in the study. The criteria for direct loading was insertion torque 30 Ncm and an ISQ > 60 on the most posterior implants and a sum of 200 ISQ (average 50 ISQ) on the 4 anterior implants. The overall conclusion with the thesis is that dental implants can be direct loaded with a good result if high primary stability can be obtained and if a stable provisional bridge with good occlusion is splinting the implants.

Diagnosis of Implant Stability and its Impact on Implant Survival: A Prospective Case Series Study

Daniel Rodrigo, Luis Aracil, Conchita Martin, Mariano

Sanz
Clin. Oral Impl. Res. 21, 2010; 255-261

The evaluation of RFA values to assess implant secondary stability (Osstell 2) demonstrated a statistically significant correlation with implant outcome. In fact, no implant with ISQ > 60 failed, while 19 % of implants with ISQ < 60 failed.

The relationship between resonance frequency analysis (RFA) and lateral displacement of dental implants: An in vitro study

Pagliani L, Sennerby L, Petersson A, Verrocchi D, Volpe S & Andersson P
Journal of Oral Rehabilitation 2012

Both RFA and displacement measurements correlated with bone density. It is concluded that RFA measurements reflect the micromobility of dental implants, which in turn is determined by the bone density at the implant site. The correlation between ISQ and micron was non-linear and micro motion was reduced with app. 50 % from 60 ISQ to 70 ISQ.

Implant Stability Quotient (ISQ) vs Direct in Vitro Measurement of Primary Stability (Micromotion): Effect of Bone Density and Insertion Torque

Paolo Trisi PhD, Teocrito Carlesi DDS, Marco Colagiovanni DDS,
Giorgio Perfetti MD, DDS
Journal of Osteology and Biomaterials, Volume 1, Number 3, 2010

Results showed a high dependence between the observed micromotion and the ISQ values, indicating that micromotion decreased with increasing ISQ values. An in vitro study and the results cannot be directly transferred to clinical applications.

Early loading of titanium dental implants with an intra-operatively conditioned hydrophilic implant surface after 21 days of healing.

Stefan Paul Hicklin, Esther Schneebeli, Vivianne Chappuis, Simone Francesco Marco Janner, Daniel Buser, Urs Brägger Clin. Oral Impl. Res 00, 2015; 1-9

Functional occlusal loading of implants with a hydrophilic, moderately rough endosseal surface and ISQ values > 70 three weeks after placement, appears to be a safe and predictable treatment option in healed sites in the posterior mandible without need of bone augmentation procedures.

References

Al-Nawas B, Groetz KA, Brahm R, Wagner W.
Resonance-frequency-analysis in the healing and loading period of dental implants. J Dent Res 2002 IADR abstract 1027.

Albrektsson T, Sennerby L. Einphasiges Implantatverfahren und Sofortbelastung von Implantaten. *Implantologie* 2000;2:145-160.

Barewal R M, Oates T Meredith N, Cochran D L. Resonance Frequency Measurement of Implant Stability In Vivo on Implants with a Sandblasted and Acid-Etched Surface, *Journal of Oral & Maxillofacial Implants*, 2003, vol 18, 641-651.

Bischof M, Nedir R, Szmukler-Moncler S, Bernard JP, Samson J. Implant stability measurement of delayed and immediately loaded implants during healing. *Clin Oral Implants Res*. 2004;15:529-39.

Bornstein, Michael. et. al. Early loading of Nonsubmerged Titanium Implants with Chemically Modified Sand-Blasted and Acid-Etched Surface: 6-Month Results of a Prospective Case Series Study in the Posterior Mandible Focusing on Peri-Implant Crestal Bone Changes and Implant Stability Quotient (ISQ) Values. *Clinical Implant Dentistry and Related Research*, 2009. in press

Calandriello R, Tomatis M, Rangert B. Immediate functional loading of Brånemark System® implants with enhanced initial stability: A prospective 1 to 2 year clinical and radiographic study. *Clin Implant Dent Relat Res* 2003;5 supp1:10-20

Cawley P, Pavlakovic B, Alleyne D.N, George R, Back T, Meredith N. The design of a vibration transducer to monitor the integrity of dental implants. *Proc Instn Mech Engrs [H]* 1998;212(4):265-272.

Cornellini R, Cangini F, Covani U, Barone A, Buser D. Immediate Loading of Implants with 3-unit Fixed Partial Dentures: A 12-month Clinical Study. *Journal of Oral & Maxillofacial Implants*, 2006, vol 21, 914-918.

Degidi M, MD, DDS; Daprile G, DMD; Piattelli A, Primary stability determination: operating surgeon's perception and objective measurement. *Int J Oral Maxillofac Surg*. 2009 in press

Degidi M, MD, DDS; Daprile G, DMD;† Piattelli A, MD, DDS; Carinci F, MD, DDS\$ Evaluation of Factors Influencing Resonance Frequency Analysis Values, at Insertion Surgery, of Implants Placed in Sinus-Augmented and Nongrafted Sites. *Clin Implant Dent Relat Res* 2007;9:144-149

Esposito M, Hirsch JM, Lekholm U, Thomsen P. Biological factors contributing to failures of osseointegrated oral implants. I. Success criteria and epidemiology. *Eur J Oral Sci* 1998;106:721-764.

Friberg B, Sennerby L, Meredith N, Lekholm U. A comparison between cutting torque and resonance frequency measurements of maxillary implants. A 20-month clinical study. *Int J Oral Maxillofac Surg* 1999;28(4):297-303.

Friberg B. On bone quality and implant stability measurements. PhD thesis. University of Gothenburg, Sweden, 1999.

Friberg B, Sennerby L, Linden B, Gröndahl K, Lekholm U. Stability measurements of one-stage Brånemark implants during healing in mandibles. A clinical resonance

frequency analysis study. Int J Oral Maxillofac Surg 1999;28(4): 266-272.

Glauser R, Meredith N. Diagnostische Möglichkeiten zur Evaluation der Implantatstabilität. Implantologie 2001;9(2): 147-160.

Glauser R, Lundgren AK, Gottlow J, Sennerby L, Portmann M, Ruhstaller P, Hämmerle CH. Immediate occlusal loading of Brånemark TiUnite implants placed predominantly in soft bone: 1-year results of a prospective clinical study. Clin Implant Dent Relat Res. 2003;5 Suppl 1:47-56.

Glauser R, Portmann M, Ruhstaller P, Gottlow J, Schärer P. Initial implant stability using different implant designs and surgical techniques. A comparative clinical study using insertion torque and resonance frequency analysis. Applied Osseointegration Research 2001;2(1):6-8.

Glauser R, Sennerby L, Meredith N, Ree A, Lundgren A, Gottlow J, Hammerle CH. Resonance frequency analysis of implants subjected to immediate or early functional occlusal loading. Successful vs. failing implants. Clin Oral Implants Res. 2004;15:428-34.

Glauser R, Portmann M, Ruhstaller P, Lundgren AK, Hämmerle CHF, Gottlow J. Stability measurements of immediately loaded machined and oxidized implants in the posterior maxilla. A comparative clinical study using resonance frequency analysis. Applied Osseointegration Research 2001;2(1):27-29.

Hallgren C, Reimers H, Gold J, Wennerberg A. The importance of surface texture for bone integration of screw shaped implants: an in vivo study of implants patterned by photolithography. J Biomed Mater Res 2001 Dec 15;57(4): 485-496.

Hart C, Buser D. Use of Resonance Frequency Analysis to Optimize Implant Therapy. Starget 2006, no 4.

Heo S.J, Sennerby L, Odersjö M, Granström G, Tjellström A, Meredith N. Stability measurements of craniofacial implants by means of resonance frequency analysis. A clinical pilot study. The J of Laryngology and Otology 1998;112(6):537-542.

Ivanoff CJ, Sennerby L, Lekholm U. Reintegration of mobilized titanium implants. An experimental study in rabbit tibia. Int J Oral Maxillofac Surg. 1997;26:310-5.

Jimenez, Damian R.; Shah, K. C.; El-Ghareeb, Moustafa; Aghaloo, Tara; Pi-Anfruns, Joan; Hameed, Sabeena; Chiang, J.; Judge, N.; Ivry, B.; Wakimoto, M.; Moy, Peter K,. Use of Osstell® for determination of implant staging and loading protocols to improve implant success rates Poster presentation, Academy of Osseointegration 2009.

Keen D S, Jovanovic S, Bernard W, Primary Implant Stability Diagnostics with Resonance Frequency Analysis. Poster EAOVienna 2003.

Kuchler U, Chappuis V, Bornstein MM, Siewczyk M, Gruber R, Maestre L, Buser D. Development of Implant Stability Quotient values of implants placed with simultaneous sinus

floor elevation – results of a prospective study with 109 implants. Clin. Oral Impl. Res. 00, 2016, 1–7. doi: 10.1111/clr.12768.

Levin BP, The Dermal Apron Technique for Immediate Implant Socket Management: A Novel Technique. J Esthet Restor Dent. 2016 Jan-Feb;28(1):18-28.

Levin, BP The Correlation Between Immediate Implant Insertion Torque and Implant Stability Quotient. Int J Periodontics Restorative Dent. 2016 Nov/Dec;36(6):833-840. doi: 10.11607/prd.2865.

Levin BP, Chu SJ. Changes in Peri-implant Soft Tissue Thickness with Bone Grafting and Dermis Allograft: A Case Series of 15 Consecutive Patients. Int J Periodontics Restorative Dent. 2018 Sep/Oct;38(5):719-727.

Meredith N. A review of nondestructive test methods and their application to measure the stability and osseointegration of bone anchored endosseous implants. Crit Rev Biomed Eng 1998;26(4):275-291.

Meredith N. Assessment of implant stability as a prognostic determinant. Int J Prosthodont 1998;11(5):491-501.

Meredith N, Rasmussen L, Sennerby L, Alleyne D. Mapping implant stability by resonance frequency analysis. Med Sci Res 1996;24:191-193.

Meredith N. On the clinical measurement of implant stability and osseointegration. PhD thesis, University of Gothenburg, Sweden, 1997.

Meredith N, Book K, Friberg B, Jemt T, Sennerby L. Resonance frequency measurements of implant stability in vivo. A cross-sectional and longitudinal study of resonance frequency measurements on implants in the edentulous and partially dentate maxilla. Clin Oral Impl Res 1997;8:226-233.

Meredith N, Shagaldi F, Alleyne D, Sennerby L, Cawley P. The application of resonance frequency measurements to study the stability of titanium implants during healing in the rabbit tibia. Clin Oral Implants Res 1997;8(3):234-243

Meredith N. J. The application of modal vibration analysis to study bone healing in vivo. Dent Res 994;73(4):793.

Meredith N, Alleyne D, Cawley P. Quantitative determination of the stability of the implant-tissue interface using resonance frequency analysis. Clin Oral Implants Res 1996; 7: 261-267.

Nedir R, Bischof M, Szmukler-Moncler S, Bernard JP, Samson J. Predicting osseointegration by means of implant primary stability. Clin Oral Implants Res. 2004;15:520-8.

O’Sullivan D, Sennerby L and Meredith N. Measurements comparing the initial stability of five designs of dental implants: A human cadaver study. Clin Impl Dent Rel Res 2000;2:85-92.

Payer M, Kirmeier R, Jakse N, Pertl C, Wegscheider W, Lorenzoni M. Surgical factors influencing mesiodistal implant angulation. Clin Oral Implants Res. 2008 Mar;19(3):265-70.

Pessoa T. A comparison between cutting torque and resonance frequency measurements of mandibular implants. J Dent Res 2002 IADR abstract 3565.

Rasmusson. L, Meredith N, Kahnberg K-E, Sennerby L. Effects of barrier membranes on bone resorption and implant healing in onlay bone grafts. An experimental study. Clin Oral Impl Res. 1999;10:267-277.

Rasmusson L, Kahnberg KE, Tan A. Effects of implant design and surface on bone regeneration and implant stability:

an experimental study in the dog mandible. Clin Implant Dent Relat Res 2001;3(1):2-8.

Rasmusson L, Stegersjö G, Kahnberg K-E, Sennerby L. Implant stability measurements using resonance frequency analysis in the grafted maxilla. A cross-sectional pilot study. Clin Impl Dent Rel Res 1999;1:70-74.

Rasmusson L, Meredith N, Sennerby L. Measurements of stability changes of titanium implants with exposed threads subjected to barrier membrane induced bone augmentation. An experimental study in the rabbit tibia. Clin Oral Impl Res 1997;8:316-322.

Rasmusson L. On implant integration in membrane-induced and grafted bone. PhD thesis. University of Gothenburg, Sweden. 1998.

Rasmusson L, Meredith N, Kahnberg K-E, Sennerby L. Stability assessments and histology of titanium implants placed simultaneously with autogenous onlay bone in the rabbit tibia. Int J Oral Maxillofac Surg 1998 Jun;27(3): 229-235.

Rasmusson L, Meredith N, Cho I.H, Sennerby L. The influence of simultaneous versus delayed placement on the stability of titanium implants in onlay bone grafts. A histologic and biomechanic study in the rabbit. Int. J. Oral Maxillofac Surg 1999; 28:224-231.

Rompen E, DaSilva D, Hockers T, Lundgren A-K, Gottlow J, Glauser R, Sennerby L. Influence of implant design on primary fit and stability. A

RFA and histological comparison of MkIII and MkIV Brånemark implants in the dog mandible. Applied Osseointegration Research 2001;2(1):9-11.

Schubert S, Schubert T. Evaluation of implant stability by resonance frequency analysis. Starget 1.2003.

Sennerby L, Meredith N. Analisi della Frequenza di Risonanza (RFA). Osteointegrazione e carico immediato 2002;19-32.

Sennerby L, Meredith N. Implant stability measurements using resonance frequency analysis: biological and biomechanical aspects and clinical implications. Periodontology 2000, Vol. 47, 2008, 51–66.

Sennerby L, Meredith N. Resonance frequency analysis: measuring implant stability and osseointegration. Compend Contin Educ Dent. 1998;19:493-8, 500, 502; quiz 504.

Sjöström M, Sennerby L, Nilson H, Lundgren S. Reconstruction of the atrophic edentulous maxilla with free iliac crest grafts and implants: a 3-year report of a prospective clinical study. Clin Implant Dent Relat Res. 2007;9:46-59.

Stenport VF, Olsson B, Morberg P, Tornell J, Johansson CB. Systemically administered human growth hormone improves initial implant stability: an experimental study in the rabbit. Clin Implant Dent Relat Res 2001;3(3):135-141.

Sullivan DY, Sherwood RL, Collins TA, Krogh PH. The reverse-torque test: a clinical report. Int J Oral

Maxillofac Implants. 1996;11:179-85.

*Ting-Jen Ji, Joseph Y. K. Kan, Kitichai Rungcharassaeng, Phillip Roe, Jaime L. Lozada, Immediate Loading of Maxillary and Mandibular Implant-Supported Fixed Complete Dentures: A 1- to 10-Year Retrospective Study, Journal of Oral Implantology. 2012;38(S1):469-477.

Valderrama P, Oates T, Jones A, Simpson J, Schoolfield J, Cochran D. Evaluation of Two Different Resonance Frequency Devices to Detect Implant Stability: A Clinical Trial. Journal of Periodontics. 2007, Vol 78, 262-272.

Östman PO, Hellman M, Sennerby L. Direct implant loading in the edentulous maxilla using a bone density-adapted surgical protocol and primary implant stability criteria for inclusion. Clin Implant Dent Relat Res. 2005;7 Suppl 1:S60-9.

Östman P O, Hellman M, Sennerby L, Teeth now – A concept for immediate prosthetic rehabilitation. Poster San Diego 2003.

Immediate loading of maxillary and mandibular implant-supported fixed complete dentures: a 1- to 10-year retrospective study." J Oral Implantol. 2012 Sep

More than 900 articles about ISQ have been published so far, and the number is constantly growing. For more articles about ISQ visit <https://www.osstell.com/scientific-database/>

About Osstell

Osstell is the global leader in implant stability measurement and osseointegration progress monitoring. Osstell was formed in 1999 to commercialize an invention using Resonance Frequency Analysis (RFA) to determine the clinical status of a dental implant.

Osstell's proprietary and patented technology helps its customers, dentists around the world, to make dental implant treatments safer, and to increase patient confidence and comfort, by measuring the stability of implants objectively and non-invasively using the ISQ scale (Implant Stability Quotient). More than 900 scientific publications confirm the benefits of the technology, its clinical value, and the use of the ISQ scale for dentists in their daily practices. Osstell is headquartered in Gothenburg, Sweden – the birthplace of dental implants.

Since 2018, Osstell is part of the W&H Group.

Contributors



Francisco Teixeira Barbosa. DDS.

Francisco Teixeira Barbosa graduated from the University Alfonso X El Sabio, Madrid, Spain in 2004. Moved his practice to Barcelona where he continued his education at Escuela Superior de Implantologia in Barcelona and as a Dentist at the Maxillofacial department of Hospital del Mar at Barcelona. At the same time, he started his private practice in Barcelona and also finished his degree in Advanced Oral Implantology at Loma Linda University, LA, California, USA. Graduated with an MBA at ESADE Business School and Periospot founder. Specialized in digital and implant dentistry.



Scott D. Ganz, DMD

Dr. Scott Ganz is one of the world's leading experts in the field of computer utilization for diagnostic, graphical, treatment planning, and CAD/CAM applications in dentistry. A much sought-after speaker, he delivers presentations both nationally and internationally on the prosthetic and surgical phases of implant dentistry. Dr. Ganz is widely published, with more than 100 articles in scientific and 14 professional textbooks and journals. He currently serves as editor-in-chief for Cone Beam, International Magazine of Cone Beam Dentistry, and an associate editor for the peer-reviewed journal of the International Congress of Oral Implantologists (ICOI). Dr. Ganz is Co-Director of Advanced Implant Education (AIE), offering live, hands-on surgery training programs several times each year. He maintains a private practice for prosthodontics, maxillofacial prosthetics, and implant dentistry in Fort Lee, New Jersey.



Barry P. Levin, DMD

Barry P. Levin, D.M.D. is a Diplomate of The American Board of Periodontology. A graduate of Temple University School of Dental Medicine, he earned his certificate in Periodontics from the University of Maryland. Dr. Levin has been on staff at the University of Pennsylvania-Periodontal and Dental Implant Surgery Department since 1996. Dr. Levin publishes and lectures both nationally and internationally on topics pertaining to dental implantology and periodontics and has been involved in research pertaining to new and advanced dental implant designs and bone regenerative materials.