How the Concept of Complete Dentistry® Changes a Dental Practice

A DAWSON ACADEMY STUDENT CASE STUDY

Becoming a Dawson trained dentist will change the way a dentist practices. The following case illustrates these changes.

Case Summary

The patient, a middle-aged male, had regular dental care throughout his lifetime. At his initial appointment he complained of sensitivity associated with exposed dentin where cervical lesions existed (Figure 1). A previous dentist had filled the lesions (Figure 2), but the treatment failed and the patient was told that he brushed his teeth too hard.

Patient Summary

Patient: Ken, middle-aged, white male.

Chief Concerns: Patient complained of sensitivity associated with cervical lesions where dentin was exposed.

Dental History: Patient had regular dental examinations and treatments throughout his life time. The cervical lesions had been filled by a previous dentist, but the fillings failed. Patient was instructed to use a softer tooth brush and less pressure when brushing his teeth.

LEONARD HESS, DDS obtained his dental degree in 1999 from Northwestern University Dental School in Chicago and immediately purchased a small practice in Monroe, NC – a suburb of Charlotte – where he continues to practice today. Although he had significant debt from student loans and the purchase of the practice, Dr. Hess quickly realized that he needed to invest in continuing education. Lenny began his studies with the Dawson Academy in 2005, and in 2009 was asked to serve as a teaching assistant. He quickly distinguished himself as an excellent instructor with a true teacher's heart and was elevated to senior faculty in 2012. He has taught hundreds of hours of hands-on classes throughout the country and internationally.

Figure 1 (Top). Frontal retracted teeth apart view. This is one of the diagnostic photos in the Dawson Photographic Series. Figure 2 (Bottom). Cervical lesions with exposed dentin. Lesions had been filled by a previous dentist, but the treatment failed.

THE DAWSON ACADEMY
Making Good Dentists Even Better

800.952.2178 ▲ 390 4th Street North, Suite 200 ▲ St. Petersburg, FL 33701-2802
Phone: 727.823.7047 ▲ Fax: 727.821.0482 ▲ Email: Info@THEDAWSONACADEMY.COM

© 2017 The Dawson Academy. All rights reserved. This material may not be reproduced, displayed, modified or distributed without the express prior written permission of the copyright holder. For permission, contact info@thedawsonacademy.com.

Complete Examination: The patient's evaluation included an occlusal examination, muscle examination, temporomandibular joint evaluation using doppler auscultation, centric relation load testing, and range of motion measurements.

The results of the examination indicated occlusal instability and the following diagnostic records were taken: diagnostic casts, CR bite registration and a facebow transfer (Figures 3, 4, 5). An occlusal analysis was performed.

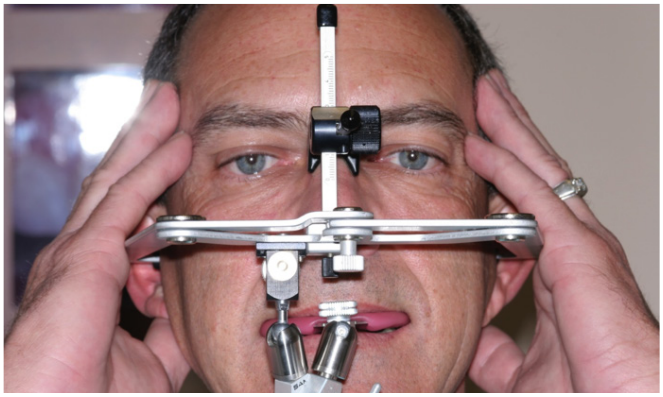

Figure 3. A facebow transfer recording is taken to mount the diagnostic casts on a semi adjustable articulator.

Diagnosis: The occlusal analysis revealed a CR to MI discrepancy causing a hit and slide (Figures 6, 7a, 7b), occlusal instability, muscular instability and bi-lateral displacement of the TMJ lateral poles.

Figure 6. The marks showing the hit and slide from CR to MI.

Figure 4. The centric relation bite registration will also be used to mount the models insuring the case is mounted in centric relation.

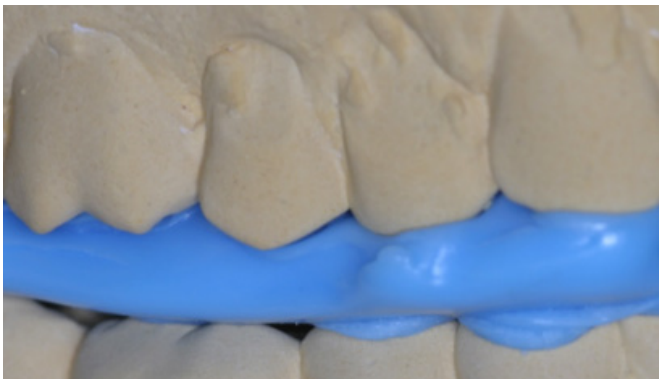

Figure 5. The centric relation bite is checked on the mounted casts to insure tooth – wax – tooth, just as in the mouth the goal is tooth – wax – tooth. The goal is for there to be no rock in the mounting.

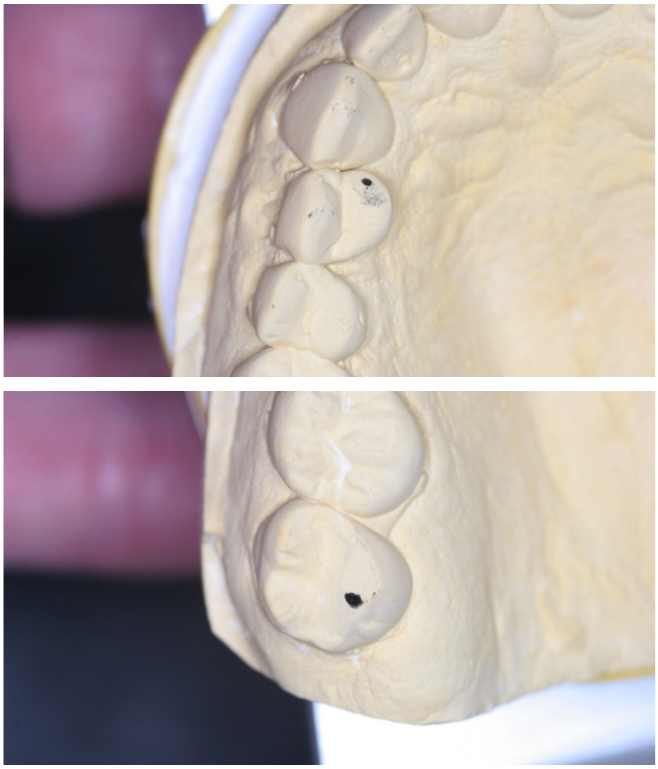

Figures 7 a and 7b. A marking ribbon indicates the first point of contact when the bite is in centric relation – indicating the source of the CR/MI discrepancy.

800.952.2178 ▲ 390 4th Street North, Suite 200 ▲ St. Petersburg, FL 33701-2802
Phone: 727.823.7047 ▲ Fax: 727.821.0482 ▲ Email: Info@THEDAWSONACADEMY.COM

© 2017 The Dawson Academy. All rights reserved. This material may not be reproduced, displayed, modified or distributed without the express prior written permission of the copyright holder. For permission, contact info@thedawsonacademy.com.

Treatment Plan

It was determined that the patient's problem could be solved with an occlusal equilibration, reshaping of the anterior teeth, one unit of crown and bridge, and resin treatment of the exposed dentinal areas (Figures 8a, 8b).

Treatment was a success, not only upon delivery, but now, 9 years later.

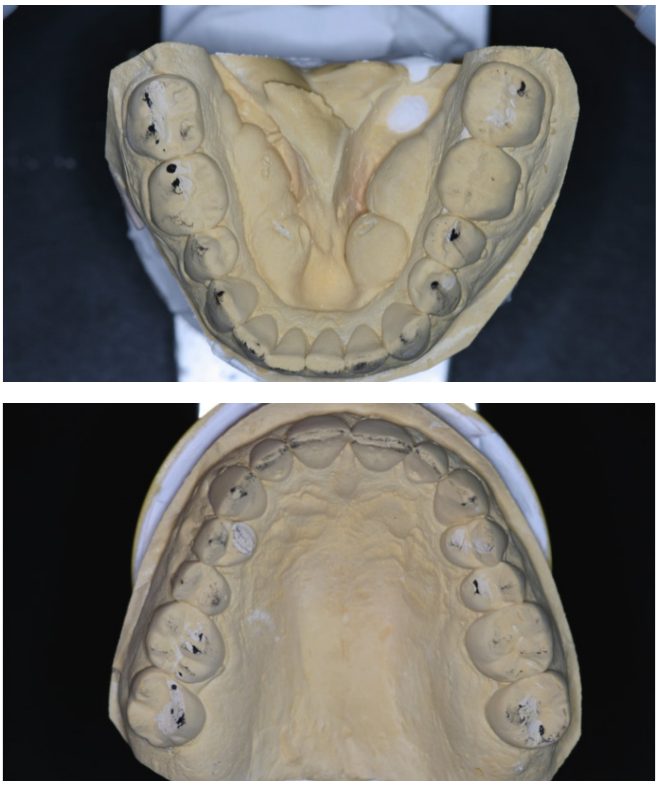

Figure 8a and 8b. Model trial equilibration indicates that an occlusal equilibration can successfully achieve a stable bite.

Figure 9. Cervical lesions are filled with resin restorations.

Figures 10 a, 10b and 10c. The cervical lesions shown before (top), after treatment (middle), and 9 years later (bottom).

The Dawson Academy provided me with the confidence to properly treat my patients. This confidence occurs by diagnosing correctly, and educating patients so that they can choose care that is best for them. More times than not, they will choose to do what is best once they have been given the freedom to choose.

800.952.2178 ▲ 390 4th Street North, Suite 200 ▲ St. Petersburg, FL 33701-2802
Phone: 727.823.7047 ▲ Fax: 727.821.0482 ▲ Email: Info@THEDAWSONACADEMY.COM

© 2017 The Dawson Academy. All rights reserved. This material may not be reproduced, displayed, modified or distributed without the express prior written permission of the copyright holder. For permission, contact info@thedawsonacademy.com.

Practice Impact

Prior to becoming a Dawson-trained dentist, I would have followed this treatment:

Complete Examination	$ 70.00
3 Facial resins ($210 each)	$ 630.00
Total production	**$ 700.00**

This would have resulted in failed treatment, just as the patient experienced with the previous dentist, and my frustration.

Because I am a Dawson-trained dentist, the following treatment occurred:

Complete Examination	$ 287.00
Splint Therapy	$ 450.00
Equilibration	$ 1,020.00
2 Facial resins	$ 420.00
Unit of crown & bridge	$ 1,020,00
Total production	**$ 3,197.00**

The Dawson difference is not just about production, though. The end-result is good dentistry that will last. The patient is happy and the dentist is too.

Live Courses.

In The Dawson Academy live courses, you will develop the knowledge and skills to confidently and accurately tackle any case - simple to complex, allowing you to increase your patients' satisfaction and your overall enjoyment of practicing dentistry.

Study Clubs.

Dawson Study Clubs are the ultimate local learning experience. Not only will you experience camaraderie learning from the provided Dawson Academy content during meetings, you also have untlimited access to all online resources.

Online Courses.

Learn from the comfort of your home (or office) with our online courses, videos and webinars. Dawson All Access gives you unlimited access to 40+ hours of CE courses, the Dawson Diagnostic Wizard® treatment planning software, and more!

THE DAWSON ACADEMY
Making Good Dentists Even Better

800.952.2178 ▲ 390 4th Street North, Suite 200 ▲ St. Petersburg, FL 33701-2802
Phone: 727.823.7047 ▲ Fax: 727.821.0482 ▲ Email: Info@THEDAWSONACADEMY.COM

© 2017 The Dawson Academy. All rights reserved. This material may not be reproduced, displayed, modified or distributed without the express prior written permission of the copyright holder. For permission, contact info@thedawsonacademy.com.